

Spinal Epidural Abscess Post Spinal Anesthesia: An Uncommon Complication of a Common Procedure

Abstract

Spinal epidural abscess (SEA) is a severe pyogenic infection of the epidural space. Bacteria gain access to the epidural space either by hematogenous spread, contiguous spread from a neighboring infected structure, or through iatrogenic inoculation. The diagnosis of SEA is a challenge, largely because of its rarity. We present here a case of SEA of iatrogenic origin (post spinal anesthesia), which we treated at Tata Main Hospital, Jamshedpur.

Keywords: *Hematogenous, iatrogenic, pyogenic, spinal epidural abscess*

Introduction

Spinal epidural abscess (SEA) is an extremely uncommon but devastating complication post spinal anesthesia. The initial symptoms are usually nonspecific, and the classic triad of back pain, fever, and neurological deficits is only seen late during the course of the disease which makes it a challenge to make an early diagnosis.^[1,2] The incidence of SEA has seen a rising trend over the past few decades. A study by Darouiche revealed the prevalence rate to be 0.18–1.96/10,000 hospital admissions.^[3] A recent study reported the incidence as 5.1/10,000 admissions.^[4] Grewal *et al.* suggested the incidence to be 1 in 2000 obstetric epidurals.^[5] Several risk factors have been identified which contribute to the etiopathogenesis of SEA, the most common of which is diabetes.^[6] We present here an uncommon case of SEA post spinal anesthesia in the absence of any known risk factors.

Case Report

A 20-year-old female presented to the emergency department with a history of bilateral lower limb weakness and acute urinary retention for the past 1 day. She also had severe lower back pain for the past 1½ months that radiated to both her lower limbs and was aggravated with an increase in physical activity. The severity

of the pain progressively increased over time. Her medical history revealed that she underwent a cesarean section under spinal anesthesia 1½ months back and all her symptoms started 3–4 days after the surgery including fever which subsided after 2 weeks following medication by a local doctor. She was nondiabetic and had no abdominal symptoms.

On physical examination, there were icterus, pallor, and tachycardia (110/min) with otherwise stable vital parameters. Abdominal examination showed mild hepatomegaly, and gynecological examination was normal. There was gross sensory diminution of all modalities below the xiphoid. The tone was increased in both lower limbs with obvious bilateral lower limb weakness (Grade 2/5 power around the hip and 3/5 around the knee and ankle). Knee and ankle jerks were exaggerated with bilaterally upgoing plantar. She had tenderness in her whole thoracic and lumbar region with negative signs of meningeal irritation. Routine blood investigation was indicative of acute infection (total leukocyte count: 27000, 90% neutrophils, the presence of toxic granules, total serum bilirubin: 7.5, and C-reactive protein: 13). An urgent contrast-enhanced magnetic resonance imaging (MRI) was done which showed a large SEA extending from T2 to S1 with multiple septations and cord compression [Figure 1].

**Jeevesh Mallik,
Vanita Motiani¹,
Manish Ganesh Pai²**

Department of Neurosurgery, Tata Main Hospital, Jamshedpur, Jharkhand, India, ¹Department of Internal Medicine, Ziauddin Medical University, Karachi, Pakistan, ²Department of Neurosurgery, Denver Children's Hospital, Anschutz Medical Campus, University of Colorado, Aurora, Colorado, USA

Address for correspondence:

*Dr. Jeevesh Mallik,
Specialist Block 11, Tata
Main Hospital, Bistupur,
Jamshedpur - 831 001,
Jharkhand, India.
E-mail: drjmallik@gmail.com*

Access this article online

Website: www.asianjns.org

DOI: 10.4103/ajns.AJNS_154_20

Quick Response Code:



This is an open access journal, and articles are distributed under the terms of the Creative Commons Attribution-NonCommercial-ShareAlike 4.0 License, which allows others to remix, tweak, and build upon the work non-commercially, as long as appropriate credit is given and the new creations are licensed under the identical terms.

For reprints contact: WKHLRPMedknow_reprints@wolterskluwer.com

How to cite this article: Mallik J, Motiani V, Pai MG. Spinal epidural abscess post spinal anesthesia: An uncommon complication of a common procedure. *Asian J Neurosurg* 2020;15:730-2.

Submitted: 11-Apr-2020

Revised: 19-Apr-2020

Accepted: 03-Jul-2020

Published: 28-Aug-2020

A diagnosis of SEA post spinal anesthesia was made. The patient was taken up for emergency surgery, and an L3 laminectomy with drainage of pus was done. Infant feeding tubes were passed cranially and caudally to breach the septations [Figure 2]. Broad-spectrum antibiotics (ceftriaxone + amikacin) were started which was changed as per pus culture and sensitivity report (meropenem + linezolid). The causative organism was identified as *Staphylococcus aureus*. She showed good postoperative recovery and was discharged on day 10. Follow-up at 2 weeks and later after 3 months showed that she was ambulant without support and had recovered fully. She had no hepatomegaly and her blood picture was completely normal. Follow-up MRI showed complete resolution of abscess with lax spinal cord and nerve roots [Figure 3].

Discussion

SEA is an uncommon condition where there is a pyogenic infection of the epidural space. It was rarely seen after epidural catheter placement in obstetric cases. A study conducted in 2002 did not report even a single case of epidural abscess among 5000 cases over a 5-year time period in obstetric patients receiving epidural catheterization.^[7] However, recent literature suggests a rising trend. Kindlar *et al.* reported the incidence as 1/2000 obstetric cases.^[8] SEA poses a unique diagnostic challenge as symptoms are nonspecific to begin with. Back pain is one of the most common early symptoms reported in 90% of cases,^[9] but being a common complaint postdelivery is frequently overlooked.^[10] The classical triad of pain, fever, and neurological deficit is often seen late after disease progression. This was observed in our patient too who had back pain soon after the delivery but was finally diagnosed more than a month later when she developed neurological deficits.

Several predisposing risk factors have been identified for SEA which include diabetes mellitus, immunocompromised state, malignant disease, or older age. SEA post spinal anesthesia in a young patient without any predisposing risk factors is extremely rare and makes our case unique. The spread of infection to the epidural space is more commonly through hematogenous spread from another focus of infection or through contiguous spread from the adjacent vertebra or muscle. Iatrogenic causes include spinal surgery, lumbar puncture, or epidural catheterization.^[3] In our patient, symptoms started few days after she had spinal anesthesia which leads us to the conclusion of it being the etiology.

MRI with contrast is considered the investigation of choice attributed to its 100% sensitivity in diagnosing SEA.^[11] Imaging findings may be supported by clinical and laboratory data. Blood markers of inflammation may be elevated, but none of them are specific for SEA.^[3] Our patient presented features of sepsis evidenced by her constitutional septic features and cholestasis leading to hepatomegaly and high bilirubin.^[14]

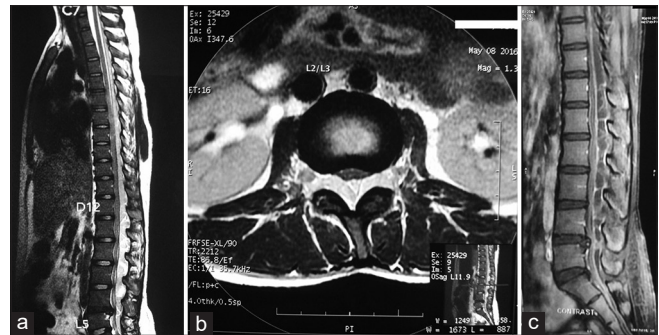


Figure 1: (a) Preoperative magnetic resonance imaging, T2-weighted sagittal. (b) T2-weighted axial. (c) Postcontrast

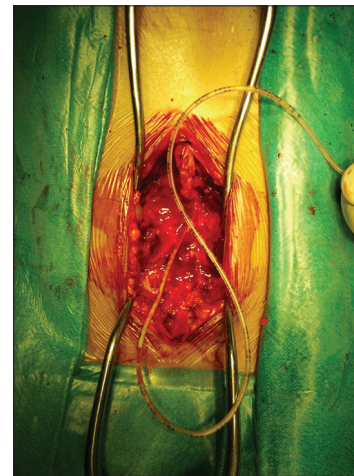


Figure 2: Infant feeding tube used to breach septations

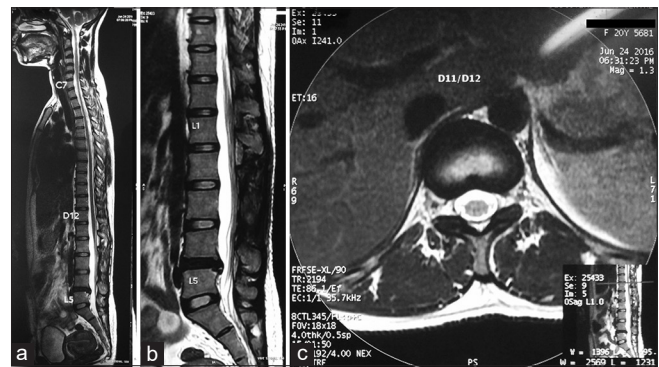


Figure 3: (a) Postoperative magnetic resonance imaging, T2-weighted whole spine. (b) T2-weighted LS spine. (c) T2-weighted axial

Surgical decompression and evacuation of pus is the treatment of choice in most cases. Patients without neurological deficits may be conservatively managed, but those patients need meticulous observation and might need emergency surgery later.^[12] Our patient presented with neurological deficits and hence was offered immediate surgery. A prompt diagnosis and early surgical intervention is the key for a good recovery.

Postoperatively, broad-spectrum antibiotics are empirically started and modified as per the pus culture/sensitivity report. In our case, we started with ceftriaxone + amikacin

later modified to meropenem + linezolid. There is no consensus on the duration of intravenous (IV) antibiotics.^[5] In our case, IV antibiotics were continued for 4 weeks (IV meropenem for 2 weeks and IV linezolid for 4 weeks), followed by oral antibiotics (linezolid) for another 2 weeks.

The most common organism causing SEA is *S. aureus* that has been isolated from cultures in two-thirds of all cases^[3] and was isolated as the causative organism in our case too. Other causative organisms reported are *Staphylococcus epidermidis*, *Escherichia coli*, *Pseudomonas aeruginosa*, and anaerobes.^[11]

With the common use of spinal anesthesia for cesarean sections and with the increasing use of epidural analgesia for painless labor, the rising trend of SEA post spinal anesthesia does not come as a surprise. This also suggests to put more emphasis on aseptic precautions in conducting these procedures, especially in developing countries. Despite the existence of differences in interpretation of aseptic precautions, standard aseptic precautions include the use of sterilized gowns, gloves, facemasks, and an appropriately placed sterile drape as well as a thorough skin treatment and handwashing after the removal of any jewelry.^[13] Their widespread implementation is extremely important in preventing such cases.

Declaration of patient consent

The authors certify that they have obtained all appropriate patient consent forms. In the form the patient(s) has/have given his/her/their consent for his/her/their images and other clinical information to be reported in the journal. The patients understand that their names and initials will not be published and due efforts will be made to conceal their identity, but anonymity cannot bechrological order guaranteed.

Financial support and sponsorship

Nil.

Conflicts of interest

There are no conflicts of interest.

References

1. Strohecker J, Grobovschek M. Spinal epidural abscess: An interdisciplinary emergency. Zentralbl Neurochir 1986;47:120-4.
2. Rosc-Bereza K, Arkuszewski M, Ciach-Wysocka E, Boczarska-Jedynak M. Spinal epidural abscess: Common symptoms of an emergency condition. Neuroradiol J 2013;26:464-8.
3. Darouiche RO. Spinal epidural abscess. N Engl J Med 2006;355:2012-20.
4. Vakili M, Crum-Cianflone NF. Spinal epidural abscess: A series of 101 cases. Am J Med 2017;130:1458-63.
5. Grewal S, Hocking G, Wildsmith JA. Epidural abscesses. Br J Anaesth 2006;96:292-302.
6. Reihnsaus E, Waldbaur H, Seeling W. Spinal epidural abscess: A meta-analysis of 915 patients. Neurosurg Rev 2000;23:175-204.
7. Phillips JM, Stedford JC, Hartsilver E, Roberts C. Epidural abscess complicating insertion of epidural catheters. Br J Anaesth 2002;89:778-82.
8. Kindler CH, Seeberger MD, Staender SE. Epidural abscess complicating epidural anesthesia and analgesia. An analysis of the literature. Acta Anaesthesiol Scand 1998;42:614-20.
9. Tang HJ, Lin HJ, Liu YC, Li CM. Spinal epidural abscess-experience with 46 patients and evaluation of prognostic factors. J Infect 2002;45:76-81.
10. Howell CJ, Dean T, Lucking L, Dziedzic K, Jones PW, Johanson RB. Randomised study of long term outcome after epidural versus non-epidural analgesia during labour. BMJ 2002;325:357-61.
11. Rigamonti D, Liem L, Sampath P, Knoller N, Namaguchi Y, Schreiber DL, et al. Spinal epidural abscess: Contemporary trends in etiology, evaluation, and management. Surg Neurol 1999;52:189-96.
12. Curry WT Jr., Hoh BL, Amin-Hanjani S, Eskandar EN. Spinal epidural abscess: Clinical presentation, management, and outcome. Surg Neurol 2005;63:364-71.
13. Association of Anaesthetists of Great Britain and Ireland. Infection control in anaesthesia. Anaesthesia 2008;63:1027-36.
14. Nesseler N, Launey Y, Aninat C, Morel F, Mallédant Y, Seguin P. Clinical review: The liver in sepsis. Crit Care 2012;16:235.