

Endoscopic Transsphenoidal Approach in Treatment of Germinomas of the Chiasmoseillar Region

Abstract

Introduction: Germinogenic central nervous system (CNS) tumors represent a heterogeneous group of tumors, constituting approximately 0.4% of all primary brain tumors. Removal of the tumor has no prognostic value. In “pure” primary germinomas of the CNS, the alpha-fetoprotein and human chorionic gonadotropin levels are within normal limits, and no specific biochemical tumor markers currently exist for this tumor type, making histological verification crucial for the choice of treatment tactics. When the tumor is located in the chiasmoseillar region, one of the possible verification methods is endoscopic endonasal transsphenoidal biopsy. **Objective:** the main objective of the study is to demonstrate the feasibility and safety of endoscopic transsphenoidal approach for histological verification of primary germinomas of the CNS with chiasmoseillar localization. **Materials and Methods:** The current study includes 13 patients with “pure” germinomas of the chiasmoseillar region who underwent endoscopic endonasal surgical interventions with subsequent treatment according to the “Germinoma 2008” protocol. **Results:** The extent of surgical intervention ranged from biopsy (4) to partial (5) and total (4) removal of the tumor. In all cases, histological verification of the diagnosis was achieved and none of the patients presented with cerebrospinal fluid leaks and/or meningitis in the postoperative period, allowing to evaluate endoscopic intervention in our patient series as safe and effective. Two out of 13 patients were lost to follow-up. **Conclusion:** The endoscopic endonasal approach for histological verification and removal of chiasmoseillar region germinomas is safe, and in some cases, less traumatic for the patient than transcranial and transventricular approaches.

Keywords: Chiasm-sellar region, endoscopic transanal approach, germinomas

Introduction

Germinogenic central nervous system (CNS) tumors represent a heterogeneous group of tumors, constituting approximately 0.4% of all primary brain tumors. The incidence of these tumors is 0.1/100,000 population per year.^[1] Most of these tumors are considered malignant.^[2]

A special place in this group of tumors is occupied by germinomas, constituting approximately 50%–65% of all CNS germ cell tumors. Other germ cell tumors include embryonic cancer, yolk sac tumors, chorionic carcinomas, teratomas (mature and immature), tumors with malignant transformation, and mixed germinogenic tumors.^[2] The male-to-female ratio of patients with germinomas is 2:1.^[1] The peak of germinoma incidence occurs at the age of 10–12 years. Ninety percent of cases of germ cell tumors are diagnosed

before the age of 20 years.^[3] There is no consensus about the origin of these tumors; however, it is assumed that these tumors develop either from germ cells that failed to migrate from the embryonic yolk sac into the gonads, or from pluripotent embryonic cells, the migration of which was also impaired.^[4-6] Germinomas arise mainly along the midline: in the suprasellar, infundibular spaces (30%) and in the pineal region (50%). In the event of simultaneous tumor occurrence in both areas, the patient is diagnosed with bi- or multi-focal germinoma. Bifocal germinomas are detected in 10%–20% of intracranial germ cell tumor cases.^[7-11] It is still unclear whether this is a true synchronous disease or is the result of metastatic process.^[12] Other possible areas of tumor occurrence are the third ventricle, basal ganglia, thalamus, lateral, and fourth ventricles. In some cases, several areas are affected, and the primary focus is difficult to determine.

How to cite this article: Kutin MA, Fomichev DV, Shkarubo AN, Chernov IV, Sharipov OI, Andreev DN, *et al.* Endoscopic transsphenoidal approach in treatment of germinomas of the chiasmoseillar region. *Asian J Neurosurg* 2019;14:1190-5.

Maxim Alexandrovich
Kutin, Dmitry
Vladislavovich
Fomichev, Alexey
Nikolaevich
Shkarubo, Iliia
Valerievich Chernov,
Oleg Ildarovich
Sharipov, Dmitry
Nikolaevich
Andreev, Denilbek
Beksultanovich
Ismailov, Nikita
Ilgorevich Mikhailov,
Grigoriy Lvovich
Kobyakov, Yuriy
Yurievich Trunin¹,
Ludmila Igorevna
Astafyeva,
Abdishukur
Abdilatifovich
Abdilatifov,
Artem Andreevich
Poddubsky, Pavel
Lvovich Kalinin

Departments of Neurooncology and ¹Radiology, N. N. Burdenko National Scientific and Practical Center for Neurosurgery, Moscow, Russia

Address for correspondence:
Dr. Iliia Valerievich Chernov,
Department of Neurooncology,
N. N. Burdenko National
Scientific and Practical Center
for Neurosurgery, Moscow,
Russia.

E-mail: ichernov@nsi.ru, ilch@list.ru

Access this article online

Website: www.asianjns.org

DOI: 10.4103/ajns.AJNS_156_19

Quick Response Code:



This is an open access journal, and articles are distributed under the terms of the Creative Commons Attribution-NonCommercial-ShareAlike 4.0 License, which allows others to remix, tweak, and build upon the work non-commercially, as long as appropriate credit is given and the new creations are licensed under the identical terms.

For reprints contact: reprints@medknow.com

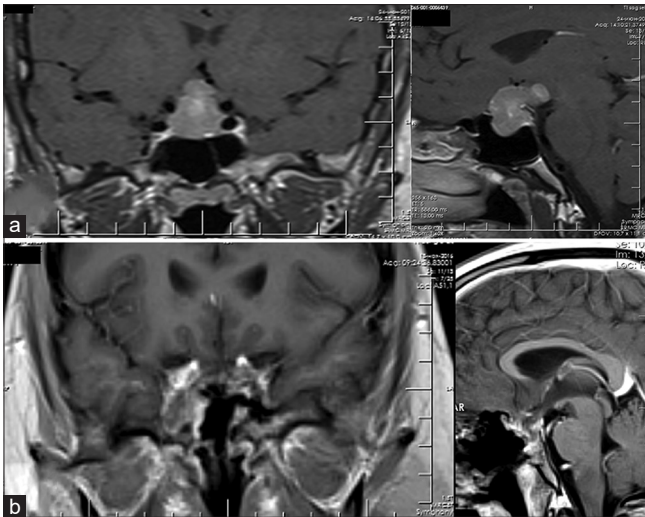


Figure 1: A 22-year-old male patient. Clinical manifestations: chiasmal syndrome, diabetes insipidus, and decreased libido. (a) Magnetic resonance imaging before surgery. Pituitary adenoma was suspected. (b) Magnetic resonance imaging 4 months after surgery (after two courses of primary chemotherapy). Vision impairment was noted in the early postoperative period. At 4 months follow-up, no tumor recurrence was observed. The patient presented with panhypopituitarism. Four courses of primary chemotherapy were conducted in total (started 2 months after surgery)

For histological verification, open, stereotactic, and endoscopic biopsies are used. However, small tumor fragments obtained during a biopsy may not always be indicative of the true diagnosis due to the possible presence of different tumor cells within the limits of one pathological focus.^[13-16]

The use of stereotactic biopsy (STB) for diagnostics of suprasellar germinomas, intimately adjacent to the visual pathways and the lower part of the hypothalamus, can cause damage to these critical structures, and therefore, until recently, transcranial approaches were used in these situations.^[17] In addition to morphological analysis, evaluation of the levels of alpha-fetoprotein (AFP) and beta-human chorionic gonadotropin (β -hCG) in serum and cerebrospinal fluid (CSF) is carried out.^[18,19]

The development of endoscopic endonasal approach techniques made primary total removal of tumors of the sellar and parasellar localizations possible using solely the endonasal transsphenoidal approach.^[20,21]

We present a series of patients with germinomas of suprasellar localization, who underwent surgical treatment (ranging from biopsy to total removal) of the tumors using only the endoscopic endonasal approach. Our task is to demonstrate the safety and effectiveness of endoscopic endonasal approaches for the surgical stage of the complex treatment of germinomas of the chiasmoseillar region.

Materials and Methods

From 2010 to 2017, 213 patients with primary germ cell tumors underwent surgical treatment at our institute, of which 153 patients had germinomas of the pineal

or chiasmoseillar region. Forty-six patients underwent surgery due to germinomas of the chiasmoseillar region. In 13 cases, endoscopic endonasal access was used.

The criteria for inclusion in the current analysis were as follows: endoscopic endonasal surgical interventions with histologically confirmed germinomas. The study included 13 patients (9 men and 4 women). The ratio of men to women was 2.25:1, which corresponds with literature data. The average age of patients was 21.1 years (6–38 years).

In 12/13 patients, chiasmal syndrome manifested in the form of reduced visual acuity and narrowing of the visual fields. Diabetes insipidus, as well as other hypopituitary disorders (hypocorticism, hypothyroidism, hypogonadism, etc.), were observed in all patients.

In all patients, blood test demonstrated titers of AFP and β -hCG which did not exceed the norm.

Based on the clinical and radiological data, hormone levels, and negative AFP and β -hCG markers, germinomas were suspected in three patients; these patients were planned to undergo transsphenoidal tumor biopsy. In the remaining ten cases, the main goal of treatment was to remove the tumor as completely as possible (in six cases, a pituitary adenoma was initially assumed, in 3 – a craniopharyngioma, and 1 – a chiasmal glioma).

After verification of the diagnosis, all patients were treated according to the “Herminoma 2008” protocol, including cisplatin etoposide polychemotherapy (up to four courses), followed by radiotherapy in doses dependent on the response of the tumor to palliative chemotherapy (PCT) (most often, the ventricular system was irradiated with total radiation dose (TRD) of up to 24 Gy).

Results

The radicality of surgical intervention ranged from biopsy (4) to partial (5) and total (4) removal of the tumor. In two cases, the tumor was represented by a very dense, moderately bleeding, stringy tissue focus; in 11 cases, the tumor was represented by soft, moderately bleeding tissue.

In three cases, in which germinomas were suspected at the preoperative stage, the extent of surgical intervention, as planned, was limited to a biopsy. In one case, the intraoperative findings allowed the surgeon to suspect a germinoma, and based on urgent histological analysis data, it was elected to limit the intervention with a biopsy. In the nine remaining cases, the texture of the tumor, its bleeding activity, and location made it possible to continue the removal of the tumor, while an urgent histological analysis was performed. As a result, at the time of completion of the urgent histological analysis (within 15–20 min), the tumor was removed totally in four cases and partially in five cases. After confirmation of suspected diagnosis, no further resection attempts were carried out.

In ten cases, standard endoscopic transsphenoidal approach was used. In three cases, an extended anterior transsphenoidal approach was used. Intraoperative CSF leaks were observed only in cases where the extended anterior transsphenoidal approach was used. In all cases, regardless of the presence or absence of intraoperative CSF leaks, the most reliable reconstruction of the skull base defect is required, as a further reduction in the size of the tumor (at the time of radiation and chemotherapy) will lead to an increased likelihood of nasal CSF leakage. In our series of patients, there were no cases of CSF leakage in the early or long-term postoperative period.

After the final histological analysis, all patients were recommended to undergo chemotherapy 1.5–2 months after surgery, followed by radiation therapy.

In the early postoperative period, in eight cases (three biopsies, three partial removals, and two total removals), no changes in the clinical symptoms were observed.

In the remaining five cases, the following clinical changes were noted: in one case (biopsy), regression of oculomotor disorders and diabetes insipidus symptoms was observed and in one case (partial removal), the patient noted improved vision. In one case (partial removal), improved vision was also noted, but diabetes insipidus symptoms became more pronounced. In one patient (total removal), visual acuity deteriorated after surgery from OU = 1.0 to OD = 0.6, OS = 0.8, and of visual field defects also increased [Figure 1]. In one patient (total removal), increased diabetes insipidus symptoms were noted [Figure 2].

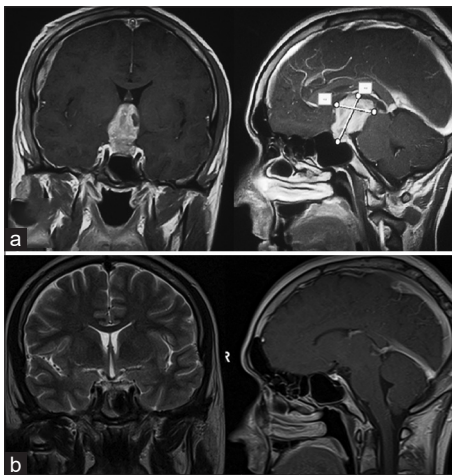


Figure 2: A 23-year-old male patient. Clinical manifestations: chiasmal syndrome, occlusive hydrocephalus (ventriculoperitoneal shunting was performed), diabetes insipidus, panhypopituitarism, and decreased libido. (a) Magnetic resonance imaging before surgery. Craniopharyngioma was suspected preoperatively. (b) Magnetic resonance imaging 2.5 years after surgery (after four courses of primary chemotherapy and radiation therapy). No tumor recurrence is observed. In the early postoperative period, increased symptoms of hypopituitarism and diabetes insipidus were observed. At the final follow-up (41 months), no recurrence of the tumor, complete regression of chiasmal syndrome, and libido recovery were observed. Diabetes insipidus, secondary hypocorticism, secondary hypothyroidism, and Growth hormone (GH) deficiency remained

The results of the combined treatment of the patients are presented in Table 1.

Two out of 13 patients were lost to follow-up with 11 patients remaining for long-term observation (three of them underwent total tumor removal, three – partial removal, and two – a biopsy).

The follow-up period ranged from 2 to 76 months. Median follow-up was 9 months.

Eight patients underwent four courses of chemotherapy, one patient underwent three courses of chemotherapy, and one patient underwent two courses of chemotherapy (platinum-combined chemotherapy was conducted). Four patients out of eight that underwent four courses of PCT also underwent radiotherapy (TRD of 24 Gy to the ventricular system). One patient of six who underwent PCT also underwent craniospinal radiation (TRD of 34 Gy) and boost to the chiasmal and pineal regions (TRD of 45 Gy). The patient had a bifocal germinoma. Two patients who completed four courses of PCT underwent local radiation of 2 Gy with a boost to the chiasmal area of 54 Gy (radiation therapy is planned for the remaining patients). There were no complications of radiation and/or chemotherapy in our series of patients. None of the patients (of those observed in the long term) had a relapse/continued tumor growth.

In five patients (one total removal, two biopsies, and two partial removals), visual impairment symptoms regressed at the final follow-up examination. Two of them also showed positive dynamics in endocrinological status: one (total removal) noted recovery of libido and the other (biopsy) noted regression of panhypopituitarism symptoms with residual secondary hypothyroidism.

In one patient (partial removal), a negative trend in the form of increased endocrine disorders was observed in the long-term postoperative period.

None of the operated patients had CSF leaks and meningitis in the long-term postoperative period, which makes it possible to confirm that endoscopic intervention in this category of patients is not only effective but also safe.

Discussion

Intracranial germinomas are rare tumors affecting predominantly patients under 20 years of age, accounting for 0.4% of all CNS tumors.^[1,12] Germinomas represent approximately two-third of intracranial germ cell tumors, the remaining third comprised of mixed malignant germ cell tumors and teratomas.^[3] The most frequent germinoma localizations are the pineal region (50%) and chiasmosellar (30%), suprasellar space. In addition, germinomas can be located in the cerebellar vermis, optic nerve chiasm, septum pellucidum, and other median structures.^[22-24]

Throughout the course of this study, a relationship between sex and the primary localization of the tumors

Table 1: Treatment results

Sex	Age	Preoperative clinical picture	Approach	Removal radicality	Early postoperative period	PCT	Radiotherapy	Follow-up period	Postoperative clinical picture
		VI* DJ* Panhypopituitarism			VI* DJ* Panhypopituitarism				VI* DJ* Panhypopituitarism
Male	22	+ + -	Extended anterior	Total removal	↓ N/C	4 PCT courses	Planned	4 months no relapse	N/C N/C N/C
Male	32	+ + -	Standard	Biopsy	N/C N/C	4 PCT courses	Planned	4 months no relapse	N/C N/C N/C
Male	38	+ + -	Extended anterior	Total removal	N/C N/C	4 PCT courses	TRD 24 Gy on target	25 months no relapse	N/C N/C N/C
Male	23	+ + +	Extended anterior	Total removal	N/C ↓	4 PCT courses	TRD 24 Gy to ventricle system	41 months no relapse	↑ N/C N/C
Female	6	+ + +	Standard	Biopsy	N/C N/C	4 PCT courses	TRD 24 Gy to ventricle system	36 months no relapse	↑ N/C N/C
Female	12	+ + +	Standard	Partial removal	↑ N/C	-	-	N/C	N/C N/C N/C
Male	16	- + +	Standard	Total removal	N/C N/C	4 PCT courses	TRD 60 Gy to head	47 months no relapse	N/C N/C N/C
Male	32	+ + +	Standard	Partial removal	N/C N/C	4 PCT courses	CR 34 Gy, boost to chiasmatal and pineal region up to 45 Gy	9 months no relapse	N/C N/C N/C
Female	22	+ + -	Standard	Partial removal	N/C N/C	3 PCT courses	Planned	3 months no relapse	↑ N/C ↓
Male	17	+ + +	Standard	Partial removal	N/C N/C	4 PCT courses	54 Gy	76 months no relapse	N/C N/C N/C
Male	13	+ + +	Standard	Biopsy	N/C N/C	1 PCT course	-	N/C	N/C N/C N/C
Male	21	+ + +	Standard	Biopsy	↑ ↑	4 PCT courses	TRD 24 Gy to ventricle system	3 months no relapse	↑ N/C ↑
Female	23	+ + +	Standard	Partial removal	↑ ↓	2 PCT courses	Planned	2 months no relapse	↑ N/C N/C

VI – Vision impairment; DJ – Diabetes insipidus; N/C – No change; PCT – Palliative chemotherapy; TRD – Total radiation dose; CR – Craniospinal radiation, +: Positive, -: Negative, ↑: Improvement, ↓: Deterioration

was identified. According to this pattern, in 75% of female patients, the primary germinoma localization is the suprasellar region, while in 67% of male patients, the tumor is localized in the pineal region.^[3,25]

In 10%–30% of patients with germ cell tumors of the CNS meningeal or CSF metastatic spread takes place; therefore, before starting treatment, it is advisable to examine the spinal cord to determine the most appropriate treatment tactics.^[26,27]

The location of the tumor largely determines the symptoms of the disease. The germinomas of the pineal region can cause obstruction of the ventricular aqueduct and the third ventricle, thereby leading to the development of hydrocephalic symptoms in the form of nausea, vomiting, cephalgia, and optic nerve edema.^[16] Compression of the tectal region and the quadrigeminal plate leads to the development of Parinaud's syndrome.^[28,29] Most patients with primary tumors of the suprasellar region have a long history of polyuria and polydipsia associated with diabetes insipidus, accompanied by other endocrine disorders, such as retarded growth, hypoparathyroidism, premature puberty, and hypothyroidism.^[3]

Thus, in any patient with acquired diabetes insipidus, suprasellar region germinoma should be suspected. Other common symptoms of the disease are fatigue, changes in sleep patterns, and learning difficulties.^[30,31] As it expands in the dorsal direction, a tumor of the suprasellar localization can compress the chiasm of the optic nerves, leading to deterioration of visual acuity and narrowing of visual fields. Often, patients disregard these symptoms until the development of pronounced symptoms of obstructive hydrocephalus or symptoms associated with tumor metastasis.^[3]

According to various authors, a combination of radiation and chemotherapy increases the 10-year survival rate of patients with germinomas up to 90%.^[17,30,31] Modern literature demonstrates that the 5-year survival rate varies between 85% and 95%; however, there have been several reports of recurrence of the disease 10 or more years after the initial diagnosis.^[32-37]

Often, all that is required from surgical intervention is the acquisition of a sufficient amount of material for morphological analysis.^[38]

However, thanks to the development of endoscopic technology and the improvement of the technical aspects of transsphenoidal interventions, an attractive option has emerged for the removal of germinomas of suprasellar localization.

According to Martens *et al.*, removal of a germinoma compared with a biopsy not only lacks any advantages in terms of overall survival and neurological outcome but also significantly reduces the quality of life of the patients.^[15]

On the other hand, according to Souweidane *et al.*, the continuously decreasing frequency of surgical complications and the possibility of reducing the adverse effects of radiation therapy (with total or subtotal removal of the tumor), may cause a reconsideration of the approach to radical germinoma removal.^[38] Abdallah *et al.* (2018) also noted that partial and subtotal removal of germinomas drastically reduces the risk of recurrence and dissemination of tumor cells in the subdural space.^[39] At the same time, currently, the postoperative treatment tactics do not depend on the extent of tumor removal, as radiation and chemotherapy must be carried out regardless of the surgical treatment results.

In our series of patients, four patients who underwent only a biopsy of the tumor did not experience visual or endocrine deterioration in the early postoperative period. In one of nine patients who underwent total or subtotal removal of the tumor, an increase in visual impairment was noted; two of these nine patients also experienced increased diabetes insipidus symptoms after surgery. Episodes of nasal CSF leaks or meningitis were not observed in any of the cases in the postoperative period.

Conclusion

Based on the results of the study, we can conclude that the endoscopic endonasal approach makes it possible to safely and effectively perform a biopsy of a germinoma when it is localized in the chiasmosellar region.

Subtotal and total removal of the germinoma of the chiasmosellar region is also feasible, as the rate of postoperative complications is very low. However, our study did not reveal any advantages of total germinoma removal compared with a biopsy. In our opinion, it is advisable to carry out radical germinoma removal only in cases of rapidly increasing symptoms of visual impairment or occlusive hydrocephalus.

In general, the question of the utility of an expanded resection of the germinoma remains controversial, and it is possible that with an increased follow-up period, additional data will be obtained that will help to evaluate the advantages and disadvantages of aggressive cytoreduction in cases of germinomas of the chiasmosellar region.

Financial support and sponsorship

Nil.

Conflicts of interest

There are no conflicts of interest.

References

- Ostrom QT, Gittleman H, Xu J, Kromer C, Wolinsky Y, Kruchko C, *et al.* CBTRUS statistical report: Primary brain and other central nervous system tumors diagnosed in the United States in 2009-2013. *Neuro Oncol* 2016;18:v1-75.
- Louis DN, Perry A, Reifenberger G, von Deimling A, Figarella-Branger D, Cavenee WK, *et al.* The 2016 World Health

- Organization classification of tumors of the central nervous system: A summary. *Acta Neuropathol* 2016;131:803-20.
3. Osorio DS, Allen JC. Management of CNS germinoma. *CNS Oncol* 2015;4:273-9.
 4. Echevarría ME, Fangusaro J, Goldman S. Pediatric central nervous system germ cell tumors: A review. *Oncologist* 2008;13:690-9.
 5. Sano K. Pathogenesis of intracranial germ cell tumors reconsidered. *J Neurosurg* 1999;90:258-64.
 6. Teilum G. Classification of endodermal sinus tumour (mesoblastoma vitellinum) and so-called "embryonal carcinoma" of the ovary. *Acta Pathol Microbiol Scand* 1965;64:407-29.
 7. Aizer AA, Sethi RV, Hedley-Whyte ET, Ebb D, Tarbell NJ, Yock TI, *et al.* Bifocal intracranial tumors of nongerminomatous germ cell etiology: Diagnostic and therapeutic implications. *Neuro Oncol* 2013;15:955-60.
 8. Cuccia V, Alderete D. Suprasellar/pineal bifocal germ cell tumors. *Childs Nerv Syst* 2010;26:1043-9.
 9. Hoffman HJ, Otsubo H, Hendrick EB, Humphreys RP, Drake JM, Becker LE, *et al.* Intracranial germ-cell tumors in children. *J Neurosurg* 1991;74:545-51.
 10. Huang PI, Chen YW, Wong TT, Lee YY, Chang KP, Guo WY, *et al.* Extended focal radiotherapy of 30 Gy alone for intracranial synchronous bifocal germinoma: A single institute experience. *Childs Nerv Syst* 2008;24:1315-21.
 11. Matsutani M, Sano K, Takakura K, Fujimaki T, Nakamura O, Funata N, *et al.* Primary intracranial germ cell tumors: A clinical analysis of 153 histologically verified cases. *J Neurosurg* 1997;86:446-55.
 12. Sumida M, Uozumi T, Kiya K, Mukada K, Arita K, Kurisu K, *et al.* MRI of intracranial germ cell tumours. *Neuroradiology* 1995;37:32-7.
 13. Franzini A, Leocata F, Servello D, Cajola L, Allegranza A, Broggi G, *et al.* Long-term follow-up of germinoma after stereotactic biopsy and brain radiotherapy: A cell kinetics study. *J Neurol* 1998;245:593-7.
 14. Konovalov AN, Pitskhelauri DI. Principles of treatment of the pineal region tumors. *Surg Neurol* 2003;59:250-68.
 15. Martens T, Rotermund R, Zu Eulenburg C, Westphal M, Flitsch J. Long-term follow-up and quality of life in patients with intracranial germinoma. *Neurosurg Rev* 2014;37:445-50.
 16. Smith AA, Weng E, Handler M, Foreman NK. Intracranial germ cell tumors: A single institution experience and review of the literature. *J Neurooncol* 2004;68:153-9.
 17. Shirato H, Nishio M, Sawamura Y, Myohjin M, Kitahara T, Nishioka T, *et al.* Analysis of long-term treatment of intracranial germinoma. *Int J Radiat Oncol Biol Phys* 1997;37:511-5.
 18. Kim A, Ji L, Balmaceda C, Diez B, Kellie SJ, Dunkel IJ, *et al.* The prognostic value of tumor markers in newly diagnosed patients with primary central nervous system germ cell tumors. *Pediatr Blood Cancer* 2008;51:768-73.
 19. Knappe UJ, Bentele K, Horstmann M, Herrmann HD. Treatment and long-term outcome of pineal nongerminomatous germ cell tumors. *Pediatr Neurosurg* 1998;28:241-5.
 20. Cavallo LM, Messina A, Cappabianca P, Esposito F, de Divitiis E, Gardner P, *et al.* Endoscopic endonasal surgery of the midline skull base: Anatomical study and clinical considerations. *Neurosurg Focus* 2005;19:E2.
 21. Kassam A, Thomas AJ, Snyderman C, Carrau R, Gardner P, Mintz A, *et al.* Fully endoscopic expanded endonasal approach treating skull base lesions in pediatric patients. *J Neurosurg* 2007;106:75-86.
 22. Nakase H, Ohnishi H, Touho H, Karasawa J, Tsunoda S. Cerebellar primary germ-cell tumor in a young boy. *Brain Dev* 1994;16:396-8.
 23. Park DeWitt J, Kim YH, Han JH, Lee SH, Kim IH, Choe G, *et al.* Primary intracranial germ cell tumor originating from septum pellucidum that mimics central neurocytoma. *J Clin Oncol* 2012;30:e274-7.
 24. Wilson JT, Wald SL, Aitken PA, Mastromateo J, Vieco PT. Primary diffuse chiasmatic germinomas: Differentiation from optic chiasm gliomas. *Pediatr Neurosurg* 1995;23:1-5.
 25. Jennings MT, Gelman R, Hochberg F. Intracranial germ-cell tumors: Natural history and pathogenesis. *J Neurosurg* 1985;63:155-67.
 26. Amendola BE, McClatchey K, Amendola MA. Pineal region tumors: Analysis of treatment results. *Int J Radiat Oncol Biol Phys* 1984;10:991-7.
 27. Haddock MG, Schild SE, Scheithauer BW, Schomberg PJ. Radiation therapy for histologically confirmed primary central nervous system germinoma. *Int J Radiat Oncol Biol Phys* 1997;38:915-23.
 28. Linggood RM, Chapman PH. Pineal tumors. *J Neurooncol* 1992;12:85-91.
 29. Paulino AC, Wen BC, Mohideen MN. Controversies in the management of intracranial germinomas. *Oncology (Williston Park)* 1999;13:513-21.
 30. Huh SJ, Shin KH, Kim IH, Ahn YC, Ha SW, Park CI, *et al.* Radiotherapy of intracranial germinomas. *Radiother Oncol* 1996;38:19-23.
 31. Ogawa K, Shikama N, Toita T, Nakamura K, Uno T, Onishi H, *et al.* Long-term results of radiotherapy for intracranial germinoma: A multi-institutional retrospective review of 126 patients. *Int J Radiat Oncol Biol Phys* 2004;58:705-13.
 32. Calaminus G, Kortmann R, Worch J, Nicholson JC, Alapetite C, Garré ML, *et al.* SIOP CNS GCT 96: Final report of outcome of a prospective, multinational nonrandomized trial for children and adults with intracranial germinoma, comparing craniospinal irradiation alone with chemotherapy followed by focal primary site irradiation for patients with localized disease. *Neuro Oncol* 2013;15:788-96.
 33. Kahn L, Fridley J, Patel AJ, Gressot L, Kitagawa R, Goodman JC, *et al.* Disseminated germinoma in the brain and cervical spinal cord 10 years after radiographic resolution of pineal germinoma. *J Clin Neurosci* 2012;19:1055-7.
 34. Kamoshima Y, Sawamura Y, Ikeda J, Shirato H, Aoyama H. Late recurrence and salvage therapy of CNS germinomas. *J Neurooncol* 2008;90:205-11.
 35. Schoenfeld A, Haas-Kogan DA, Molinaro A, Banerjee A, Nicolaidis T, Tihan T, *et al.* Pure germinomas of the central nervous system: Treatment strategies and outcomes. *J Neurooncol* 2014;120:643-9.
 36. Shima H, Nishizaki T, Ishihara H, Moroi J, Fujii M, Suzuki M, *et al.* Recurrent intracranial germinoma with dissemination along the ventricular catheter: A case report. *J Clin Neurosci* 2002;9:708-10.
 37. Von Rohr E, Gönner F, Schroth G, Cerny T. Relapse and subarachnoid dissemination of a pineal germinoma 14 years after radiation therapy. *J Clin Neurosci* 1999;6:247-9.
 38. Souweidane MM, Krieger MD, Weiner HL, Finlay JL. Surgical management of primary central nervous system germ cell tumors: Proceedings from the second international symposium on central nervous system germ cell tumors. *J Neurosurg Pediatr* 2010;6:125-30.
 39. Abdallah A, Asilturk M, Uysal ML, Emel E, Abdallah BG, Bilgic B, *et al.* Primary intracranial germinomas: Retrospective analysis of five cases. *Turk Neurosurg* 2018;28:29-35.