

Surgical Management of Multi-Level Cervical Spine Synovial Chondromatosis

Abstract

Cervical synovial chondromatosis is a benign condition which most commonly affects the knee joint. The involvement of the spinal column is rare, with only a few reports in the literature describing surgical treatment for compressive spinal lesions. Given the rarity of this condition, the best treatment methodology is yet to be established. We describe the case of a 38-year-old female who presented with progressively worsening myeloradicular symptoms localizing to the cervical spinal cord. Imaging revealed a multilevel osseous and epidural lesion involving the subaxial cervical spine. A computed tomography-guided biopsy was performed to obtain a diagnosis to aid further treatment planning. Subsequently, surgical decompression and stabilization were performed after which the patient made an excellent recovery. She continues to do well at 2 years follow-up. Cervical synovial chondromatosis is a rare condition which can present with pain, radiculopathy, and/or myelopathy. Surgical treatment should focus on complete resection, decompression, and stabilization with arthrodesis and fusion to prevent recurrence. We propose that the lack of motion provided by stabilization and fusion after gross total resection prevents disease recurrence.

Keywords: Cervical chondromatosis, myelopathy, radiculopathy, spinal cord compression

Introduction

Synovial chondromatosis is a benign pathology involving metaplastic proliferation of chondrocytes within the synovium. The knee joint is most commonly affected. Involvement of the cervical spine is rare. Thus far, 12 patient reports have been described in the literature involving single level facet disease with either an epidural mass or an exophytic neck mass.^[1-11] In Gallia *et al.*'s report, one of the two cases had a two-level anterolateral component from a posteriorly arising facet lesion which was treated with gross total resection, decompression, and fusion.^[3] Given the rarity of this problem in the cervical spine, the best approach to surgical management of this pathology has not yet been established. The question remains whether near gross total resection itself is enough or arthrodesis and fusion is required in these cases to prevent recurrence. It is also not certain whether there are any histological variations that can predict future recurrence.

This is an open access journal, and articles are distributed under the terms of the Creative Commons Attribution-NonCommercial-ShareAlike 4.0 License, which allows others to remix, tweak, and build upon the work non-commercially, as long as appropriate credit is given and the new creations are licensed under the identical terms.

For reprints contact: WKHLRPMedknow_reprints@wolterskluwer.com

Case Report

Presentation and symptoms

A 38-year-old female presented with a 5-month history of worsening intermittent neck pain radiating into her shoulder blades, associated with bilateral hand numbness and paresthesias hands. One week prior, she started developing numbness and cramping in her thighs and calves, difficulty walking, and imbalance. Neurologic examination revealed hyperreflexia bilaterally without motor or sensory deficits.

Imaging

Computed tomography (CT) of the cervical spine revealed an osseous mass centered at the left C4–5 facet joint extending along the lamina and involving C4 through C6 spinous processes. Significant kyphotic deformity was noted. CT angiogram of the neck demonstrated encasement and occlusion of the left vertebral artery at C4 and C5. Magnetic resonance imaging revealed a nonenhancing mass with epidural extension at C4–5 causing displacement of the spinal cord and spinal canal narrowing [Figure 1].

How to cite this article: Mirza FA, Vasquez RA. Surgical management of multi-level cervical spine synovial chondromatosis. *Asian J Neurosurg* 2021;16:367-71.

Submitted: 13-Apr-2020

Revised: 06-Sep-2020

Accepted: 27-Oct-2020

Published: 28-May-2021

Farhan Arshad Mirza, Raul Alberto Vasquez

*Department of Neurosurgery,
University of Kentucky,
Lexington, KY, USA*

Address for correspondence:

*Dr. Farhan Arshad Mirza,
Department of Neurosurgery,
University of Kentucky,
Lexington, KY 40536, USA.
E-mail: fmi222@uky.edu*

Access this article online

Website: www.asianjns.org

DOI: 10.4103/ajns.AJNS_157_20

Quick Response Code:



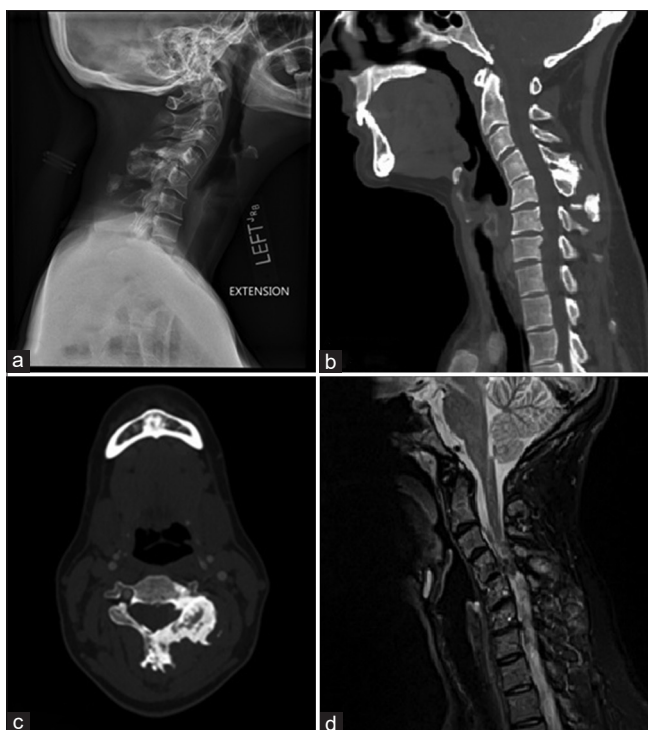

Figure 1: Preoperative imaging: (a) Lateral plain radiograph showing degenerative kyphotic changes as well as abnormal ossification of the posterior elements at C4–5 and C5–6. (b) Sagittal computed tomography scan showing the same findings. (c) Axial computed tomography scan showing large left side osteophytic growth involving the lateral mass and spinous process. (d) Sagittal contrast-enhanced magnetic resonance imaging showing cord compression and signal change

Surgical plan and intraoperative findings

The patient underwent a CT-guided biopsy of the mass at the C6 spinous process. Pathology was consistent with synovial chondromatosis. Given the patient's continued radicular and myelopathic symptoms, the decision was made to proceed with decompression and stabilization of the cervical spine.

A standard posterior midline approach was conducted. The severity of cervical deformity, instability, and the large bony tumor mass was immediately obvious. The tumor involved the spinous processes of C4, C5, and C6 with extension into the left C4 and C5 facet joints [Figure 2a]. After removal of the osseous tumor components, C3–6 laminectomy and left C4–5 facetectomy was completed. Using microsurgical techniques, the intraspinal tumor was removed. A complete resection was achieved with adequate decompression of the spinal cord, nerves, and the left vertebral artery [Figure 2b]. To correct the kyphotic deformity and instability, a C2–T1 posterolateral arthrodesis and fusion as well as a C4–5 anterior cervical discectomy, interbody arthrodesis, and fusion was performed in the same session.

Postoperative care

The patient was admitted to the intensive care unit overnight for blood pressure control and then transferred to

the floor on day one. The patient was discharged home on day four without any new neurological deficits. At 2 years follow-up, the patient reports minimal neck pain with no radiculopathy and significant improvement of myelopathic symptoms [Figure 3].

Pathology

Microscopic examination demonstrated a hypocellular chondroid lesion, with chondrocytes arranged predominantly in micronodules. The lesion demonstrated foci of enchondral ossification and attenuation of the host bone without definitive cortical permeation. There were rare microscopic foci present within the lesion that demonstrate ischemic-type necrosis. Given the unusual nature of this case, it sent for expert soft tissue and bone consultation, confirming the diagnosis of synovial chondromatosis. [Figure 4].

Discussion

First described in 1813, Synovial chondromatosis is an uncommon disorder which typically affects large joints, most commonly the knee.^[11] Cervical spine involvement is rare with only twelve cases reported thus far. Multilevel presentation is even more unusual, with only one of the twelve previously reported cases having a two-level anterolateral component [Table 1]. Usually, a single facet is involved, and it gives rise to an intraspinal epidural mass or exophytic neck mass, presenting with axial neck pain, radicular symptoms, or myelopathy. This was seen in our case where the mass was involving the left C4–5 facet joint extending anterolaterally to the C4–5 vertebral bodies. Even more uncommon was the presence of two different skip lesions on the spinous processes of C6 and C7.

Histologically, primary synovial chondromatosis reveals lobules of hypercellular hyaline cartilage admixed with atypical histological features: Multinucleation, nuclear crowding, nuclear enlargement, and hyperchromasia with mild myxoid changes. This is often accompanied by a variable degree of synovial proliferation. In our case, areas of necrosis were also seen which were deemed to be ischemic in nature rather than tumor necrosis, perhaps related to an accelerated growth. Differentiating primary synovial chondromatosis from low-grade chondrosarcoma can be a challenge due to these somewhat atypical findings, for which molecular markers or immunostains may be helpful in the future.

In series from orthopedic literature of extraspinal lesions, it has been noted that in secondary synovial chondromatosis, which is usually associated with osteoarthritis, rheumatoid disease, osteochondral plate fractures, the triggering factors were usually obvious, and the lesions were not aggressive. Conversely, primary synovial chondromatosis, was aggressive and associated with a high incidence of recurrence.^[12] Recurrence and degeneration of the tumor into synovial chondrosarcoma has been reported

Table 1: Reports of cervical synovial chondromatosis in literature. Single case with multi-level involvement is highlighted.

Study	Pt.	Levels involved	Presenting Sx	Hx of Trauma	Treatment		F/U	Recurrence
					Conservative	Surgical		
Kyriakos6 (2000)	39 yo F	C3-4 left facet and lamina	9 mo. Neck and left arm pain	None	PT, Heat, U/S, NSAIDs Muscle relaxants Injections	Left C3 hemilaminectomy and partial facetectomy C3-4	Post-operative neck pain for 6 mos.	Unknown
Greenlee4 (2002)	48 yo M	C4-5 left anterior mass	1 y left arm and suprascapular pain	MVA 1 y prior	Unknown	Resection of left C4-5 mass via anterior approach	Unknown	Unknown
Chiba1 (2003)	52 yo F	C7-T1 right sided epidural mass, facet joint involvement	Right shoulder, arm, forearm pain with mild weakness	None	Prednisone	Right C7 hemilaminectomy, C7-T1 facetectomy, resection of epidural mass	Improvement of pain. Mild dysesthesia	Unknown
*Gallia3 (2004)	46 yo M	C1-2 left sided epidural mass with C1-3 anterior extension, facet joint involvement	4 y neck pain. CT guided bx. Continued pain and arm weakness			2 staged: -Left C1-2 hemilaminectomy, facetectomy, resection of epidural tumor, partial C2 VB resection, O-C5 fusion -Tracheostomy. left-sided transmandibular circumglossal approach, tumor debulking, partial C1 arch resection and odontoidectomy B/L C2-5 laminectomy, radical left C2-3, C3-4 facetectomy, partial C4-5 facetectomy, tumor resection, C-2 pedicle, C-3, C-4, and C-5 lateral mass screws. Transcondylar far lateral approach, C2 laminectomy, right C1-2 facetectomy, en bloc tumor resection tumor, C1 to C4 posterior instrumentation and fusion	1 y, complete resolution of neck pain	None
*Moody8 (2010)	44 yo M	C1-2, large right posterolateral exophytic mass	6 y painful neck mass, pain in right shoulder and bicep	MVA			44 mos. Symptomatic improvement	None
Han5 (2012)	21 yo M	C6-7, right facet epidural mass	17 mos right scapular pain, R hand numbness			First op: Right C6 hemilaminectomy, partial C6-7 facetectomy, subtotal tumor resection Second op: Redo facetectomy and complete tumor resection	Improvement in pain. 3 yrs later: Recurrence of pain 4 mos: pain free	Radiographic and clinical recurrence None

Contid...

Table 1: Contd...

Study	Pt.	Levels involved	Presenting Sx	Hx of		Treatment		F/U	Recurrence
				Trauma	Conservative	Surgical	Surgical		
Shaw9 (2014)	19 yo M	C3-4, left facet epidural mass	Left sided weakness/numbness from cord compression	MVA and Football	7 mos PT	Left C3 laminoplasty and tumor resection	Left C3 laminoplasty and tumor resection	12 mos: improvement in strength and numbness	None
Mehra7 (2015)	58 yo M	C5-6, right facet epidural foraminal mass	2 y right arm numbness			Right C5-6 partial facetectomy, tumor resection, posterior fusion (levels unspecified)	Right C5-6 partial facetectomy, tumor resection, posterior fusion (levels unspecified)	Unknown	Unknown
Wang10 (2015)	12 yo F	C4-5, large right exophytic mass involving facet and neural foramen	1 y right posterolateral neck enlarging mass with neck discomfort			2 staged: -Midline approach, open biopsy -Henry approach posterior to SCM and levator scapulae, en-bloc tumor resection	2 staged: -Midline approach, open biopsy -Henry approach posterior to SCM and levator scapulae, en-bloc tumor resection	9 mos: no instability or pain	None
Wood11 (2016)	42 yo F	C3-4, large right exophytic mass involving TP and facet	8 y painless posterior neck mass			Resection - details unspecified	Resection - details unspecified	1 mos	Unknown

*Reports with surgical treatment involving arthrodesis and fusion.. VB: vertebral body; O: occipital; PT: physical therapy; TP: transverse process

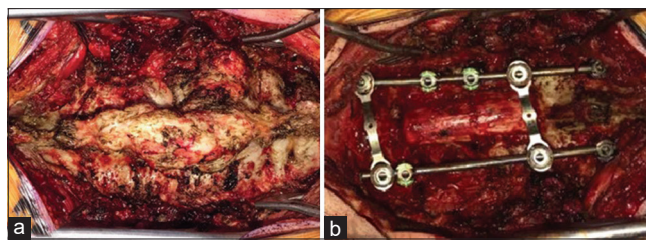


Figure 2: Intraoperative imaging: (a) Intraoperative findings on initial exposure (rostral is to the left and caudal to the right). (b) Completion of C3-6 laminectomy, left C4-5 facetectomy, C2-T1 posterolateral arthrodesis, and fusion

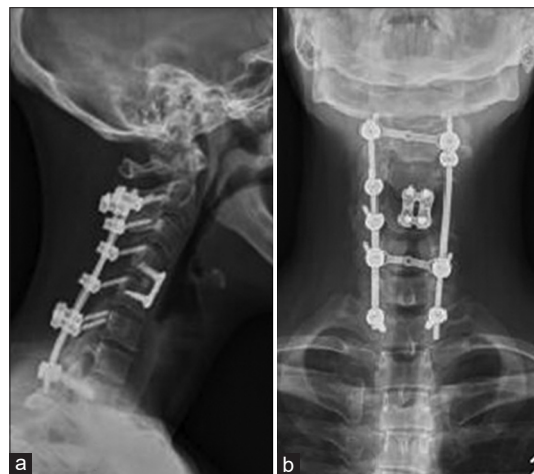

Figure 3: Follow-up imaging. (a) Lateral plain radiograph at 2 years follow up. (b) Anteroposterior plain radiograph

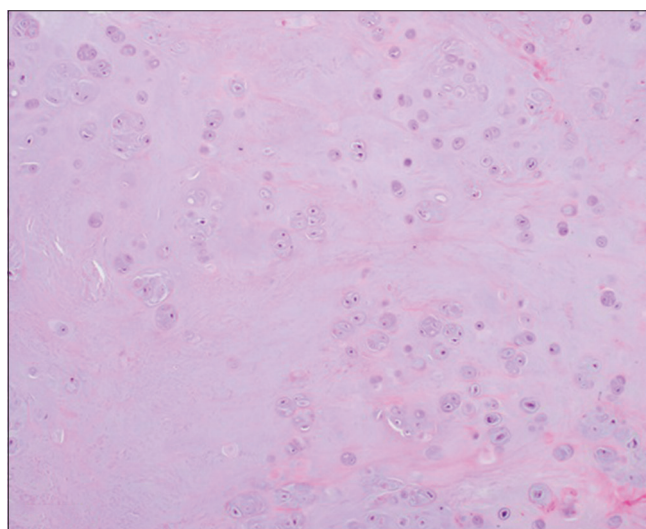


Figure 4: Pathology: Micrograph at x10 demonstrates a hypocellular and chondroid lesion, comprised predominantly chondrocytes arranged in small nodules. No atypia is seen

in extraspinal sites, with the rate being cited close to 6% and the median time to malignant transformation being two decades from initial diagnosis.^[13] Predicting recurrence in the cervical spine is a challenge given the rarity of cases. It can be presumed that since this tumor arises from metaplastic synovium, osteoarthritic changes

leading to motion segment instability may contribute to the progression of the tumor, akin to a synovial cyst. We propose that the lack of motion provided by stabilization and fusion after gross total resection prevents tumor recurrence.

Conclusion

Cervical synovial chondromatosis is a rare condition. Surgical treatment should focus on complete resection, decompression, and stabilization with arthrodesis and fusion to prevent recurrence. Image-guided biopsy is also recommended before surgery to aid in establishing pathological diagnosis and goals of the surgery.

Acknowledgments

Funding was not required for the completion of this project.

IRB approval is not required for case reports, as per institutional policy. The patient's consent was obtained for publication of this unique case. No patient identifiers are disclosed in this manuscript.

Declaration of patient consent

The authors certify that they have obtained all appropriate patient consent forms. In the form the patient(s) has/have given his/her/their consent for his/her/their images and other clinical information to be reported in the journal. The patients understand that their names and initials will not be published and due efforts will be made to conceal their identity, but anonymity cannot be guaranteed.

Financial support and sponsorship

Nil.

Conflicts of interest

There are no conflicts of interest.

References

1. Chiba S, Koge N, Oda M, Yamauchi R, Imai T, Matsumoto H, *et al.* Synovial chondromatosis presenting with cervical radiculopathy: A case report. *Spine (Phila Pa 1976)* 2003;28:E396-400.
2. Chee CG, Lee JW, Lee GY, Yeom JS, Choe G, Kang HS. Synovial osteochondromatosis of the cervical spine: A case report. *J Korean Soc Radiol* 2014;70:379-83.
3. Gallia GL, Weiss N, Campbell JN, McCarthy EF, Tufaro AP, Gokaslan ZL. Vertebral synovial chondromatosis. Report of two cases and review of the literature. *J Neurosurg Spine* 2004;1:211-8.
4. Greenlee JD, Ghodsi A, Baumbach GL, VanGilder JC. Synovial chondromatosis of the cervical spine. Case illustration. *J Neurosurg* 2002;97:150.
5. Han JS, Lee SH, Kim ES, Eoh W. Regrowing synovial chondromatosis in a cervical facet joint with radiculopathy. *Korean J Spine* 2012;9:253-6.
6. Kyriakos M, Totty WG, Riew KD. Synovial chondromatosis in a facet joint of a cervical vertebra. *Spine (Phila Pa 1976)* 2000;25:635-40.
7. Mehra RN, Grigorov M, Pieper D. Synovial chondromatosis presenting as an epidural mass. *Surg Neurol Int* 2015;6:S388-90.
8. Moody P, Bui MM, Vrionis F, Setzer M, Rojiani AM. Synovial chondromatosis of spine: Case report and review of the literature. *Ann Clin Lab Sci* 2010;40:71-4.
9. Shaw A, Zibly Z, Prasad V, Ikeda D, Boue D, Governale LS. Synovial chondromatosis of the cervical spine: A case report and review of the literature. *Pediatr Dev Pathol* 2014;17:221-5.
10. Wang WH, Grigoriou E, Dormans JP. Synovial chondromatosis of the spine in the skeletally immature: Case report and updated review of the literature. *J Pediatr Orthop B* 2015;24:255-61.
11. Wood ML, Lee TK, Armstrong WB, Wang BY. Cervical spine synovial chondromatosis: A case report and literature review. *Med Rep Case Stud* 2016;1:114.
12. Villacin AB, Brigham LN, Bullough PG. Primary and secondary synovial chondrometaplasia: Histopathologic and clinicoradiologic differences. *Hum Pathol* 1979;10:439-51.
13. Evans S, Boffano M, Chaudhry S, Jeys L, Grimer R. Synovial chondrosarcoma arising in synovial chondromatosis. *Sarcoma* 2014;2014:647939. doi: 10.1155/2014/647939. Epub 2014 Mar 5. PMID: 24737946; PMCID: PMC3967817.