

Do Asians have Higher Carotid Bifurcation? A Computed Tomographic Angiogram Study of the Common Carotid Artery Bifurcation and External Carotid Artery Branching Patterns

Abstract

Introduction: Carotid endarterectomy is a major treatment modality for high-grade carotid stenosis. Preoperative identification of the level of the carotid bifurcation and its branching pattern is important in planning for adequate exposure and cross-clamping to achieve hemostasis during the procedure. Most of the previous studies on carotid arteries were performed in cadavers. **Methods:** We studied levels of carotid bifurcation compared relatively with the level of the vertebral body and ipsilateral angle of the mandible and its branching pattern using computed tomographic angiogram (CTA) carotid with multiplanar reconstruction and three-dimensional imaging in 100 CTA studies. **Results:** Most of the carotid bifurcations were located at the level of C3–C4 vertebral body and 12% were considered to be high bifurcation. Carotid bifurcations were located below the angle of the mandible in 83.5%. The superior thyroid, facial, and lingual arteries arose from separate branches of external carotid arteries in 67.7% of samples. Facial arteries arose in common trunk with lingual arteries in 29.2%, much more common than previous cadaveric studies. The lingual arteries arose with superior thyroid arteries in 2%, while occipital arteries had high variations in their branching patterns. **Conclusions:** CTA is an effective and reliable modality for preoperative evaluation of the carotid system in patients undergoing carotid endarterectomy and other carotid procedures. Higher percentage of high carotid bifurcation was found in our study, concordant with other Asian cadaveric studies. We assumed that carotid bifurcation of Asian tends to be located slightly higher than those of the Caucasian population.

Keywords: Carotid anatomy, carotid bifurcation level, carotid endarterectomy, computed tomographic angiogram carotid study, extracranial carotid branching patterns

Introduction

The level of common carotid bifurcation and branching patterns of external carotid arteries have significant impacts on various surgical procedures of the head-and-neck region. In neurosurgery, the level of bifurcation impacts the decision-making in carotid endarterectomy and stenting procedures for carotid stenosis. The endarterectomy should be avoided in patients with very high carotid bifurcation, usually defined as being above the C3 vertebral body. From the surgical perspective, high-level carotid bifurcation requires more specialized techniques for adequate exposure and has more tendency to postoperative complications because of difficulties in the dissection of distal carotid artery and risk of injuries to adjacent structures, including hypoglossal nerve and

salivary gland.^[1-4] Variation of branching patterns of carotid arteries needed to be carefully evaluated preoperatively and during the carotid endarterectomy procedure because these branches needed to be cross-clamped to control bleeding.

Interestingly, even in the era of modern imaging techniques, most of the studies about the carotid bifurcation and the branching patterns were still performed in cadaveric specimens.^[5-16] We believe that computed tomographic angiogram (CTA) of carotid can provide excellent visualization of anatomical variations and can be applied in clinical practice comparable to or even better than cadaveric data. Some studies used CTA or magnetic resonance angiography (MRA) of carotid as a method to determine the level of the carotid bifurcation.^[17-19] However, each study defined different landmarks for

This is an open access journal, and articles are distributed under the terms of the Creative Commons Attribution-NonCommercial-ShareAlike 4.0 License, which allows others to remix, tweak, and build upon the work non-commercially, as long as appropriate credit is given and the new creations are licensed under the identical terms.

For reprints contact: reprints@medknow.com

How to cite this article: Jitpun E, Wattanasen Y, Tirakotai W. Do Asians have higher carotid bifurcation? A computed tomographic angiogram study of the common carotid artery bifurcation and external carotid artery branching patterns. Asian J Neurosurg 2019;14:1082-8.

**Ekkapot Jitpun,
Yodkhan
Wattanasen¹,
Wuttipong Tirakotai**

*Departments of Neurosurgery
and ¹Neuroradiology, Prasat
Neurological Institute, Bangkok,
Thailand*

Address for correspondence:
Dr. Ekkapot Jitpun,
Department of Neurosurgery,
Prasat Neurological Institute,
312, Ratchawithi Road, Thung
Phayathai, Ratchathewi,
Bangkok 10400, Thailand.
E-mail: ejitpun@gmail.com

Access this article online

Website: www.asianjns.org

DOI: 10.4103/ajns.AJNS_162_19

Quick Response Code:



determining the level of bifurcation, making the results from these studies incomparable. The aim of this study is to investigate the variations of common carotid artery bifurcation comparing with the level of the vertebral column and branching pattern of the external carotid artery using CTA with three-dimensional (3D) reconstruction.

Methods

We reviewed the consecutive 100 patients with carotid CTAs from the PACS database performed in Prasat Neurological Institute from January 2013 to May 2016.

Multisection CTAs were obtained with a 64-slice CT scanner (SOMATOM Definition AS, Siemens Medical Systems Inc., Erlangen, Germany). Contrast media was injected at a rate of 5 mL/s, with the use of a power injector (Mallinckrodt) and an 18G or 20G needle inserted in the antecubital vein. The volume of iodinated contrast media in each study was 100 ml. The CTA was automatically started with bolus trigger (Care-Bolus) by monitoring of vascular opacification. The scanning parameters included 120 kV, 129 mAs, 0.6-mm slice thickness, 0.6 s scan time, 0.33 s rotation time, 1.4 pitch, and 200 mm Field of View (FOV). Transverse spiral scan from vertex to the arch of the aorta was performed for the entire carotid artery system. Postprocessing subtraction image, volume rendering, and maximum intensity projection image were created on medical workstations (Syngo Via and Syngo InSpace).

Levels of carotid bifurcation were compared relatively with the level of the vertebral body and ipsilateral angle of the mandible in horizontal plane. Branching patterns of carotid arteries including superior thyroid, facial, lingual, and occipital arteries were examined from 3D imaging. Anterior branches were classified as A1, superior thyroid, facial, and lingual arteries arose from separate branches

of external carotid arteries; A2, facial arteries arose in common trunk with lingual arteries (linguofacial trunk) and A3, lingual arteries arose with superior thyroid arteries (thyrolingual trunk) [Figure 1]. Occipital arteries branching patterns were classified as O1, occipital arteries arose between superior thyroid arteries and lingual arteries; O2, occipital artery arose between lingual arteries and facial arteries and O3, the occipital arose above facial arteries [Figure 2].

The data were descriptively analyzed and reported into frequency, median, and percentage. The study was approved by the Prasat Neurological Institute Ethics Committee.

Results

Level of carotid bifurcation comparing with the vertebral column and angle of mandible

CTA of 200 carotid arteries from 100 patients were examined, 58% were men. The mean age was 60-year-old (age range 19–91, median 62).

Sixty-one percent of CTA was performed for diagnosis and illustrated carotid anatomy for patients with carotid stenosis. There is only one carotid artery that the level of bifurcation cannot be identified from CTA due to nearly occluded ICA bifurcation.

The carotid bifurcation was most commonly located at C3–C4 vertebral level, followed by mid C4, and mid C3, respectively [Table 1]. There was no significant difference between the two sides of carotid arteries.

Comparing level of angle of mandible in neutral supine position with vertebral body showed that the most common level of angle of mandible was at C2–C3 (51%), followed by mid C3 (28%), mid C2 (13%), C3–C4 (5%), and C4–C5 (3%), respectively. We found no angle of

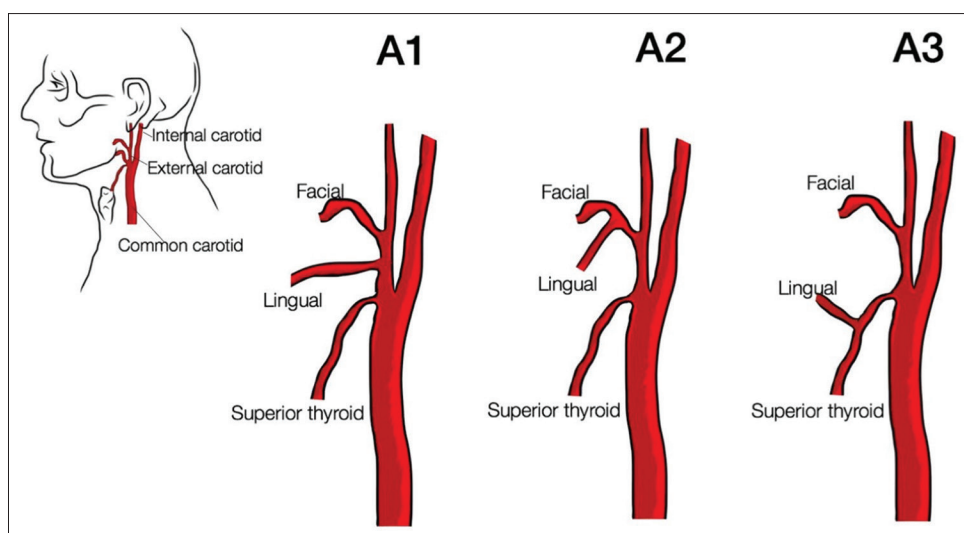


Figure 1: The artistic rendering illustrates the classification of the anterior branch of the external carotid artery into three common variations. A1: The superior thyroid, lingual, and facial arteries arose from separate branches of the external carotid artery; A2: The facial artery arose in common trunk with the lingual artery (linguofacial trunk); and A3: The lingual artery arose in common trunk with the superior thyroid artery (thyrolingual trunk)

the mandible that located below C4–C5 level in our study [Table 2].

Most of the carotid bifurcations (83.5% of the total, 86% of the right side, 81% of left side) were located below the angle of mandible, with a mean distance of 16.41 mm below the angle on the right side and 14.84 mm on the left side. Sixteen percent of carotid bifurcation was lying above or at the same level of the angle of the mandible [Table 3].

Table 1: The distribution of level of carotid bifurcations comparing with the level of the vertebral body

Level of carotid bifurcation	Right (n=100), n (%)	Left (n=100), n (%)	Total (n=200), n (%)
Mid C2	0	1 (1)	1 (0.5)
C2-3	10 (10)	13 (13)	23 (11.5)
Mid C3	20 (20)	18 (18)	38 (19)
C3-4	32 (32)	32 (32)	64 (32)
Mid C4	23 (23)	19 (19)	42 (21)
C4-5	12 (12)	15 (15)	27 (13.5)
Mid C5	0	1 (1)	1 (0.5)
C5-6	2 (2)	1 (1)	3 (1.5)
Unidentified	1 (1)	0	1 (0.5)

Table 2: The distribution of level of the angle of mandible comparing with the level of the vertebral body

	Angle of mandible (%)
Mid C2	13
C2-3	51 (51)
Mid C3	28 (28)
C3-4	5 (5)
Mid C4	0
C4-5	3 (3)
Mid C5	0
C5-6	0

Branching patterns of superior thyroid, lingual, facial, and occipital arteries

From 200 carotid arteries, CTA studies with 3D reconstruction, we excluded five samples of superior thyroid, facial, lingual arteries (anterior branches, classified as A1, A2, and A3) and 4 of occipital arteries due to poor visualization of branching patterns.

The superior thyroid, facial, and lingual arteries arose from separate branches of external carotid arteries in 67.7% of samples. Facial arteries arose in common trunk with lingual arteries in 29.2%, and the lingual arteries arose with superior thyroid arteries in 2% [Table 4 and Figures 1-5].

The occipital arteries arose between superior thyroid arteries and lingual arteries in 49.5%, between lingual arteries and facial arteries in 32.7% and above facial arteries in 15.8%. There were 2% of occipital arteries that arose in common trunk with superior thyroid, lingual, or facial arteries [Table 4 and Figures 1-5].

Discussion

Evaluation of carotid bifurcation level in patients with carotid stenosis, planning for endarterectomy, was usually performed by CTA, MRA, or even conventional angiography. Most recommendations suggest that carotid bifurcation above C3 vertebral level was considered high bifurcation. A study used distance from the mastoid process as a reference to identify the high bifurcation.^[18] Some studies used thyroid cartilage as anatomical landmark.^[5,7-9,15,16] The level of carotid bifurcation was considered as a high bifurcation when it was located above the thyroid cartilage.

In this study, the carotid bifurcations can be identified in 95.5% of the samples and the branching patterns of external carotid arteries can be clearly identified with CTA with multiplanar reconstruction (MPR) and 3D reconstruction

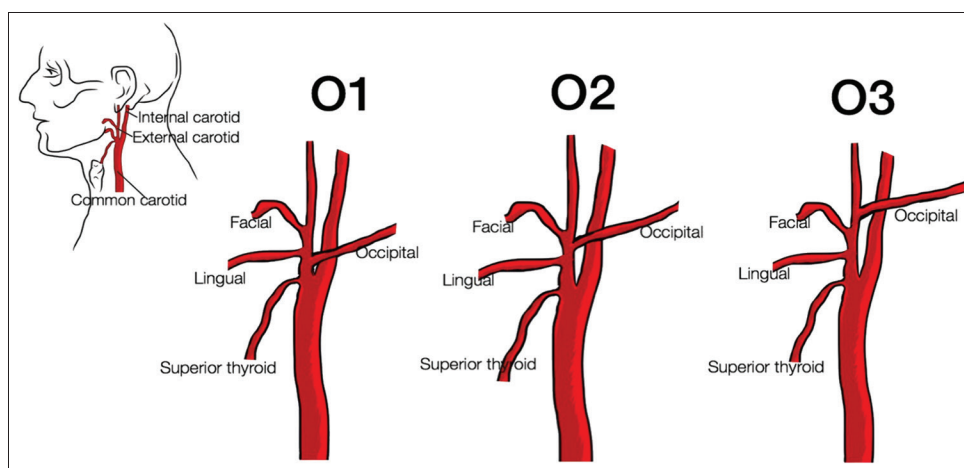


Figure 2: The artistic rendering illustrates the classification of the occipital artery into three common variations. O1: The occipital artery arose between superior thyroid artery and lingual artery; O2: The occipital artery arose between lingual artery and facial artery; and O3: The occipital artery arose above the level of the facial artery

Table 3: The relationship of level of carotid bifurcation comparing with the level of the angle of mandible

	Right		Left	
	<i>n</i> (%)	Mean distance (mm)	<i>n</i> (%)	Mean distance (mm)
Carotid bifurcation above angle of mandible	4 (4)	0.53	3 (3)	0.20
Carotid bifurcation at the level of the angle of mandible	9 (9)	-	16 (16)	-
Carotid bifurcation below angle of mandible	86 (86)	16.41	81 (81)	14.84

Table 4: Branching patterns of external carotid artery

	Right	Left	Total (%)
Anterior branches (<i>n</i> =195)			
A1	69	63	132 (67.7)
A2	25	32	57 (29.2)
A3	3	1	4 (2)
Other	1	1	2 (1)
Occipital (<i>n</i> =196)			
O1	50	47	97 (49.5)
O2	30	34	64 (32.7)
O3	16	15	31 (15.8)
Other	2	2	4 (2)

in 97.75% of the study sample, suggesting that CTA is an effective and reliable modality to evaluate the carotid artery anatomy in patients undergoing carotid endarterectomy.

We reviewed the studies describing the carotid bifurcation in the literature and anatomy textbooks [Table 5]. Using the vertebral body level as the anatomical landmark, most of the classic western anatomy textbooks described that carotid bifurcation was found most commonly located at C3–C4 vertebral level.^[20,22-26] Clemente reported that only 5% of his samples had high carotid bifurcation.^[20] An angiographic study in Turkey reported 2% of samples with high bifurcation.^[21] Interestingly, studies in Asian cadavers showed different results.^[6,11-14] Klosek and Rungruang studied the level of carotid bifurcation comparing with the level of the vertebral body in 43 Thai cadavers. They reported that most of the carotid bifurcation was at C3–C4 vertebral level. However, the carotid bifurcation could not be identified in 13.6% of the cadaver. The authors discussed that very high position of carotid bifurcation could explain the finding.^[12] Chaijaroonkhanarak *et al.*, also reported a study in 55 Thai cadavers. The right carotid bifurcation was the most common at C2 level and left bifurcation was the most common at C3 level, with 53.6% of their cadavers had high carotid bifurcation.^[13] Hayashi *et al.* reported 49 Japanese cadaveric dissection and found that most of the carotid bifurcation was at mid C3 vertebral body level with 20% considered to have high carotid bifurcation. The authors concluded that the carotid bifurcation of Japanese might be located higher than those of the European population.^[11] Another Japanese study reported a high bifurcation in 31.2% of their cadavers.^[14]

Our study found that most of the carotid bifurcation was located at the level of C3–C4 vertebral body, with 12% with high carotid bifurcation. We realized that with limited study

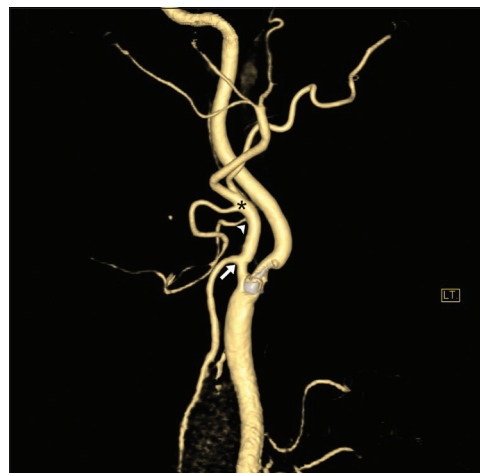


Figure 3: The left-sided three-dimensional computed tomographic angiogram of a 47-year-old male with carotid stenosis illustrates the branching pattern of the external carotid artery. The superior thyroid artery (arrow), lingual artery (arrowhead), and facial artery (asterisk) arise from separate branches of the external carotid artery; (A1). The occipital artery arises above the origin of the facial artery; (O3)

population, 200 carotid studies in 100 patients, cannot make a conclusion that the Asian population have more percentage of high carotid bifurcation than in the Caucasian population. However, our data are concordant with other previous carotid studies performed in the Asian population and should be a concern for a clinician who deals with this group of patients.

As Chaijaroonkhanarak *et al.*, reported that carotid bifurcation in their cadaveric dissection study most commonly located at C2 vertebral body,^[13] suggested that most of the carotid bifurcations of their cadaveric specimen were considered to be high carotid bifurcations. However, that may result from the technique of measurement and cadaveric preparation that may cause errors in the evaluation of the actual level of the carotid bifurcation.

From our surgical experience, the relationship between the angle of the mandible and carotid bifurcation also has an impact on surgical exposure. We observed that carotid bifurcation located at the level of or above the level of the angle of mandible usually had more exposure difficulties. Most of carotid bifurcations (86% on the right side and 81% on the left side) were located below the level of the angle of the mandible in the supine neck position, and 16% was located at the level of the angle of mandible or above the level of the angle of mandible. Further study has to be performed to identify the relationship between the angle of mandible with difficulties in surgical exposure.

The distribution of branching patterns of carotid arteries in this study is quite different from other studies [Table 6].^[5,7,10,11,15,27,28] The percentage of facial arteries that arose in common trunk with lingual arteries (linguofacial trunk) was more frequently found (29.2% vs. 0%–20%). The branching patterns of the occipital artery had the same distribution as the previous study.^[11]

Limitations

This is a retrospective, anatomical study with no comparative data. We assumed that patients underwent CTA was in the supine position, but in the real surgical procedures, these patients would be operated in extended position of the neck, thus studying the level of the angle of mandible from CTA might has limited benefit in surgical planning. As mentioned

in the previous study,^[29] the vertebral level of structures in the neck depends in part on the curvature of the cervical spine and choice of the reference plane. As our study measured all structures in horizontal plane, the level retrieved might be different from other studies using the axial plane.

We evaluate the carotid bifurcation level from CTA, which was an intraluminal study. The bifurcation level cannot be identified in those vessels with severe carotid stenosis or completely obliterated carotid arteries, and also in very small vessels that usually cannot be identified in normal imaging, for example, the ascending pharyngeal artery.

Conclusions

Carotid bifurcation level and carotid branching patterns should be preoperatively evaluated and should be

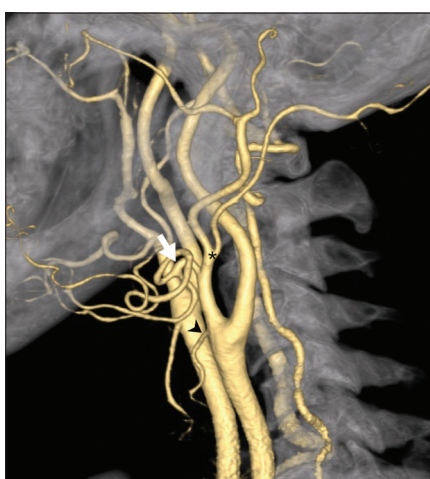


Figure 4: The left-sided three-dimensional computed tomographic angiogram of 53-year-old male with carotid stenosis illustrates the level of carotid bifurcation at C3–C4 intervertebral space level and branching pattern of the external carotid artery. The facial artery arises in common trunk (arrow) with the lingual artery; (A2). The occipital artery (asterisk) arises above the origin of facial artery (asterisk); (O3)

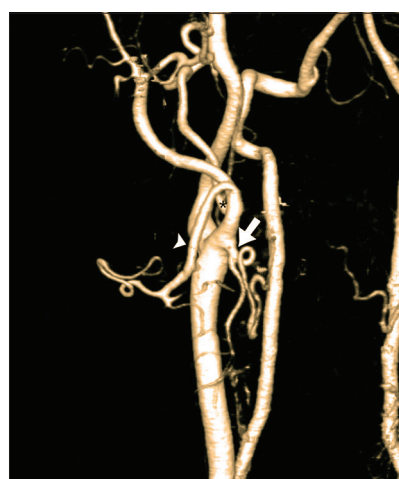

Figure 5: The right-sided three-dimensional computed tomographic angiogram of a 59-year-old male with carotid stenosis illustrates the branching pattern of the external carotid artery. The superior thyroid artery arises in common trunk (arrow) with lingual artery; (A3). The occipital artery (asterisk) arises between the origin of lingual (arrow) and facial artery (arrowhead); (O2)

Table 5: The distribution of the level of carotid bifurcation among reported studies

Level of carotid bifurcation	Above C2	Mid C2	C2-3	Mid C3	C3-4	Mid C4	C4-5	Mid C5	C5-6	Below C5-6
Clemente ^[20]	0	1	4	12	30	35	12	5	1	0
Chaijaroonkhanarak <i>et al.</i> , Thai, cadaver ^[13]	10	40	3.6	41.8	0.9	3.6	0	0	0	0
Hayashi <i>et al.</i> , Japanese, cadaver ^[11]	0	10.2	9.1	47.5	8	28.4	3.4	0	0	0
Ito <i>et al.</i> , Japanese, cadaver ^[14]		31.2			57.5				11.3	
Anu <i>et al.</i> , Indian, cadaver ^[6]	-	Right 10/left 9	-	Right 50/left 55	-	Right 40/left 35	-	-	-	-
Klosek and Rungruang, Thai*, cadaver ^[12]	0	0	2.3	10.5	20.9	30.2	16.3	5.8	0	0
Kurkcuoglu <i>et al.</i> , Turkey, conventional angiography ^[21]	0	1	1	6	12	23	24	25	4	4
Current study, Thai, CTA	0	0.5	11.5	19	32	21	13.5	0.5	1.5	0

*Unidentified carotid bifurcation in 13.6% of study population. CTA – Computed tomographic angiogram

Table 6: The distribution of external carotid artery branching patterns among reported studies

Branching patterns	Anterior branches				Occipital			
	A1	A2 (linguofacial)	A3 (thyrolingual)	Other	O1	O2	O3	Other
Hayashi <i>et al.</i> , Japanese ^[11]	81	18	1	0	57	32	11	0
Vazquez <i>et al.</i> , UK ^[27]	99	0	0.6	0.3	-	-	-	-
Sanjeev <i>et al.</i> , India ^[15]	78.38	18.92	2.7	0	-	-	-	-
Natsis <i>et al.</i> , Caucasian Greek ^[10]	80.2	17.4	2.5	0	-	-	-	-
Ongeti and Ogeng'o, Kenyan ^[28]	93.5	0	0	1	-	-	-	-
Dessie, Ethiopia ^[7]	92.4	2.3	2.3	0	-	-	-	-
Devadas <i>et al.</i> , India ^[5]	78.75	20	0	1.25	-	-	-	-
This study	67.7	29.2	2	1	49.5	32.7	15.8	2

meticulously identified intraoperatively before arteriotomy was performed to achieve well-controlled hemostasis during the procedure. Carotid bifurcations and the branching patterns of external carotid arteries can be clearly identified with CTA with MPR and 3D reconstruction, suggesting that CTA is an effective and reliable modality for preoperative evaluation of the carotid system in patients undergoing carotid endarterectomy and other carotid procedures. Furthermore, CTA can be used to identify the relationship of level of the angle of the mandible and the level of the carotid bifurcation, which can be benefit in preoperative planning.

Most of the carotid bifurcation located at level of C3–C4 vertebral body, concordant with previous carotid studies performed in the Asian population. Carotid bifurcations of Asian tend to be located slightly higher than those of Caucasian studies.

Declaration of patient consent

The authors certify that they have obtained all appropriate patient consent forms. In the form the patient(s) has/have given his/her/their consent for his/her/their images and other clinical information to be reported in the journal. The patients understand that their names and initials will not be published and due efforts will be made to conceal their identity, but anonymity cannot be guaranteed.

Financial Support and sponsorship

Nil.

Conflicts of interest

There are no conflicts of interest.

References

- Spetzler RF, Baskin JJ, Apostolides PJ. Rational and Protocol for Microsurgical Carotid Endarterectomy, Microsurgical Carotid Endarterectomy. Philadelphia, New York: Lippincott-Raven; 1996.
- Bademci G, Batay F, Tascioglu AO. Non-traumatic elevation techniques of the hypoglossal nerve during carotid endarterectomy: A cadaveric study. *Minim Invasive Neurosurg* 2005;48:108-12.
- Bademci G, Batay F, Vural E, Avci E, Al-Mefty O, Yaşargil MG, *et al.* Microsurgical anatomical landmarks associated with high bifurcation carotid artery surgery and related to hypoglossal nerve. *Cerebrovasc Dis* 2005;19:404-6.
- Kim T, Chung S, Lanzino G. Carotid artery-hypoglossal nerve relationships in the neck: An anatomical work. *Neurol Res* 2009;31:895-9.
- Devadas D, Pillay M, Sukumaran TT. A cadaveric study on variations in branching pattern of external carotid artery. *Anat Cell Biol* 2018;51:225-31.
- Anu VR, Pai MM, Rajalakshmi R, Latha VP, Rajanigandha V, D'Costa S, *et al.* Clinically-relevant variations of the carotid arterial system. *Singapore Med J* 2007;48:566-9.
- Dessie MA. Variations of the origin of superior thyroid artery and its relationship with the external branch of superior laryngeal nerve. *PLoS One* 2018;13:e197075.
- Lo A, Oehley M, Bartlett A, Adams D, Blyth P, Al-Ali S, *et al.* Anatomical variations of the common carotid artery bifurcation. *ANZ J Surg* 2006;76:970-2.
- Lucev N, Bobinac D, Maric I, Drescik I. Variations of the great arteries in the carotid triangle. *Otolaryngol Head Neck Surg* 2000;122:590-1.
- Natsis K, Raikos A, Foundos I, Noussios G, Lazaridis N, Njau SN, *et al.* Superior thyroid artery origin in Caucasian Greeks: A new classification proposal and review of the literature. *Clin Anat* 2011;24:699-705.
- Hayashi N, Hori E, Ohtani Y, Ohtani O, Kuwayama N, Endo S, *et al.* Surgical anatomy of the cervical carotid artery for carotid endarterectomy. *Neurol Med Chir (Tokyo)* 2005;45:25-9.
- Klosek SK, Rungruang T. Topography of carotid bifurcation: Considerations for neck examination. *Surg Radiol Anat* 2008;30:383-7.
- Chaijaroonkhanarak W, Prachaney P. The common carotid artery: Site of bifurcation at the vertebral level. *Srinagarind Med J* 2003;18:21-6.
- Ito H, Mataga I, Kageyama I, Kobayashi K. Clinical anatomy in the neck region the position of external and internal carotid arteries may be reversed. *Okajimas Folia Anat Jpn* 2006;82:157-67.
- Sanjeev IK, Anita H, Ashwini M, Mahesh U, Rairam GB. Branching pattern of external carotid artery in human. *J Clin Diagn Res* 2010;4:3128-33.
- Al-Rafiah A, EL-Haggagy AA, Aal IH, Zaki AI. Anatomical study of the carotid bifurcation and origin variations of the ascending pharyngeal and superior thyroid arteries. *Folia Morphol (Warsz)* 2011;70:47-55.
- Denli Yalvac ES, Balak N, Atalay B, Bademci MS, Kocaaslan C, Oztekin A, *et al.* A new method for determining the level of the carotid artery bifurcation. *J Craniofac Surg* 2019. doi: 10.1097/SCS.00000000000005449.
- McNamara JR, Fulton GJ, Manning BJ. Three-dimensional computed tomographic reconstruction of the carotid artery:

- Identifying high bifurcation. *Eur J Vasc Endovasc Surg* 2015;49:147-53.
19. Weaver K, Huang J, Tamargo RJ, Bernard EJ Jr. Preoperative localization of the carotid bifurcation for carotid endarterectomy using magnetic resonance angiography without tomography: Technical note. *Neurosurgery* 2004;55:1227.
 20. Clemente CD. *Anatomy, a Regional Atlas of the Human Body*. 37th ed. Edinburgh: Churchill Livingstone; 1997.
 21. Kurkuoglu A, Aytakin C, Oktem H, Pelin C. Morphological variation of carotid artery bifurcation level in digital angiography. *Folia Morphol (Warsz)* 2015;74:206-11.
 22. Standring S. *Gray's Anatomy: The Anatomical Basis of Clinical Practice*. Edinburgh: Churchill Livingstone; 2008.
 23. Sinnatamby C. *Last's Anatomy: Regional and Applied*. Edinburgh: Churchill Livingstone, Elsevier; 2011.
 24. Moore KL, Daly AF, Agur AM. *Clinically Oriented Anatomy*. Philadelphia, PA: Lippincott Williams and Wilkins; 2010.
 25. Drake RL, Vogl AW, Mitchell AW. *Gray's Anatomy of Student*. 2nd ed. Philadelphia, PA: Churchill Livingstone; 2010.
 26. Ellis H, Mahadevan V. *Clinical Anatomy: A Revision and Applied Anatomy for Clinical Students*. Oxford, UK: Blackwell Publishing; 2010.
 27. Vázquez T, Cobiella R, Maranillo E, Valderrama FJ, McHanwell S, Parkin I, *et al.* Anatomical variations of the superior thyroid and superior laryngeal arteries. *Head Neck* 2009;31:1078-85.
 28. Ongeti KW, Ogeng'o JA. Variant origin of the superior thyroid artery in a Kenyan population. *Clin Anat* 2012;25:198-202.
 29. Mirjalili SA, McFadden SL, Buckenham T, Stringer MD. Vertebral levels of key landmarks in the neck. *Clin Anat* 2012;25:851-7.