

Chalkstick Fracture: A Catastrophic Injury

Abstract

Cervical spine region is known as very prone for injury because it is great mobility. Hyperflexion or hyperextension may create life-threatening injury to ankylosed cervical spine vertebra and spinal cord. The posttrauma result can range from neurological damage to the death. We present a case of a 52-year-old male patient, came to the emergency department with a history of road traffic accident induced quadriplegia and shock. The final diagnosis was chalkstick fracture of spine with complete cord transaction.

Keywords: Ankylosing spondylitis, cervical spine, chalkstick fracture, trauma

Introduction

Ankylosed cervical spine fractures are not uncommon. The word “ankylosis or ankylosis refers for abnormal bone joint adhesion and rigidity in normal movement.^[1] Ankylosing spondylitis is known as a seronegative spondyloarthropathy commonly found at the sacral joints, iliac joints, and in the spine. Because of this, spine can lose articulation, normal architecture and become stiff and weak.^[1] Because of this pathology, low-velocity trauma can create spinal fracture. Surrounding ossified soft tissue and osteoporosis make these types of fractures highly unstable.^[1,2]

Case Report

A 52-year-old man came in emergency with a history of road traffic accident (RTA). He was unable to move his all four limbs and not able to pass urine also. With the old history, he was suffering with ankylosing spondylitis of cervical spine. During RTA, he was going on the motorcycle and suddenly stacked with divider on the road. Because of his helmet, he did not get a head injury, but his cervical spine had absorbed the total trauma force during fall. He was feeling difficulty to take breath. He gave a complete history of incidence by his own but unable to move his limbs and body below the level of neck with abnormal sensations of pin-prick in his body below neck. On general examination, he was in

hypotension with bradycardia, suggestive of spinal shock.

After all postspine trauma safety measures such as cervical collar, spine board, fluid management and airway management, plain radiographs done. Plain radiography of cervical spine [Figure 1] revealed cervical spine C4–C5 level fracture with total displacement with forward bending of cervical spine. Chalkstick fracture of cervical spine was final diagnosis.

After plain radiography, we were planning for magnetic resonance imaging (MRI) to find out severity of cervical cord injury, suddenly, the patient clinical condition course deteriorated and he became unconscious with very low blood pressure. Fiberoptic intubation done and ventilation started. Unfortunately, after all lifesaving attempts, patient died due to cardiac arrest in emergency within 40 min.

Discussion

Several causes can affect the cervical region of spine. The various radiological presentations, clinical scenario, and cause of deaths of ankylosing spondylitis patients complicated by cervical trauma have been described in literature previously. It found most commonly in elderly.^[1] There are very few case reported in literature related specifically with chalkstick fracture. Chalkstick fracture is a traumatic complete fracture of ankylosed cervical spine. Because of rigidity and stiffness, minor trauma can produce devastating injury to cervical region. The most common region

This is an open access journal, and articles are distributed under the terms of the Creative Commons Attribution-NonCommercial-ShareAlike 4.0 License, which allows others to remix, tweak, and build upon the work non-commercially, as long as appropriate credit is given and the new creations are licensed under the identical terms.

For reprints contact: reprints@medknow.com

How to cite this article: Tomar SS. Chalkstick fracture: A catastrophic injury. Asian J Neurosurg 2018;13:383-5.

Suryapratap Singh Tomar

Department of Neurosciences,
Fortis OPJ Hospital, Raigarh,
Chhattisgarh, India

Address for correspondence:
Dr. Suryapratap Singh Tomar,
Department of Neurosciences,
Fortis OPJ Hospital, Raigarh,
Chhattisgarh, India.
E-mail: dr.suryapratap_singh_ tomara@yahoo.com

Access this article online

Website: www.asianjns.org

DOI: 10.4103/ajns.AJNS_167_13

Quick Response Code:



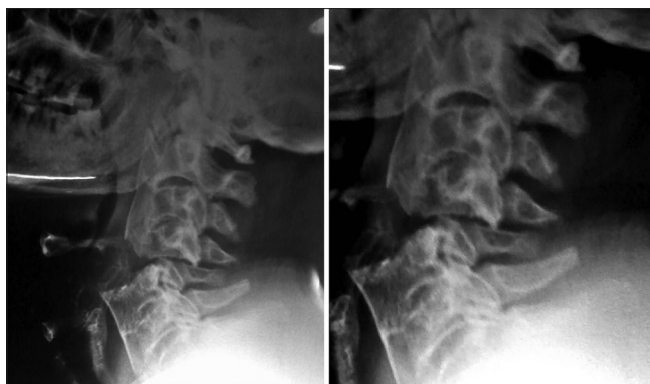


Figure 1: Plain radiograph of cervical spine: Fracture through C4–C5 level with features of ankylosing spondylitis (close-up view reveals total displacement)

of fracture is C5–C6.^[1] This entity often presents with ossification of the posterior longitudinal ligament (OPLL), diffuse idiopathic skeletal hyperostosis (DISH), and the ligamentum flavum ossification (OLF).^[3,4] The involvement of cervical spine in ankylosing spondylitis and other related pathology (OPLL, DISH, and OLF) is very high (75%) as compare to thoracic (15%) and lumbar (10%).^[3,5,6] All of these factors are responsible for heavy calcification with ossification of the ligamentous structures of the cervical spine and which can result as “chalk stick” fractures after minor or major injuries. Chalkstick fractures are very unstable type and very devastating in nature because of the hard and stiff broken ligamentous structures around it. Surrounding degenerated structures such as muscles, tendons, and ligaments use to play notoriously role to make this fracture as a complex life-threatening injury.^[1,7,8] The first and foremost task is quick and correct diagnosis of pathology to reduce the mortality. This can be hidden under the head injury or other external injuries due to polytrauma. Sometimes, plain radiograph can miss a minor fracture at spine and it can transform in grievous complication due to secondary injury.^[9] Computed tomography (CT) scan is best diagnostic choice for bone pathology. A thin 2 mm cut, multislice CT with three-dimensional reconstruction is very helpful to define location, extent and severity.^[10] MRI scanning is best to identify the ligament, perilesional edema, collection of blood/fluid, spinal cord injury, and intraspinal bleeding.^[11] If the fracture involves at the disc space, the chance of neurological deficit or injury will be less and prognosis will be good. Total spinal distraction due to fractures use to associate with poor prognosis.^[1,12] After the diagnostic workup, management of this entity is a herculean task. Total destruction of alignment, displacement of vertebra, and per-injury status of spine plays major role in management. In the absence of deformity, the patient can be managed with conservative management with immobilization with cervical collar support.^[13,14] If deformity is clear and associated with risk of neurological injury, special stabilization technique with surgical procedure is important for betterment of patient and

prevention of secondary injury. Soft or rigid cervical collar, spinal traction techniques and halo traction and fixation are useful if surgical stabilization delays. In the cases of cervical spine injuries, literature suggests use of fiberoptic intubation or the use of a laryngeal mask to ventilate the patient.^[1,2,15] The maintenance of intravascular blood volume with blood pressure is also useful to prevent the spinal cord for ischemia or secondary insult.^[13,14] Once vitals of patient become stable, early definitive stabilization with minimum handling of spinal cord, to prevent the secondary injury, can give fantastic outcomes.^[16] Unfortunately, in our case, the patient died in initial stage due to cardiac arrest. Various operative methods are described in literature such as anterior stabilization, posterior stabilization, and combined anterior and posterior stabilization. Combined anterior and posterior stabilization is more reliable than other method because of maximum stability factor. To correct the spinal stenosis, spinal decompression by laminectomy can be used. For more stability and enhancement of bone growth, autologous bone graft fragments can also use with fixation.^[16-19] Postoperative strict spinal stabilization required minimum for 10–15 days. Then after cervical collar is recommended for 4–6 months.^[16,18,19]

Conclusion

Cervical spine fracture with characteristics of chalkstick type should awake the surgeons and physicians for a big challenge. History of ankylosing spondylitis of cervical spine in victim makes it more worsen. There is a need of standard international registry protocol for primary care of cervical spine injury. Expert radiological evaluation, quick assessment of severity, and disciplined management can change the result and prognosis.

Financial support and sponsorship

Nil.

Conflicts of interest

There are no conflicts of interest.

References

1. Harding JR, McCall IW, Park WM, Jones BF. Fracture of the cervical spine in ankylosing spondylitis. *Br J Radiol* 1985;58:3-7.
2. Westerveld LA, Verlaan JJ, Oner FC. Spinal fractures in patients with ankylosing spinal disorders: A systematic review of the literature on treatment, neurological status and complications. *Eur Spine J* 2009;18:145-56.
3. Al-Jarallah K, Al-Saeed O, Shehab D, Dashti K, Sheikh M. Ossification of ligamentum flavum in Middle East Arabs: A hospital-based study. *Med Princ Pract* 2012;21:529-33.
4. Saetia K, Cho D, Lee S, Kim DH, Kim SD. Ossification of the posterior longitudinal ligament: A review. *Neurosurg Focus* 2011;30:E1.
5. Hirai T, Korogi Y, Takahashi M, Shimomura O. Ossification of the posterior longitudinal ligament and ligamentum flavum: Imaging features. In: *Seminars in Musculoskeletal Radiology*. New York, USA: Thieme Medical Publishers Inc.; Copyright© 2001. p. 83-8.

6. Hirai T, Korogi Y, Yamashita Y, Takahashi M, Shimomura O, Sakae T. Invited: Ossification of posterior longitudinal ligaments: Evaluation with MRI. *J Magn Reson Imaging* 1998;8:398-405.
7. Clarke A, James S, Ahuja S. Ankylosing spondylitis: Inadvertent application of a rigid collar after cervical fracture, leading to neurological complications and death. *Acta Orthop Belg* 2010;76:413-5.
8. Park YS, Kuh SU, Cho YE, Kim YS. Case report treatment of cervical cord injury in ankylosing spondylitis. *J Korean Neurosurg Soc* 2003;34:389-92.
9. Griffen MM, Frykberg ER, Kerwin AJ, Schinco MA, Tepas JJ, Rowe K, *et al.* Radiographic clearance of blunt cervical spine injury: Plain radiograph or computed tomography scan? *J Trauma* 2003;55:222-6.
10. Mirvis SE, Diaconis JN, Chirico PA, Reiner BI, Joslyn JN, Militello P. Protocol-driven radiologic evaluation of suspected cervical spine injury: Efficacy study. *Radiology* 1989;170 (3 Pt 1):831-4.
11. Keiper MD, Zimmerman RA, Bilaniuk LT. MRI in the assessment of the supportive soft tissues of the cervical spine in acute trauma in children. *Neuroradiology* 1998;40:359-63.
12. Thumbikat P, Hariharan RP, Ravichandran G, McClelland MR, Mathew KM. Spinal cord injury in patients with ankylosing spondylitis: A 10-year review. *Spine (Phila Pa 1976)* 2007;32:2989-95.
13. Osenbach R, Menezes A. Spinal cord injury without radiographic abnormality in children. *Pediatr Neurosurg* 1989;15:168-75.
14. Stevens RD, Bhardwaj A, Kirsch JR, Mirski MA. Critical care and perioperative management in traumatic spinal cord injury. *J Neurosurg Anesthesiol* 2003;15:215-29.
15. Heyde CE, Fakler JK, Hasenboehler E, Stahel PF, John T, Robinson Y, *et al.* Pitfalls and complications in the treatment of cervical spine fractures in patients with ankylosing spondylitis. *Patient Saf Surg* 2008;2:15.
16. Murphy KP, Opitz JL, Cabanela ME, Ebersold MJ. Cervical fractures and spinal cord injury: Outcome of surgical and nonsurgical management. *Mayo Clin Proc* 1990;65:949-59.
17. Nassr A, Khan MH, Ali MH, Espiritu MT, Hanks SE, Lee JY, *et al.* Donor-site complications of autogenous nonvascularized fibula strut graft harvest for anterior cervical corpectomy and fusion surgery: Experience with 163 consecutive cases. *Spine J* 2009;9:893-8.
18. Nazarian SM, Louis RP. Posterior internal fixation with screw plates in traumatic lesions of the cervical spine. *Spine (Phila Pa 1976)* 1991;16 3 Suppl:S64-71.
19. Woodworth RS, Molinari WJ, Brandenstein D, Gruhn W, Molinari RW. Anterior cervical discectomy and fusion with structural allograft and plates for the treatment of unstable posterior cervical spine injuries. *J Neurosurg Spine* 2009;10:93-101.