

Solitary Plasmacytoma with Amyloid – An Unusual Dural-Based Lesion

Abstract

Solitary plasmacytoma of the dura without systemic involvement are extremely rare lesions, with <15 cases reported in the literature. Among these, ours is the second case to show the presence of amyloid. Fifty-year-old male had presented with headache, sudden onset right-sided weakness, and vomiting. Magnetic resonance imaging revealed an extra-axial mass in the left fronto-parietal region measuring 10 cm × 8.7 cm × 3.9 cm, suggestive of meningioma. The left fronto-parietal craniotomy was performed and multiple tissue bits aggregating to 10 cm × 8.5 cm × 2 cm along with thinned out membrane-like bit of calvarium was sent for pathologic examination. H and E stained sections showed sheets of plasmacytoid cells along with amyloid, which showed apple-green birefringence on Congo red staining. On immunohistochemistry, tumor cells were positive for CD38, CD138, showed kappa light chain restriction and were negative for CD45, CD34. Hence, it was diagnosed as a plasma cell neoplasm. Further work-up with whole-body positron-emission tomography scan revealed no systemic involvement. Dural-based lesions can mimic meningioma radiographically as well as intraoperatively. Histopathological examination unveils the diagnosis, to guide appropriate therapeutic regimens.

Keywords: Amyloid, dura, immunohistochemistry, plasmacytoma, solitary

Introduction

Meningioma is the most common mass lesion that affects the dura. Other neoplastic lesions less commonly affecting it are metastasis, solitary fibrous tumor/hemangiopericytoma, melanomas or lymphomas.^[1,2] The occurrence of plasmacytomas in this location is an extremely rare event, with a reported incidence of <1%.^[3,4] Solitary plasmacytoma of the dura, without any underlying systemic involvement is even rarer, with <15 cases reported in the literature. We hereby report a case of an adult male with a dural mass presenting as a meningioma, which turned out to be plasmacytoma on histopathological examination, without any systemic involvement.

Case Report

A 50-year-old male, known hypertensive and diabetic on regular medications, presented with headache that was holocranial, moderate to severe in intensity since 5 months. This was followed by right sided weakness, giddiness, along with on and off episodes of vomiting

since 2 months. He had no addictions or no past history of tuberculosis. On examination, the patient was conscious, oriented with stable vitals, with pallor of mild degree and without any icterus, edema or lymphadenopathy. There was hypertonia in right sided upper and lower limbs. Rest of the physical examination was within normal limits.

On investigations, the patient was anemic with a hemoglobin of 10.9 g/dl, while the total leucocyte count and platelet counts were within normal limits. He had normal serum creatinine of 0.8 mg/dl (range: 0.7–1.3 mg/dl) and normal serum calcium levels at 9.3 mg/dl (range: 8.6–10 mg/dl). His serum LDH levels were raised, being 205 U/L (range: 100–190 U/L). Serum β 2-microglobulin levels were 2.28 mg/L (Normal: <3 mg/L). Erythrocyte sedimentation rate was raised to 63 mm at the end of 1 h (<10 mm at the end of 1 h). All the viral markers were nonreactive.

On magnetic resonance imaging, a large homogeneously enhancing dural-based, extra-axial mass lesion was identified in the left fronto-parietal region measuring

**Pooja Kamlesh Gajaria,
Asha Sharad Shenoy,
Jayashri Popat Chaudhari,
Naina Atul Goel**

*Department of Pathology,
Seth G S Medical College, KEM
Hospital, Mumbai, Maharashtra,
India*

Address for correspondence:

*Dr. Asha Sharad Shenoy,
301, Arihant, 613-B, 15th Road,
Khar, Mumbai - 400 052,
Maharashtra, India.
E-mail: shenoyasha@yahoo.
co.in*

Access this article online

Website: www.asianjns.org

DOI: 10.4103/ajns.AJNS_184_20

Quick Response Code:



This is an open access journal, and articles are distributed under the terms of the Creative Commons Attribution-NonCommercial-ShareAlike 4.0 License, which allows others to remix, tweak, and build upon the work non-commercially, as long as appropriate credit is given and the new creations are licensed under the identical terms.

For reprints contact: WKHLRPMedknow_reprints@wolterskluwer.com

How to cite this article: Gajaria PK, Shenoy AS, Chaudhari JP, Goel NA. Solitary plasmacytoma with amyloid – An unusual dural-based lesion. Asian J Neurosurg 2020;15:997-1002.

Submitted: 29-Apr-2020

Revised: 19-Jul-2020

Accepted: 24-Sep-2020

Published: 21-Dec-2020

10 cm × 8.7 cm × 3.9 cm. Overlying skull bone was thinned out. Also noted were effacement of the sulcal spaces, left Sylvian fissure with compression of the left lateral ventricle and midline shift of 2 mm towards the right side. These imaging findings were suggestive of meningioma [Figure 1a and b].

Subsequently, the patient underwent left frontoparietal craniotomy with excision of the tumor. Intraoperatively, it was a frontal, dural-based, extra-axial, moderately vascular tumor and was suggestive of meningioma. At the neuropathology department, we received the tumor for intraoperative consultation. Squash cytology preparations showed a cellular tumor with cells in sheets, dyscohesive clusters, and diffusely spread. Cells had moderate amount of eosinophilic cytoplasm with eccentrically placed nuclei showing cart-wheel like chromatin and a perinuclear hof. Some cells had vesicular nuclei and prominent nucleoli. Few binucleate forms also were seen. A diagnosis of plasma cell neoplasm was given.

Postsurgery, two containers were received, one containing multiple grey brown, soft to firm tissue bits aggregating to 10 cm × 8.5 cm × 2 cm. The other container had a thinned out membrane-like bit of calvarium overlying the tumor measuring 8 cm × 6 cm × 0.1 cm [Figure 1c]. Hematoxylin and eosin stained sections from formalin-fixed paraffin-embedded tissue from the first container revealed a cellular tumor in sheets admixed with spheroidal,

eosinophilic, and acellular structures of varying sizes [Figure 2a and b]. These were surrounded by giant cells. Individual cells showed abundant eosinophilic cytoplasm with eccentrically placed nucleus [Figure 2c]. Few cells showed intracytoplasmic eosinophilic inclusions and moderate pleomorphism. Nuclei varied from spherical to elongate to lobulated. Few binucleate forms were also seen. Occasional mitosis was seen but no necrosis was apparent. Polarizing microscopy of Congo-Red stained slide demonstrated characteristic apple green birefringence, confirming the acellular structures to be amyloid [Figure 2d]. Differentials at this point were plasmacytoma, plasmablastic lymphoma and lymphoplasmacytic meningioma. Sections from the bony tissue in the second container showed marrow spaces without any evidence of plasma cells. For confirmation of the morphological diagnosis, immunohistochemical (IHC) stains were performed. On IHC, tumor cells were positive for CD38, CD138 and showed kappa light chain restriction [Figure 2e], while these were negative for CK, CD34, CD68, S-100, LCA, and CD20. There was focal positivity for epithelial membrane antigen (EMA). The tumor had a low proliferative index of 2%–3% with MIB-1. Hence, a diagnosis of plasmacytoma of the dura was rendered.

Postoperatively, serum electrophoresis was performed which showed M band in the Gamma region with

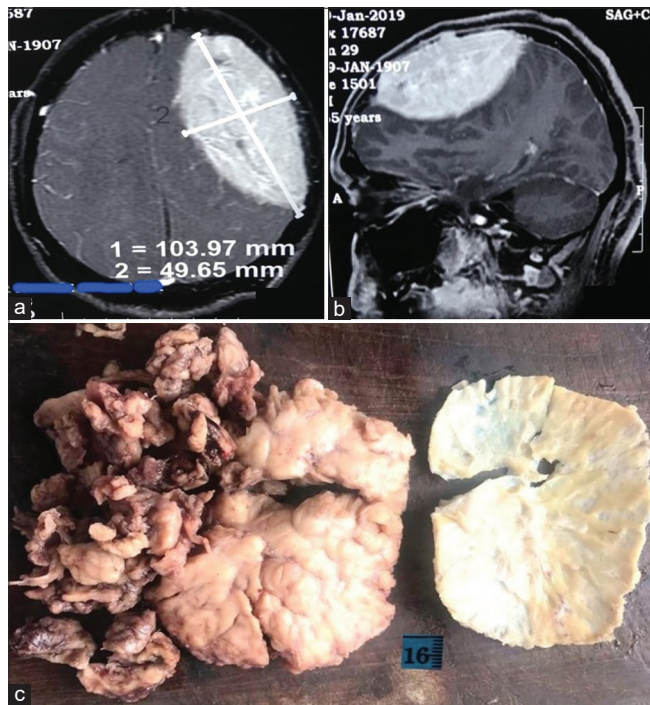


Figure 1: (a) T1 weighted contrast magnetic resonance imaging image showing homogeneously enhancing dural-based lesion in left fronto-parietal region measuring 10.3 cm × 4.9 cm. (b) Sagittal view showing the dural-based mass with no involvement of overlying skull bone. (c) Gross photomicrograph showing multiple grey brown tissue bits and thinned out calvarium

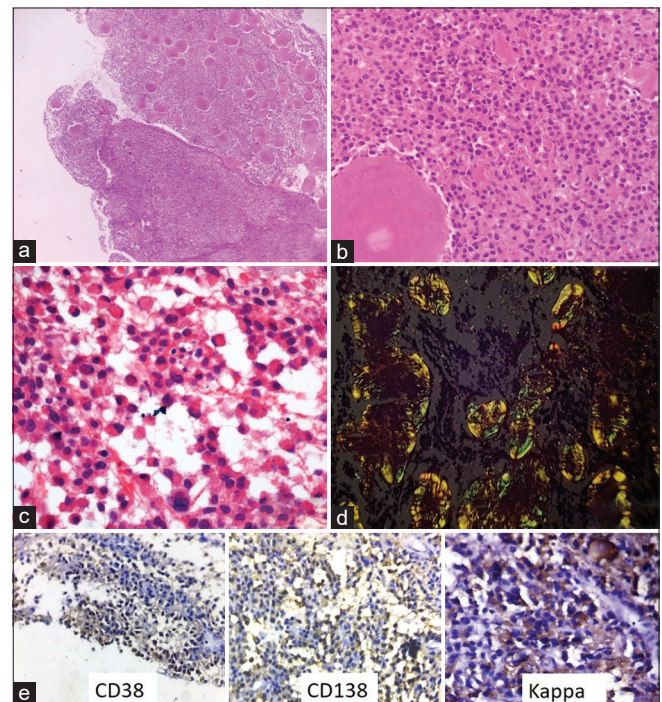


Figure 2: (a) Cellular tumor with cells arranged in sheets along with eosinophilic, acellular material (H and E, ×40). (b) Plasma cells in sheets, few multinucleate cells seen along with eosinophilic, acellular material (H and E, ×100). (c) Polygonal cells with eccentrically placed nuclei and abundant eosinophilic cytoplasm (H and E, ×400). (d) Apple green birefringence on polarizing microscopy (Congo red stain, ×100). (e) Positive immunohistochemical markers – CD38, CD138, Kappa light chain restriction (×400)

the concentration of 700 mg/dl. On nephelometry, immunoglobulin G (IgG) levels were raised at 1650 mg/dl (range: 751–1560 mg/dl) and kappa chains were raised to 1530 mg/dl (range: 629–1350 mg/dl), while IgA, IgM, and Lamda light chains were within normal limits. Thus, a monoclonal band of IgG Kappa type was reported. Urine was negative for Bence Jones proteins. Postoperative bone marrow aspirate and biopsy did not show involvement by plasma cells (2% mature plasma cells were seen). In view of no active metabolic disease anywhere in the body on whole-body positron-emission tomography scan, the patient was planned to be observed with regular follow-up at intervals of every 3 months. The patient is asymptomatic and disease-free, a year after the surgery.

Discussion

Plasma cell neoplasms (PCN) arise due to proliferation of a clone of terminally differentiated B cells that secrete a monoclonal immunoglobulin called M protein and comprises plasma cell myeloma, plasmacytoma, monoclonal immunoglobulin deposition disease and those associated with paraneoplastic syndromes. Plasmacytomas are rare neoplasms accounting for 2%–5% of all the PCN and are defined as single, localized tumors consisting of plasma cells without any clinical or physical or radiological evidence of plasma cell myeloma elsewhere.^[5-7]

The World Health Organization defines two types of plasmacytomas: solitary plasmacytoma of bone and extraosseous solitary (extramedullary) plasmacytoma (SEP).^[7] The International Myeloma Working Group has defined the following four criteria for a lesion to be called as solitary plasmacytoma—(a) Biopsy-proven solitary lesion consisting of clonal plasma cells, (b) Normal bone marrow biopsy with no evidence of clonal plasma cells, (c) Normal skeletal survey and other radiological investigations (except for the primary solitary lesion), and (d) Absence of end-organ damage, such as hypercalcemia, renal insufficiency, anemia, and bone lesions (CRAB).^[8]

Our case met all the above criteria with the lesion confined only to the dura, and hence was a case of SEP. Overall, SEPs are rare neoplasm accounting for approximately 1% of all PCN.^[9] These occur most commonly in the mucous membranes of the upper air passages, followed by the gastrointestinal tract, lymph nodes, bladder, breasts, thyroid, testes, parotid glands, skin, and are extremely rare in the central nervous system.^[9,10]

It is important to differentiate this lesion from morphologically similar neoplasms especially plasmablastic lymphoma and lymphoplasmacyte-rich meningioma, since the former would require aggressive chemotherapy, while the latter may warrant radiotherapy postsurgery depending on the presence of aggressive features/brain invasion.^[11,12]

Plasmablastic lymphoma is more common in the setting of human immunodeficiency virus-positive patients and runs an aggressive course with high proliferative index.^[7] Our patient tested negative for all the viral markers and MIB-1 index was low, with predominance of mature plasma cells. Lymphoplasmacyte-rich meningiomas show an abundance of CD68 positive macrophages, lymphocytes, while plasma cells are mostly inconspicuous. Meningothelial cells, though masked by the inflammatory component, are highlighted by IHC staining with EMA.^[13] In our case, no meningothelial cells were seen and staining for CD68 was negative.

Another benign differential includes a plasma cell granuloma. It is composed of a polyclonal population of mature plasma cells, lymphocytes, histiocytes, giant cells, and xanthomatous cells in a background of fibroblasts and collagenous stroma.^[1,14] Such polymorphous population of cells was absent in our case.

Although rare, dural involvement has been reported in known cases of multiple myeloma.^[15-18] Few authors have also reported it as an incidental finding, where in further investigations led to the diagnosis of a systemic myeloma involvement. These require aggressive chemotherapeutic regimens and are reported to have dismal clinical outcomes.^[19,20] However, the occurrence of dural-based SEP, without systemic myeloma is extremely rare.

SEP of the dura is more commonly reported in the fourth to sixth decade, with only one case occurring in a pediatric patient.^[21] Literature reports female predominance for this lesion, however there seems to be an equal distribution among both the genders.^[22-24] In the era prior to the advent of IHCs, the findings were confirmed by electron microscopy. On electron microscopy, plasma cells showed eccentrically placed nucleus exhibiting clumped chromatin and one or two nucleoli. Endoplasmic reticulum, numerous mitochondria and a highly developed Golgi apparatus were the organelles prominent in the cytoplasm. The endoplasmic reticulum was arranged in a concentric fashion around the nucleus, and was frequently filled with electron-dense material.^[22-26]

M band has been reported in approximately 20% of the patients with SEP and is known to disappear following adequate treatment.^[7] The presence of amyloid as seen in our case, is an extremely rare finding in dural-based lesions and has been reported only by Mancardi *et al.*^[26] Thus, our case becomes the second case of dural-based plasmacytoma showing the presence of amyloid. Some cases of solitary dural-based plasmacytoma reported in the literature are summarized in Table 1.

Overall, SEPs have been reported to progress to multiple myeloma in 15% of the patients.^[7] However, as shown in Table 1, most of the patients with dural-based SEP have shown good overall prognosis. The longest disease free

Table 1: Comparison of dural-based Solitary extramedullary plasmacytoma reported in the literature

Authors (years)	Age (years)/gender	Location	Brain invasion	Anyloid	Monoclonal immunoglobulin	Treatment	Follow-up
Mancilla-Jimenez and Tavassoli, 1976 ^[25]	58/female	Right fronto-temporal and sphenoid area	Yes	Not reported	IgA lambda	Surgery + radiation	Not available
Atweh and Jabbour, 1982 ^[22]	30/female	Right sphenoid wing	Yes	Not reported	-	Surgery + radiation	Not available
Krumholz et al., 1982 ^[3]	56/female	Dura in the middle cranial fossa	Yes	Not reported	-	Surgery + radiation	Alive after 13 years and disease free
Mancardi and Mandybur, 1983 ^[26]	62/male	Tentorium toward the right middle and posterior intracranial fossae	No	Yes	IgG lambda	Surgery + radiation	Disease free at 1 year
Dincer et al., 1994 ^[21]	7/female	Subdural space at the left parieto-occipital region	No	Not reported	-	Surgery + radiation	Not available
Lebrun et al., 1997 ^[27]	60/female; 30/female	Right temporo-parietal region Left frontal region	No	Not reported	-	Surgery + radiation	Not available
Vujovic et al., 1998 ^[28]	56/male	Leptomeninges of left cerebral hemisphere	Yes	Not reported	No M band	Surgery + radiation	Alive at 4 years and free of disease
Manabe et al., 2010 ^[23]	59/male	Right temporal region	Not mentioned	Not reported	IgG kappa	Surgery + radiation Chemotherapy (for recurrence)	Disease progression within a year
Olarinoye-Akorede et al., 2012 ^[4]	41/male	Left fronto-parietal region	No	Not reported	-	Surgery	Alive at 6 years and free of disease
Azarpira et al., 2012 ^[24]	34/male	Left fronto-temporal region	Not mentioned	Not reported	-	Surgery + radiation	No recurrence
Devoe et al., 2014 ^[29]	75/female	Biparietal region	No	No	No M band	Radiation + lenalidomide + dexamethasone	Alive at 5 years and free of disease
Khalili et al., 2015 ^[30]	47/male	Right frontal region	Yes	Not reported	No M band	Surgery + radiation	Alive at 9 months and free of disease
Our case, 2020	50/male	Left fronto-parietal region	No	Yes	IgG kappa	Surgery	Free of disease at 1 year

survival has been reported by Krumholz *et al.*, where in their patient was disease free even over a follow-up period of 13 years, and only the case reported by Manabe *et al.*, has shown disease progression within a year.^[3,23]

Plasmacytomas are radiosensitive tumors. Dural-based SEPs can be treated by surgery or radiotherapy or both.^[31] Devoe *et al.* have shown benefit in their patient, who was treated with radiotherapy followed by lenalidomide and dexamethasone, since she could not be operated upon, in view of her old age and other comorbidities.^[29] Our patient had no evidence of residual tumor on postoperative scans and therefore has been planned to be observed with close follow-up.

It has been reported that repeated antigenic stimulation can lead to plasmacytomas. Predilection for the occurrence of SEP in dural-based locations can be attributed to the occurrence of arachnoid granulations that act as absorbing filters for cerebrospinal fluid and are therefore subjected to high degree of such stimulation.^[22] Atypical plasma cell hyperplasia has been reported to be a preneoplastic lesion for plasmacytomas.^[32]

Although relatively rare, other lesions can mimic meningiomas radiographically as well as intra-operatively. Rare differentials should be kept in mind by the reporting pathologist, and ruled out with the help of morphology as well as by ancillary tests, in order to guide appropriate therapeutic regimens.

Declaration of patient consent:

The authors certify that they have obtained all appropriate patient consent forms. In the form the patient(s) has/have given his/her/their consent for his/her/their images and other clinical information to be reported in the journal. The patients understand that their names and initials will not be published and due efforts will be made to conceal their identity, but anonymity cannot be guaranteed.

Financial support and sponsorship

Nil.

Conflicts of interest

There are no conflicts of interest.

References

- Johnson MD, Powell SZ, Boyer PJ, Weil RJ, Moots PL. Dural lesions mimicking meningiomas. *Hum Pathol* 2002;33:1211-26.
- Lyndon D, Lansley JA, Evanson J, Krishnan AS. Dural masses: Meningiomas and their mimics. *Insights Imaging* 2019;10:11.
- Krumholz A, Weiss HD, Jiji VH, Bakal D, Kirsh MB. Solitary intracranial plasmacytoma: Two patients with extended follow-up. *Ann Neurol* 1982;11:529-32.
- Olarinoye-Akorede SA, Jimoh AO, Chom ND, Akano AO, Hamidu AU, Abdullahi K. Solitary craniocerebral plasmacytoma mimicking a meningioma. *J Biomed Graph Comput* 2012;2:110-4.
- Dimopoulos MA, Hamilos G. Solitary bone plasmacytoma

- and extramedullary plasmacytoma. *Curr Treat Options Oncol* 2002;3:255-9.
- Dores GM, Landgren O, McGlynn KA, Curtis RE, Linet MS, Devesa SS. Plasmacytoma of bone, extramedullary plasmacytoma, and multiple myeloma: Incidence and survival in the United States, 1992-2004. *Br J Haematol* 2009;144:86-94.
- McKenna RW, Kyle RA, Kuehl WM, Harris NL, Coupland RW, Fend F. Plasma cell neoplasms. In: Swerdlow SH, editor. *Who Classification of Tumours of Haematopoietic and Lymphoid Tissues*, Revised. 3rd ed. Lyon: IARC; 2017. p. 241-53.
- Rajkumar SV. Updated diagnostic criteria and staging system for multiple myeloma. *Am Soc Clin Oncol Educ Book* 2016;35:e418-23.
- Alexiou C, Kau RJ, Dietzfelbinger H, Kremer M, Spiess JC, Schratzenstaller B, *et al.* Extramedullary plasmacytoma: Tumor occurrence and therapeutic concepts. *Cancer* 1999;85:2305-14.
- Galièni P, Cavo M, Pulsoni A, Avvisati G, Bigazzi C, Neri S, *et al.* Clinical outcome of extramedullary plasmacytoma. *Haematologica* 2000;85:47-51.
- Castillo JJ, Bibas M, Miranda RN. The biology and treatment of plasmablastic lymphoma. *Blood* 2015;125:2323-30.
- Sun SQ, Hawasli AH, Huang J, Chicoine MR, Kim AH. An evidence-based treatment algorithm for the management of WHO Grade II and III meningiomas. *Neurosurg Focus* 2015;38:E3.
- Perry A, Louis DN, Budka H, von Deimling A, Sahm F, Rushing EJ. Meningioma. In: Louis DN, editor. *Who Classification of Tumours of the Central Nervous System*, Revised. 4th ed. Lyon: IARC; 2016. p. 232-45.
- Kim DJ, Choi YS, Song YJ, Kim KU. Intracranial plasma cell granuloma. *J Korean Neurosurg Soc* 2009;46:161-4.
- Kaneko D, Irikura T, Taguchi Y, Sekino H, Nakamura N. Intracranial plasmacytoma arising from the dura mater. *Surg Neurol* 1982;17:295-300.
- Roddie P, Collie D, Johnson P. Myelomatous involvement of the dura mater: A rare complication of multiple myeloma. *J Clin Pathol* 2000;53:398-9.
- Rahmah N, Brotoarianto H, Andor E, Kusnarto G, Muttaqin Z, Hongo K. Dural plasmacytoma mimicking meningioma in a young patient with multiple myeloma. *Biomed Imaging Interv J* 2009;5:e5.
- Gascón N, Pérez-Montero H, Guardado S, D'Ambrosi R, Cabeza MÁ, Pérez-Regadera JF. Dural plasmacytoma with meningeal myelomatosis in a patient with multiple myeloma. *Case Rep Hematol* 2018;2018:6730567.
- Haegelen C, Riffaud L, Bernard M, Carsin-Nicol B, Morandi X. Dural plasmacytoma revealing multiple myeloma. *Case report. J Neurosurg* 2006;104:608-10.
- Morgenstern P, Pisapia D, Ramakrishna R. Calvarial plasmacytoma mimicking meningioma as the initial presentation of multiple myeloma. *Cureus* 2017;9:e1126.
- Dincer C, Mustafa B, Yuçeer N. Solitary intracranial plasmacytoma in a child report of a 7-year-old girl. *Turk Neurosurg* 1994;4:47-50.
- Atweh GF, Jabbour N. Intracranial solitary extraskeletal plasmacytoma resembling meningioma. *Arch Neurol* 1982;39:57-9.
- Manabe M, Kanashima H, Yoshii Y, Mukai S, Sakamoto E, Iwai Y, *et al.* Extramedullary plasmacytoma of the dura mimicking meningioma. *Int J Hematol* 2010;91:731-2.
- Azarpira N, Noshadi P, Pakbaz S, Torabineghad S, Rakei M, Safai A. Dural plasmacytoma mimicking meningioma. *Turk Neurosurg* 2014;24:403-5.

25. Mancilla-Jimenez R, Tavassoli FA. Solitary meningeal plasmacytoma: Report of a case with electron microscopic and immunohistologic observations. *Cancer* 1976;38:798-806.
26. Mancardi GL, Mandybur TI. Solitary intracranial plasmacytoma. *Cancer* 1983;51:2226-33.
27. Lebrun C, Chanalet S, Paquis P, Frenay M, Lagrange JL, Chatel M. Solitary meningeal plasmacytomas. *Ann Oncol* 1997;8:791-5.
28. Vujovic O, Fisher BJ, Munoz DG. Solitary intracranial plasmacytoma: Case report and review of management. *J Neurooncol* 1998;39:47-50.
29. Devoe CE, Li JY, Demopoulos AM. The successful treatment of a recurrent intracranial, dural-based plasmacytoma with lenalidomide. *J Neurooncol* 2014;119:217-20.
30. Khalili RP, Mokhtari M, Fard SA, Neshat A, Norouzi R. Solitary dural plasmacytoma with parenchymal invasion. *Asian J Neurosurg* 2015;10:102-4.
31. Provenzale JM, Schaefer P, Traweek ST, Ferry J, Moore JO, Friedman AH, *et al.* Craniocerebral plasmacytoma: MR features. *AJNR Am J Neuroradiol* 1997;18:389-92.
32. Weidenheim KM, Campbell WG Jr, Goldman HW. Atypical monoclonal plasma cell hyperplasia of the central nervous system: Precursor of plasmacytoma with evolutionary considerations. *Neurosurgery* 1989;24:429-34.