

## Endoscopic Third Ventriculostomy in Noncommunicating Hydrocephalus: Report on a Short Series of 53 Children

### Abstract

**Introduction:** Endoscopic third ventriculostomy (ETV) is currently considered the best alternative to cerebrospinal fluid (CSF) shunt systems in the treatment of obstructive hydrocephalus. The aim of ETV is to communicate the third ventricle with the interpeduncular cistern and create CSF flow which bypasses an obstruction to the circulation of the CSF. **Aims and Objectives:** The purpose of this study was to elucidate the indications, efficacy, safety and outcome Of ETV pediatric patients of noncommunicating hydrocephalus. **Material and Methods:** This study is a 3 year prospective study from June 2012 to May 2015. Records were kept for age, gender, etiological factors, symptoms, signs, previous use of shunt or external ventricular device, imaging findings, and surgical complications (intraoperative and postoperative). Only those patients with age between 6months and 18 years with symptoms of intracranial hypertension and radiographic evidence of noncommunicating hydrocephalus were included in the study. **Results:** A total of 53 patients were studied, out of these 29 were boys and 24 were girls. The mean age of the patients was 6.6 years. Overall a total of 50 successful ETVs were done in 53 patients. The success rate is estimated to be 94%. There was no mortality. The average postoperative hospital stay was 4 days. The followup ranged from 6 to 16 months (mean, 12 months). **Conclusion:** ETV in children is a safe, simple and effective treatment and a logical alternative to shunting procedure for patients of noncommunicating hydrocephalus.

**Keywords:** Endoscopic third ventriculostomy, hydrocephalus, shunt failure

### Introduction

The first successful endoscopic third ventriculostomy (ETV) was performed by Mixer, a urologist in Chicago in 1923.<sup>[1]</sup> However, ventriculoperitoneal shunt (VPS) is still the most common procedure for hydrocephalus. The rate of long-term shunt failure in an individual going from childhood through adulthood over a 20-year period is in the range of 80%.<sup>[2]</sup>

Against this background, ETV is currently considered the best alternative to cerebrospinal fluid (CSF) shunt systems in the treatment of triventricular hydrocephalus. The aim of ETV is to communicate the third ventricle with the interpeduncular cistern and create CSF flow which bypasses an obstruction to the circulation of the CSF.<sup>[3]</sup>

### Patients and Methods

This study is a 3-year prospective study from June 2012 to May 2015. This study was carried out in the Departments of Neurosurgery, Radiodiagnosis, and

This is an open access journal, and articles are distributed under the terms of the Creative Commons Attribution-NonCommercial-ShareAlike 4.0 License, which allows others to remix, tweak, and build upon the work non-commercially, as long as appropriate credit is given and the new creations are licensed under the identical terms.

For reprints contact: reprints@medknow.com

Neuroanesthesiology, Sher-I-Kashmir Institute of Medical Sciences, Srinagar, Jammu and Kashmir, India. Records were kept for age, gender, etiological factors, symptoms, signs, previous use of shunt or external ventricular device, imaging findings including Evans ratio, and surgical complications (intraoperative and postoperative). Only those patients who had symptoms of intracranial hypertension and radiographic evidence of noncommunicating hydrocephalus were the candidates for the procedure. Patients with age range 6 months to 18 years and who presented with symptoms of raised intracranial hypertension and imaging showed of noncommunicating hydrocephalus were included in the study.

### Surgical technique

The burr hole was placed in the right prefrontal area in the mid-pupillary line just anterior to the coronal suture. The optimal trajectory into the third ventricle through the foramen of Monro and into the interpeduncular cistern is usually

**How to cite this article:** Sarmast A, Khursheed N, Ramzan A, Shaheen F, Wani A, Singh S, *et al.* Endoscopic third ventriculostomy in noncommunicating hydrocephalus: Report on a short series of 53 children. Asian J Neurosurg 2019;14:35-40.

Arif Sarmast,  
Nayil Khursheed,  
Altaf Ramzan,  
Feroz Shaheen<sup>1</sup>,  
Abrar Wani,  
Sarbjit Singh,  
Zulfikar Ali<sup>2</sup>,  
Bashir Dar<sup>2</sup>

Departments of Neurosurgery,  
<sup>1</sup>Radiodiagnosis and  
<sup>2</sup>Neuroanesthesiology,  
Sher-I-Kashmir Institute of  
Medical Sciences, Srinagar,  
Jammu and Kashmir, India

### Address for correspondence:

Dr. Nayil Khursheed,  
Department of Neurosurgery,  
Sher-I-Kashmir Institute  
of Medical Sciences,  
Srinagar - 190 011,  
Jammu and Kashmir, India.  
E-mail: nayilkhursh@gmail.com

### Access this article online

Website: www.asianjns.org

DOI: 10.4103/ajns.AJNS\_187\_16

### Quick Response Code:



achieved with this burr hole. A rigid 0° endoscope in a 4.6-mm double irrigating sheath (Aesculap, Tuttlingen, Germany) would be introduced into the lateral ventricle by following the catheter under video guidance. ETV was performed in supine position with head flexed so that the burr hole site was at the highest point. The foramen of Monro was identified by the confluence of thalamostriate vein, septal vein, and choroid plexuses. Ringer's lactate at a temperature of 90°F was used for irrigation. Perforation in the third ventricle floor was made after negotiating endoscope through the foramen of Monro and then puncturing with cautery probe in between mammillary bodies and infundibular recess at the most transparent site. An initial fenestration was then dilated by inflating Fogarty catheter. Gelfoam plug (Pfizer Inc., New York, USA) was inserted into the cortical tract at the end of the procedure.

### Postoperative follow-up

Patients were generally discharged from the hospital on the 2<sup>nd</sup> or 3<sup>rd</sup> postoperative day unless some complication arose. They were followed up at 2 weeks, 1, 3, and 6 months postoperatively and every 6 months thereafter. A postoperative follow-up magnetic resonance imaging/computed tomography (MRI/CT) scan brain was done after 3 months to see the ventricular size; however, if patient developed features suggestive of failed ETV, then imaging was done earlier. Cine phase-contrast (PC) MRI was done in all patients and used to determine the patency of the stoma. No flow across the stoma was taken as the sign of stoma closure.

Success was defined as the avoidance of shunt insertion and relief from symptoms of elevated intracranial pressure, such as irritability and vomiting, resolution of eye findings (for example, sunsetting or sixth cranial nerve palsy), and a decrease or arrest in ventriculomegaly as determined on ultrasonography (in infants and children with open anterior fontanelle) or MRI/CT scanning using Evans index or fronto-occipital horn ratio and also demonstration of CSF flow on cine PC MRI through the newly formed stoma in the floor of the third ventricle.

### Statistical analysis

All the information were recorded in a prestructured pro forma, and data were analyzed by Statistical Package for Social Sciences version 19, Chicago, IL, USA. Statistical significance was defined as  $P \leq 0.05$ .

### Results

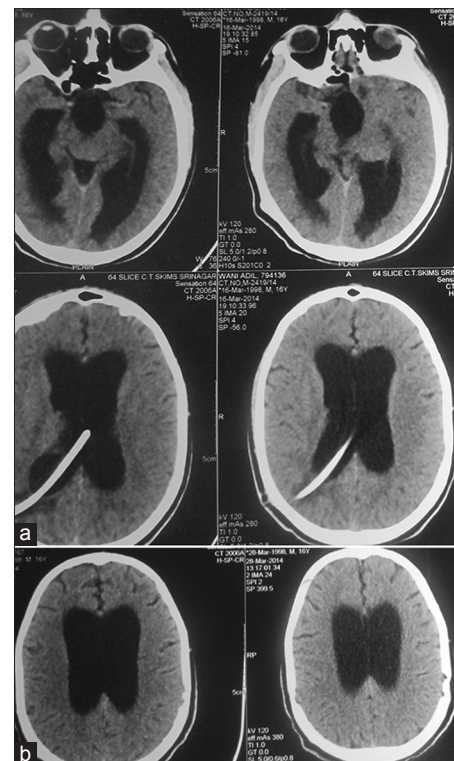
A total of 53 patients were studied, 29 (54.7%) were boys and 24 (45.3%) were girls. The mean age of the patients was 6.6 years. The most common symptoms were headache and increased head size [Table 1]. The etiological factors for hydrocephalus are given in Table 2. A total of 52 successful ETVs were done in 53 patients, out of which on follow-up, two patients had to be reoperated upon. The success rate

for the procedure was 98% (52/53). There was no mortality related to the procedure. One patient experienced repeated seizures in the early postoperative period but responded well to antiepileptic treatment. Three patients experienced CSF leak, which responded to conservative management. No lumbar puncture was required. The average postoperative hospital stay was 4 days. We were not able to complete the procedure in one patient. In this case, we could navigate the endoscope to the floor of the third ventricle; however, defining the landmarks was not possible. A VPS was placed in the same setting.

Nine patients underwent ETV for malfunction of a preexisting VPS [Figure 1], with 100% success in this subgroup. Out of these nine patients, seven patients had

**Table 1: Clinical presentation**

Presentation	Number of patients
Headache	42
Increased head circumference	32
Gait disturbance	23
Bulging fontanelle	23
Nausea and vomiting	17
Urinary incontinence	16
Locomotor ataxia	16
Altered mental status	13
Hemiparesis	7
Parinaud's syndrome	4



**Figure 1: Computed tomography scan axial sections show malfunctioning shunt (a), postendoscopic third ventriculostomy size of the ventricles has not changed though (b) (though patient improved clinically)**

VPS placements for aqueductal stenosis and two had hydrocephalus due to obstruction by a tumor. The duration between the initial VPS to subsequent ETV in this entire group of nine patients ranged from 5 to 13 years.

Kaplan–Meier survival analysis did not show any correlation between different age groups, i.e., 6 months - 2 years, >2–5 years, >5–10 years, and >10 years and ETV failure rate,  $P = 0.60$  (not significant) [Figure 2a] nor between different indications of ETV and failure rates,  $P = 0.38$  (not significant) [Figure 2b].

On follow-up, clinical improvement did not necessarily correlate well with the radiological improvement [Table 3]. Out of 53 patients, reduction in ventricle size was achieved in 33 patients (62.27%) [Figure 3], but ventricle size did not change in 20 (37.73%) [Figure 1]. However, cine PC MRI was used in all the patients for checking the effectiveness of ETV in postoperative period and showed a flow in all but two patients [Figure 4]. These two patients had a secondary ETV failure. MRI in one of these patients showed CSF flow through the stoma and another showed stenosis of the stoma. The former patient had a VPS placement and the later had a repeat ETV done.

## Discussion

ETV has been popularized due to the fact that, if successful, a shunt-free period is guaranteed and a lifelong dependency

on a VPS could be avoided. ETV has been established as a reasonable alternative to VPS and ventriculoatrial shunts (VASs) or as treatment for VPS/VAS failure. The central dogma that “a shunt is always a shunt” has been disfranchised with the experience with ETV. The main issue related to ETV is whether if it is a safer and better treatment for pediatric patients with hydrocephalus as compared to VPS/VAS.<sup>[4-6]</sup>

Although different opinions exist in the literature about the effectiveness of ETV in children under 1-year age,<sup>[7-10]</sup> the question whether infants and very young children have a higher risk of treatment failure after ETV than older children is still being debated. There seems to be growing evidence that the success of ETV depends mainly on the etiology of the hydrocephalus and not on the age of the patient alone.<sup>[11-16]</sup> In their study, Cinalli *et al.*<sup>[15]</sup> have shown that ETV could be successfully performed even in patients <6 months of age even though this young age was previously considered a contraindication.<sup>[17]</sup> In their study, Gorayeb *et al.*<sup>[16]</sup> reported a success rate of 64% in children younger than 1 year who have undergone ETV for obstructive hydrocephalus and they advocated the use of ETV when appropriate regardless of age younger than 1 year. In our series, only children >6 months of age were included because most of the literature reports a higher incidence of ETV failure in patients <6 months of age.<sup>[17,18]</sup>

**Table 2: Etiology of hydrocephalus in relation to procedure outcome, success, and complications**

Cause of hydrocephalus on imaging	Number of cases	Procedure success	Outcome on follow-up	Complications
Posterior fossa mass	7	7/7	7/7	1/7 CSF leak
Myelomeningocele associated	11	10/11	9/10	1/11 stomal block* 1/11 CSF leak
Primary aqueductal stenosis	15	15/15	14/15	1/15 persistent hydrocephalus, however stoma on cine MRI was open
Posterior third ventricular mass/cyst	6	6/6	5/6	1/6 seizure 1/6 stomal block
Previous VPS failure	9	9/9	8/9	1/9 CSF leak
Dandy-Walker syndrome	5	5/5	5/5	
Total	53	52/53	50/53	7 complications

This patient needed VPS. VPS – Ventriculoperitoneal shunt; CSF – Cerebrospinal fluid; MRI – Magnetic resonance imaging

**Table 3: Assessment of radiological effectiveness of endoscopic third ventriculostomy in noncommunicating hydrocephalus of various etiologies**

Etiology of hydrocephalus (number of patients)	Reduction of ventricular diameter	Ventricular diameter unchanged
Posterior fossa mass (7)	4	3
Myelomeningocele associated (11)	7	4
Primary aqueductal stenosis (15)	11	4
Posterior third ventricular mass (6)	4	2
Previous VPS failure (9)	5	4
Dandy-Walker syndrome (5)	2	3
Total (53) (%)	33 (62.27)	20 (37.73)

VPS – Ventriculoperitoneal shunt



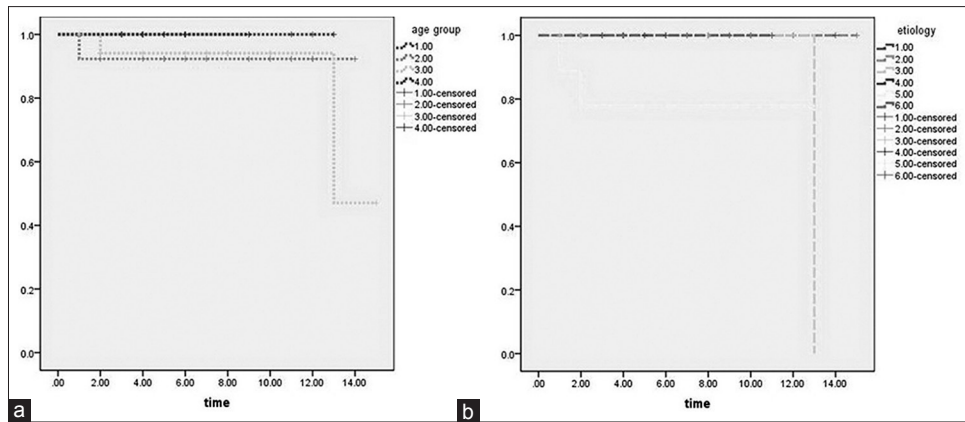


Figure 2: Kaplan–Meier analysis shows no relation of age (a) and etiology of hydrocephalus (b) on endoscopic third ventriculostomy success rate

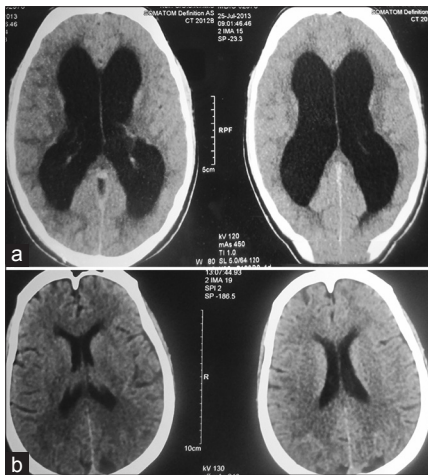


Figure 3: Computed tomography scan axial sections show hydrocephalus (a), postoperative third ventriculostomy ventricle size has reduced (b)



Figure 4: Postoperative third ventriculostomy cine phase magnetic resonance imaging shows good flow across the stoma

Our patients with a previous VPS and known obstructive hydrocephalus (aqueduct stenosis or tumor) were optimal candidates for ETV even if the VPS was performed many years before. Woodworth *et al.*<sup>[19]</sup> reported 71% immediate success with ETV for obstructive hydrocephalus in patients

with VPS obstruction, but only 25% remained recurrence free after 2 years. Baldauf *et al.*<sup>[20]</sup> reported a 60% success rate with ETV in obstructed VPS in a mixed pediatric and adult population but advised against ETV if no obstruction was identified on MRI. In our series, we did have late failure in one out of nine cases. In this patient, cine phase MRI was done which showed closure of stoma, hence a repeat ETV was performed.

On follow-up, a total of fifty successful ETVs were done in 53 patients. The success rate is estimated to be 94% which is in concordance with various other reported studies in literature.<sup>[16-19]</sup> Among factors that have been advocated as possible failure scenarios are: age <1 year, preexisting shunt infection, and postoperative infection.<sup>[16,21-25]</sup>

In our study, we did not get a statistically significant correlation between age and ETV failure or etiology of hydrocephalus and ETV failure ( $P > 0.05$ ). This however could be because of the small sample size and an overall very low complication rate in our series.

We were not able to complete the procedure in one patient. In this case, we could not navigate the endoscope to the floor of the third ventricle; however, defining the landmarks was not possible. A VPS was placed in the same setting. Many endoscopists report one or two failures in their series and some have even reported a 31% failure rate.<sup>[8,26]</sup>

Puncturing the third ventricular floor when it is opaque is dangerous and should not be done. The major risk is that of basilar artery injury. In such situation, indocyanine green (ICG) dye administered intravenously can visualize the vessels under green filter and hence prevent injury.<sup>[27]</sup> We did not have such a technological support.

It is well known that the radiological improvements after ETV are less than that in postshunt, as the fluid is maintained in the same physiological space, the ventricle will not shrink as in a patient who has functioning shunt. Nowoslawska *et al.*<sup>[28]</sup> studied the ventricle size and head enlargement after ETV and compared these with patients who have a shunt and concluded that patients treated with

ETV have larger ventricle and head circumference but that this is not related to their clinical improvements. This belief is shared by many authors.<sup>[29,30]</sup>

In our study, radiological improvement was found in 62.26% (33/53) of patients whereas 94% patients improved clinically which supports the fact ETV restores the disturbed CSF flow to a particular set point rather than merely decreasing the size of the ventricle.

The literature describes a number of complications that were not encountered in our series. Such complications include pituitary stalk and hypothalamic damage that usually presents itself as diabetes insipidus.<sup>[31,32]</sup> Cardiac arrhythmias and respiratory arrest could occur due to hypothalamic irritation and manipulation.<sup>[33,34]</sup> The most feared of these complications is damage to vascular structures such as the basilar artery due to the proximity in the perforation field.<sup>[35,36]</sup>

Basilar artery injury occurs if the fenestration in the floor of the third ventricle is made with potassium titanyl phosphate laser<sup>[37]</sup> even blunt perforations made with endoscope or Fogarty balloon also have resulted in basilar artery injury.<sup>[38]</sup>

To avoid basilar artery injury, microvascular Doppler probes have been used to identify the artery;<sup>[39]</sup> if the floor is not transparent intravenous ICG dye, administration has been used to visualize the basilar artery through the opaque third ventricular floor.<sup>[27]</sup>

There are reports of failure of ETV. It can be early or late. Early occurs within 4 weeks and late after this period. Inability to absorb CSF leads to early failure, whereas gliosis of the stoma causes late failure. We also had two cases of ETV failure, one belonging to each group. We managed early failure by VPS and late by a repeat ETV as has been recommended.<sup>[18]</sup>

In general, the rate of complications for neuroendoscopic interventions, particularly ETV, is reported to be between 6% and 20%.<sup>[18,29,34,40]</sup>

Our morbidity rate remained low at 13% (7/53) and we had no mortality. The complications encountered in our experience were the emergence of postoperative CSF leak in three patients, seizure in one patient, and ETV failure in two patients, which are all in concordance with many recently published studies.<sup>[41-43]</sup>

## Conclusion

ETV, when performed correctly by an experienced surgeon, is a safe, simple, and effective treatment and a logical alternative to VPS for patients of noncommunicating hydrocephalus. Radiological improvements after ETV are less than that in postshunt, as the fluid is maintained in the same physiological space, the ventricle will not shrink as in a patient who has functioning shunt. The primary result of

ETV procedures performed for patients who present with shunt malfunction is encouraging, thus allowing for more shunt-free patients. In general, the rate of complications and failure rates for ETV is reported to be low. Each ingredient of technological advancement in the form of microvascular Doppler or ICG dye can enhance the safety of ETV in children. Neurosurgeons should be encouraged to do more of endoscopic CSF diversion procedures in children as the results are encouraging.

## Financial support and sponsorship

Nil.

## Conflicts of interest

There are no conflicts of interest.

## References

- Mixer WJ. Ventriculocopy and puncture of the floor of the third ventricle. *Boston Med J* 1923;188:277-8.
- Paulsen AH, Lundar T, Lindegaard KF. Twenty-year outcome in young adults with childhood hydrocephalus: Assessment of surgical outcome, work participation, and health-related quality of life. *J Neurosurg Pediatr* 2010;6:527-35.
- Feng H, Huang G, Liao X, Fu K, Tan H, Pu H, *et al.* Endoscopic third ventriculostomy in the management of obstructive hydrocephalus: An outcome analysis. *J Neurosurg* 2004;100:626-33.
- Reddy GK, Bollam P, Caldito G, Guthikonda B, Nanda A. Ventriculoperitoneal shunt surgery outcome in adult transition patients with pediatric-onset hydrocephalus. *Neurosurgery* 2012;70:380-8.
- Boschert J, Hellwig D, Krauss JK. Endoscopic third ventriculostomy for shunt dysfunction in occlusive hydrocephalus: Long-term follow up and review. *J Neurosurg* 2003;98:1032-9.
- Jaksche H, Loew F. Burr hole third ventriculo-cisternostomy. An unpopular but effective procedure for treatment of certain forms of occlusive hydrocephalus. *Acta Neurochir (Wien)* 1986;79:48-51.
- Jones RF, Stening WA, Brydon M. Endoscopic third ventriculostomy. *Neurosurgery* 1990;26:86-91.
- Buxton N, Macarthur D, Mallucci C, Punt J, Vloeberghs M. Neuroendoscopy in the premature population. *Childs Nerv Syst* 1998;14:649-52.
- Ambesh SP, Kumar R. Neuroendoscopic procedures: Anesthetic considerations for a growing trend: A review. *J Neurosurg Anesthesiol* 2000;12:262-70.
- de Resende MA, da Silva EV, Nascimento OJ, Gemal AE, Quintanilha G, Vasconcelos EM. Total intravenous anesthesia (TIVA) in an infant with Werdnig-Hoffmann disease. Case report. *Rev Bras Anesthesiol* 2010;60:170-5.
- Beems T, Grotenhuis JA. Is the success rate of endoscopic third ventriculostomy age-dependent? An analysis of the results of endoscopic third ventriculostomy in young children. *Childs Nerv Syst* 2002;18:605-8.
- Etus V, Ceylan S. Success of endoscopic third ventriculostomy in children less than 2 years of age. *Neurosurg Rev* 2005;28:284-8.
- Javadpour M, Mallucci C, Brodbelt A, Golash A, May P. The impact of endoscopic third ventriculostomy on the management of newly diagnosed hydrocephalus in infants. *Pediatr Neurosurg* 2001;35:131-5.

14. Balthasar AJ, Kort H, Cornips EM, Beuls EA, Weber JW, Vles JS. Analysis of the success and failure of endoscopic third ventriculostomy in infants less than 1 year of age. *Childs Nerv Syst* 2007;23:151-5.
15. Cinalli G, Sainte-Rose C, Chumas P, Zerah M, Brunelle F, Lot G, *et al.* Failure of third ventriculostomy in the treatment of aqueductal stenosis in children. *J Neurosurg* 1999;90:448-54.
16. Gorayeb RP, Cavalheiro S, Zymberg ST. Endoscopic third ventriculostomy in children younger than 1 year of age. *J Neurosurg* 2004;100 5 Suppl Pediatrics: 427-9.
17. Leach P, Thorne J, Palmer J. Response to: Ten years of experience with paediatric neuroendoscopic third ventriculostomy features and perioperative complications of 210 cases. *J Neurosurg Anesthesiol* 2005;17:172.
18. Mohanty A, Vasudev MK, Sampath S, Radhesh S, Sastry Kolluri VR. Failed endoscopic third ventriculostomy in children: Management options. *Pediatr Neurosurg* 2002;37:304-9.
19. Woodworth G, McGirt MJ, Thomas G, Williams MA, Rigamonti D. Prior CSF shunting increases the risk of endoscopic third ventriculostomy failure in the treatment of obstructive hydrocephalus in adults. *Neurol Res* 2007;29:27-31.
20. Baldauf J, Oertel J, Gaab MR, Schroeder HW. Endoscopic third ventriculostomy in children younger than 2 years of age. *Childs Nerv Syst* 2007;23:623-6.
21. Koch D, Wagner W. Endoscopic third ventriculostomy in infants of less than 1 year of age: Which factors influence the outcome? *Childs Nerv Syst* 2004;20:405-11.
22. Fritsch MJ, Kienke S, Ankermann T, Padoin M, Mehdorn HM. Endoscopic third ventriculostomy in infants. *J Neurosurg* 2005;103 1 Suppl: 50-3.
23. Koch-Wiewrodt D, Wagner W. Success and failure of endoscopic third ventriculostomy in young infants: Are there different age distributions? *Childs Nerv Syst* 2006;22:1537-41.
24. Kombogiorgas D, Sgouros S. Assessment of the influence of operative factors in the success of endoscopic third ventriculostomy in children. *Childs Nerv Syst* 2006;22:1256-62.
25. Levy ML, Masri LS, McComb JG. Outcome for preterm infants with germinal matrix hemorrhage and progressive hydrocephalus. *Neurosurgery* 1997;41:1111-7.
26. Hoffman HJ, Harwood-Nash D, Gilday DL. Percutaneous third ventriculostomy in the management of noncommunicating hydrocephalus. *Neurosurgery* 1980;7:313-21.
27. Wachter D, Behm T, von Eckardstein K, Rohde V. Indocyanine green angiography in endoscopic third ventriculostomy. *Neurosurgery* 2013;73 1 Suppl Operative: ons67-72; ons72-3.
28. Nowoslawska E, Polis L, Kaniewska D, Mikołajczyk W, Krawczyk J, Szymanski W, *et al.* Influence of neuroendoscopic third ventriculostomy on the size of ventricles in chronic hydrocephalus. *J Child Neurol* 2004;19:579-87.
29. Baykan N, Isbir O, Gerçek A, Dagçınar A, Ozek MM. Ten years of experience with pediatric neuroendoscopic third ventriculostomy: Features and perioperative complications of 210 cases. *J Neurosurg Anesthesiol* 2005;17:33-7.
30. Buxton N. Neuroendoscopic third ventriculostomy. *Neurosurg Focus* 1999;6:e2.
31. Di Roio C, Mottolise C, Cayrel V, Berlier P, Artru F. Ventriculostomy of the third ventricle and diabetes insipidus. *Ann Fr Anesth Reanim* 1999;18:776-8.
32. Grant JA, McLone DG. Third ventriculostomy: A review. *Surg Neurol* 1997;47:210-2.
33. Enya S, Masuda Y, Terui K. Respiratory arrest after a ventriculoscopy surgery in infants: Two case reports. *Masui* 1997;46:416-20.
34. Anandh B, Madhusudan Reddy KR, Mohanty A, Umamaheswara Rao GS, Chandramouli BA. Intraoperative bradycardia and postoperative hyperkalemia in patients undergoing endoscopic third ventriculostomy. *Minim Invasive Neurosurg* 2002;45:154-7.
35. Abtin K, Thompson BG, Walker ML. Basilar artery perforation as a complication of endoscopic third ventriculostomy. *Pediatr Neurosurg* 1998;28:35-41.
36. Horowitz M, Albright AL, Jungreis C, Levy EI, Stevenson K. Endovascular management of a basilar artery false aneurysm secondary to endoscopic third ventriculostomy: Case report. *Neurosurgery* 2001;49:1461-4.
37. McLaughlin MR, Wahlig JB, Kaufmann AM, Albright AL. Traumatic basilar aneurysm after endoscopic third ventriculostomy: Case report. *Neurosurgery* 1997;41:1400-3.
38. Schroeder HW, Warzok RW, Assaf JA, Gaab MR. Fatal subarachnoid hemorrhage after endoscopic third ventriculostomy. Case report. *J Neurosurg* 1999;90:153-5.
39. Schmidt RH. Use of a microvascular Doppler probe to avoid basilar artery injury during endoscopic third ventriculostomy. Technical note. *J Neurosurg* 1999;90:156-9.
40. Gangemi M, Donati P, Maiuri F, Longatti P, Godano U, Mascari C. Endoscopic third ventriculostomy for hydrocephalus. *Minim Invasive Neurosurg* 1999;42:128-32.
41. Yadav YR, Jaiswal S, Adam N, Basoor A, Jain G. Endoscopic third ventriculostomy in infants. *Neurol India* 2006;54:161-3.
42. Mayah KN. Endoscopic third ventriculostomy – Experience in Basrah. *Iraq Pan Arab J Neurosurg* 2009;13:43-8.
43. Idowu OE, Falope LO, Idowu AT. Outcome of endoscopic third ventriculostomy and Chhabra shunt system in noncommunicating non-tumor childhood hydrocephalus. *J Pediatr Neurosci* 2009;4:66-9.