

Posterior Cervical Interbody Fusion – Single-Stage Approach of Anterior Reconstruction and Posterior Stabilization: A Case Report and Review of Literature

Abstract

The success and popularity of the transforaminal approach in the lumbar spine have been made possible by the routine use of pedicle screws in the lumbar spine. Transforaminal approach in the cervical spine can give access to the disc and the vertebral body anteriorly and avoid an additional anterior approach in certain clinical situations. A case of cervical spine trauma was managed by this approach. Technical details and difficulties faced were analyzed in this article. Transforaminal approach in the lower cervical spine, though has a learning curve, seems to be a feasible technique along with the use of cervical pedicle screws. The safety and reproducibility of the approach need to be substantiated with a larger study. Further, this procedure can avoid additional anterior surgery in certain situations in the cervical spine.

Keywords: Cervical pedicle screws, medial cortical pedicle screws, transforaminal cervical interbody fusion

Introduction

Harms and Rolinger first introduced the transforaminal approach in the lumbar spine. Since then with the widespread use of pedicle screws, it has become one of the most popular approaches to access the disc and interbody region in the lumbar spine.^[1] Compared to the lumbar spine, cervical pedicle screws (CPSs) are less frequently used due to the fear of catastrophic damage to the surrounding neurovascular structures. Hence, transforaminal approach to the disc and cervical body is not commonly practiced.^[2-5] However, clinical studies have shown minimal screw-related complications and have highlighted the advantages of using CPS.^[6-8] The use of CPS in the lower cervical spine will facilitate the transforaminal approach analogous to that in the lumbar spine. Transforaminal approach can give access to the disc and the vertebral body anteriorly and avoid an additional anterior approach in certain clinical situations. Here, we will share our experience on the feasibility and safety of transforaminal approach in the lower cervical spine in a case of traumatic cervical spine injury.

This is an open access journal, and articles are distributed under the terms of the Creative Commons Attribution-NonCommercial-ShareAlike 4.0 License, which allows others to remix, tweak, and build upon the work non-commercially, as long as appropriate credit is given and the new creations are licensed under the identical terms.

For reprints contact: reprints@medknow.com

Case Report

A 35-year-old male patient presented to our tertiary care center following a road traffic accident with bi-facetral fracture dislocation, quadriplegia (nonfunctional power in bilateral upper and lower limbs) with the involvement of the bladder bowel [Figure 1]. Under general anesthesia in the prone position, midline posterior approach was taken. Pedicle screws were inserted at C6, 7. Reduction was achieved by distraction. Nerve roots were decompressed bilaterally. The vertebral artery was retracted anteriorly by indirect method [Figure 2]. Discectomy was carried out at C6–7 level followed by endplate preparation and cage insertion at the same level [Figures 3 and 4]. Following the procedure, patient was mobilized on the 3rd post-operative day with a Philadelphia brace. At present, patient is mobilized on wheelchair with functional power in upper limbs with a follow-up period of 2 years.

Discussion

Posterior foraminotomy has been previously carried out along with discectomy with

**Sandeep Sonone,
Aditya A. Dahapute,
Shubhanshu
Mahendra
Bhaladhare, Nandan
Amrit Marathe,
Sai Gautham
Balasubramanian,
Prakash Kieron
George**

Department of Orthopaedics,
Seth GS Medical College
and KEM Hospital, Mumbai,
Maharashtra, India

Address for correspondence:

Dr. Shubhanshu Mahendra
Bhaladhare,
Department of Orthopaedics,
6th Floor, New Building, KEM
Hospital, Parel, Mumbai,
Maharashtra, India.
E-mail: shubhanshu.
bhaladhare@gmail.com

Access this article online

Website: www.asianjns.org

DOI: 10.4103/ajns.AJNS_189_19

Quick Response Code:



How to cite this article: Sonone S, Dahapute AA, Bhaladhare SM, Marathe NA, Balasubramanian SG, George PK. Posterior cervical interbody fusion – Single-stage approach of anterior reconstruction and posterior stabilization: A case report and review of literature. Asian J Neurosurg 2020;15:222-4.

Submission: 23-06-2019 **Accepted:** 25-10-2019
Published: 25-02-2020

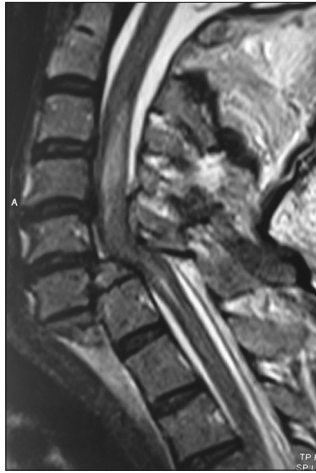

Figure 1: T2-weighted sagittal magnetic resonance imaging showing C6-7 dislocation with signal changes in cord

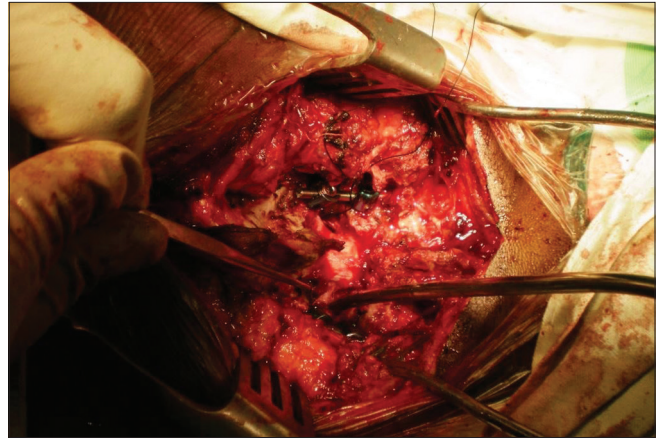


Figure 2: Intraoperative image after facetectomy showing probe in foraminal area retracting vertebral artery laterally

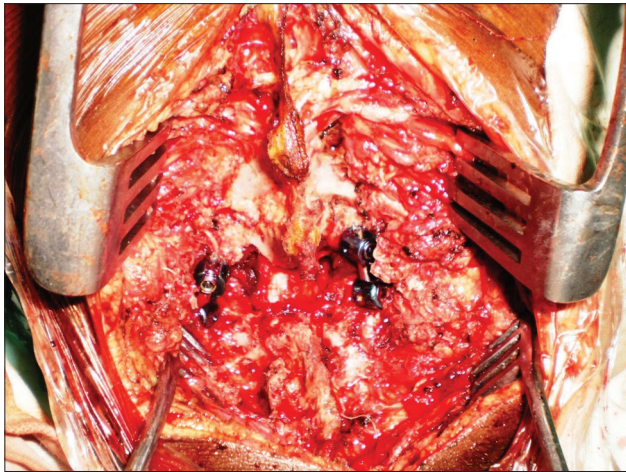


Figure 3: Intraoperative image showing the final fixation with cervical pedicle screw

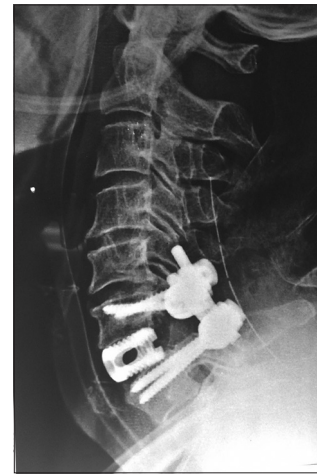

Figure 4: Postoperative lateral X-ray

good surgical outcomes. Removal of the lateral mass and lamina in this approach raised concerns of iatrogenic instability. However, now, we have an improvement in technique of safe placement of CPSs. This facilitates facet removal thus enlarging the zone of work. There is always a concern of iatrogenic injury to vital structures like the vertebral artery, as this approach entails a more lateral approach into the transforaminal area. This can be avoided by using the unciniate process as a landmark in the foraminal region.

Transforaminal approach in patients with lower cervical fracture dislocations with herniated disc has been previously reported in literature. Dunlap *et al.* reported on removal of the herniated disc fragment through foraminotomy in seven patients with cervical fracture dislocation and traumatic disc herniation along with the use of CPS in a single posterior approach.^[9] Nakashima *et al.* reported on 40 patients with cervical facet dislocations and disc herniation, who underwent posterior pedicle screw instrumentation and reduction.^[10] The authors in these two

series had planned for an anterior procedure in the event of increase in disc herniation during posterior reduction, but they did not require the anterior procedure in any of their patients.

The major obstacle in this approach is the relatively narrow safe zone available for entry into the inter-body region. Similar to the transforaminal approach in the lumbar spine, the safe zone is bound by the superior wall of the pedicle below, the existing root which is retracted cranially, the dura medially, the vertebral artery laterally, and the unciniate process making the floor. The authors used 1-2 mm curettes and 1 mm disc punches to get into the inter-body region. The transforaminal approach in the lower cervical spine can be as versatile as in the lumbar spine with the routine use of CPS.

The advantage of the trans-foraminal approach lies in the access gained to the anterior structures of the cervical spine from the posterior aspect. Further, the access to the disc and the vertebral body is from a more lateral zone and at a more-steep angle compared to the conventional posterior foraminotomy approach. This gives the surgeon

access to the lateral and central portions of the inter-body area without undue retraction of the cervical cord. This approach can avoid an additional anterior procedure as the goals of anterior decompression rigid 3-column stabilization (using CPS) and inter-body fusion can be achieved by a single posterior approach at least in clinical situations described above.

Lateral mass posterior instrumentation in the lower cervical spine is a time-tested familiar method of stabilization and sufficient in most of the situations requiring cervical stabilization. However, the authors believe that with the routine and safe use of CPS instrumentation the evolution of a versatile technique like the transforaminal decompressions and inter-body fusions is only a matter of time. The authors encourage the procedure to be evaluated by surgeons routinely performing CPS insertion in the lower cervical spine for its safety and feasibility.

Declaration of patient consent

The authors certify that they have obtained all appropriate patient consent forms. In the form the patient(s) has/have given his/her/their consent for his/her/their images and other clinical information to be reported in the journal. The patients understand that their names and initials will not be published and due efforts will be made to conceal their identity, but anonymity cannot be guaranteed.

Financial support and sponsorship

Nil.

Conflicts of interest

There are no conflicts of interest.

References

1. Harms J, Rolinger H. A one-stager procedure in operative treatment of spondylolistheses: Dorsal traction-reposition and anterior fusion (author's transl). *Z Orthop Ihre Grenzgeb* 1982;120:343-7.
2. Reinhold M, Bach C, Audigé L, Bale R, Attal R, Blauth M, *et al.* Comparison of two novel fluoroscopy-based stereotactic methods for cervical pedicle screw placement and review of the literature. *Eur Spine J* 2008;17:564-75.
3. Neo M, Sakamoto T, Fujibayashi S, Nakamura T. The clinical risk of vertebral artery injury from cervical pedicle screws inserted in degenerative vertebrae. *Spine (Phila Pa 1976)* 2005;30:2800-5.
4. Abumi K, Shono Y, Ito M, Taneichi H, Kotani Y, Kaneda K. Complications of pedicle screw fixation in reconstructive surgery of the cervical spine. *Spine (Phila Pa 1976)* 2000;25:962-9.
5. Uğur HC, Attar A, Uz A, Tekdemir I, Egemen N, Çağlar S, *et al.* Surgical anatomic evaluation of the cervical pedicle and adjacent neural structures. *Neurosurgery* 2000;47:1162-8.
6. Abumi K, Itoh H, Taneichi H, Kaneda K. Transpedicular screw fixation for traumatic lesions of the middle and lower cervical spine: Description of the techniques and preliminary report. *J Spinal Disord* 1994;7:19-28.
7. Abumi K, Kaneda K. Pedicle screw fixation for nontraumatic lesions of the cervical spine. *Spine (Phila Pa 1976)* 1997;22:1853-63.
8. Karaikovic EE, Kunakornsawat S, Daubs MD, Madsen TW, Gaines RW Jr. Surgical anatomy of the cervical pedicles: Landmarks for posterior cervical pedicle entrance localization. *J Spinal Disord* 2000;13:63-72.
9. Dunlap BJ, Karaikovic EE, Park HS, Sokolowski MJ, Zhang LQ. Load sharing properties of cervical pedicle screw-rod constructs versus lateral mass screw-rod constructs. *Eur Spine J* 2010;19:803-8.
10. Nakashima H, Yukawa Y, Imagama S, Kanemura T, Kamiya M, Yanase M, *et al.* Complications of cervical pedicle screw fixation for nontraumatic lesions: A multicenter study of 84 patients. *J Neurosurg Spine* 2012;16:238-47.