

Spontaneous Resolution of Postoperative Giant Frontal Pseudomeningocele

Abstract

Cranial pseudomeningoceles are abnormal extradural collections of cerebrospinal fluid. Postoperative giant cranial pseudomeningoceles have been rarely reported in the literature and have no specific treatment guidelines. The optimal management strategy for this condition differs among authors, varying from conservative approach to surgical intervention. A spontaneous resolution of postoperative giant frontal pseudomeningocele is reported. A 41-year-old female presented a pseudomeningocele 3 weeks after a right frontal meningioma surgical resection. The pseudomeningocele progressed during the first 1.5-month postoperatively despite percutaneous aspiration and compressive bandage, it then shrank spontaneously and was completely resolved at the 15th month since the surgery. Nonoperative treatment with a close follow-up could be a good option for asymptomatic giant pseudomeningoceles, resulting in a spontaneous resolution.

Keywords: *Conservative treatment, craniotomy, giant, pseudomeningocele, resolution*

Introduction

Postoperative pseudomeningoceles are characterized by the extradural accumulation of cerebrospinal fluid (CSF) leaked from a surgical wound into the subcutaneous space.^[1,2] The incidence may exceed 40%.^[2-6] Besides inducing anxiety to patients and their families, these lesions may cause cosmetic deformity, wound dehiscence, CSF leak, intracranial hypotension, aseptic meningitis, and even death.^[7,8] Hydrocephalus, poor surgical closure of the dura, and subarachnoid scarring have all been implicated as potential contributing factors.^[2]

At present, there are no standardized guidelines for the management of this condition. Most pseudomeningoceles resolve spontaneously while some progress until a wound breakdown occurs.^[9] Factors that may predict the progression include ongoing hydrocephalus or infection, although these are inconsistently reported.^[9] Many authors advocate conservative managements including observation, bed rest with proper positions, pressure bandage, needle aspiration, and lumbar CSF drainage; a dural repair should be considered for those who do not respond to conservative management.^[2,9,10]

This is an open access journal, and articles are distributed under the terms of the Creative Commons Attribution-NonCommercial-ShareAlike 4.0 License, which allows others to remix, tweak, and build upon the work non-commercially, as long as appropriate credit is given and the new creations are licensed under the identical terms.

For reprints contact: WKHLRPMedknow_reprints@wolterskluwer.com

Here, we present a 41-year-old female with a pseudomeningocele that appeared 3 weeks after a right frontal meningioma surgical resection. Despite unsuccessful conservative management at the beginning, the pseudomeningocele shrank spontaneously and was completely resolved at the 15th month since the surgery. We would also discuss its clinical features and delineating management options for this postoperative complication.

Case Report

A 41-year-old female presented with a secondarily generalized seizure. Brain magnetic resonance imaging (MRI) revealed a right frontal meningioma. She underwent an uneventful total tumor resection and was discharged on the 7th day after surgery. The patient revisited the outpatient clinic at the postoperative 3rd week because of expanding subcutaneous fluid accumulation at the surgical site. She was otherwise normal. Percutaneous aspiration and compression bandage were performed every 2 days for 3 times but were unsuccessful. The fluid accumulation was still 3 cm × 5 cm; then, it reached its largest size of 6 cm × 10 cm on the 45th day since the operation [Figure 1]. She obtained a MRI showing a frontal pseudomeningocele

How to cite this article: Tran DD, Dinh TP, Nguyen QB, Mai DT, Truong VT. Spontaneous resolution of postoperative giant frontal pseudomeningocele. *Asian J Neurosurg* 2021;16:372-5.

Submitted: 15-Jan-2021

Accepted: 01-Mar-2021 **Published:** 28-May-2021

**Duc Duy Tri Tran^{1,2,*},
Thi Phuong Hoai
Dinh^{1,*},
Quoc Bao Nguyen¹,
Dang Thi Mai¹,
Van Tri Truong^{1,3}**

¹Department of Neurosurgery, Hue University Hospital, Hue University of Medicine and Pharmacy, Hue University, Hue, Vietnam, ²Department of Neurosurgery, Xuyen A Hospital, Ho Chi Minh City, Vietnam,

³Division of Orthopedics, Central Hospital of University of Montreal, University of Montreal, Montreal, Canada

*: Authors equally contributed the work

Address for correspondence:

Dr. Van Tri Truong,
Department of Neurosurgery,
Hue University Hospital, Hue
University of Medicine and
Pharmacy, Hue University, Hue,
Vietnam.

Division of Orthopedics,
Central Hospital of University
of Montreal, University of
Montreal, Montreal, Canada.
E-mail: drtruongtri@gmail.com

Access this article online

Website: www.asianjns.org

DOI: 10.4103/ajns.AJNS_18_21

Quick Response Code:



and no hydrocephalus [Figure 2]. Despite the cosmetic deformity, the patient refused a surgery to remove the pseudomeningocele. Surprisingly, the fluid collection began to shrink remarkably from the 9th month postoperation then was completely resolved at the 15th month since the surgery [Figure 1].

The latest MRI taken in the postoperative 2nd year showed no recurrence of the tumor as well as the pseudomeningocele [Figure 2].

Discussion

Postoperative pseudomeningocele was first reported by Hyndman and Gerber in 1946 in a survey of extradural cysts and has several other names in the literature such as: “meningocele spurious,” “pseudocyst,” or “false cyst.”^[11] Miller classified pseudomeningoceles into: Congenital, iatrogenic, and traumatic.^[12] Most congenital pseudomeningoceles are usually associated with neurofibromatosis and Marfan syndrome.^[13] Giant pseudomeningocele is a pathology where lesion size is above 8 cm in diameter.^[13] Postoperative giant pseudomeningocele is a very rare entity. Several postoperative giant spinal pseudomeningoceles have been published in the literature.^[13,14] However, there has been no postoperative giant cranial pseudomeningocele reported. Some theories have been proposed to explain the pathophysiology of these lesions, but none of them have been clearly proven. An incomplete dura closure after surgery may allow the arachnoid membrane to protrude through the defect, forming an arachnoid-lined

pseudomeningocele.^[1] Some other authors have suggested that large volumes of CSF accumulate in the postoperative cavity through the dural defect in a ball-valve fashion and become trapped.^[15,16]

Typically, most pseudomeningoceles persist for days or weeks then promptly disappear within 1 or 2 days, indicating that the abnormal accumulation of CSF is temporary and could be reabsorbed completely.^[10] However, infection, radiation, malnutrition, and increased CSF pressure may result in persistent pseudomeningoceles.^[1] As there is no consensus in treatment strategy, pseudomeningocele, especially giant one may be managed differently among clinicians. The overall average opinion ascertained from an international survey of Tu *et al.* suggested that postoperative pseudomeningocele, without hydrocephalus, should be monitored for 7–14 days before re-exploration.^[10] In case of hydrocephalus, 48% of neurosurgeons initially intervene with CSF diversion and would change the method if the lesion does not decrease within 2–4 days.^[10] This survey concluded that initial follow-up was appropriate for cranial pseudomeningoceles. In case of failure with conservative management including pressure bandages, percutaneous fluid aspiration, bed rest, and CSF lumbar drainage, surgical intervention is recommended.^[10,17,18] In case of postoperative ventriculomegaly, CSF shunting may be required if lumbar drainage has been failed.^[7] For example, a report at British Columbia’s Children’s Hospital in Vancouver, Canada showed 73.5% of cranial pseudomeningoceles after posterior fossa surgery were

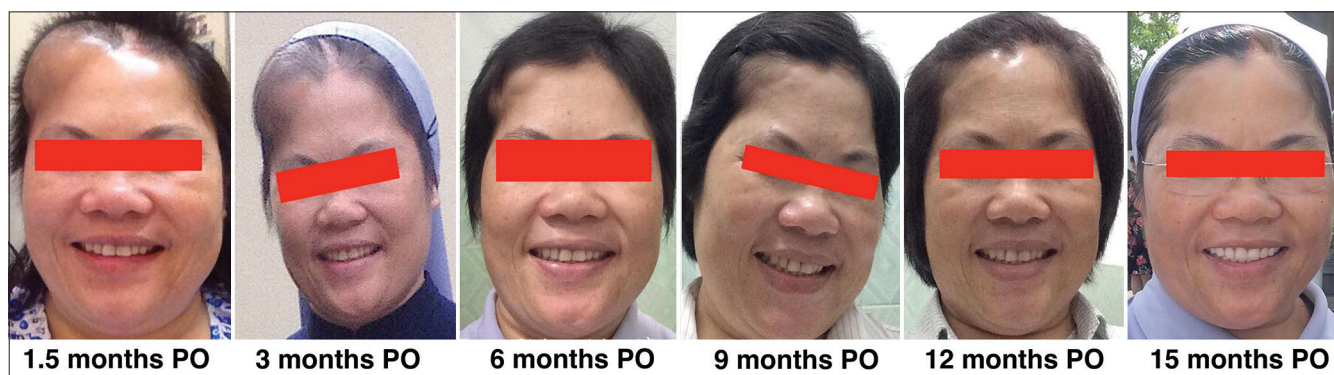

Figure 1: Evolution of postoperative frontal pseudomeningocele (PO: postoperative)

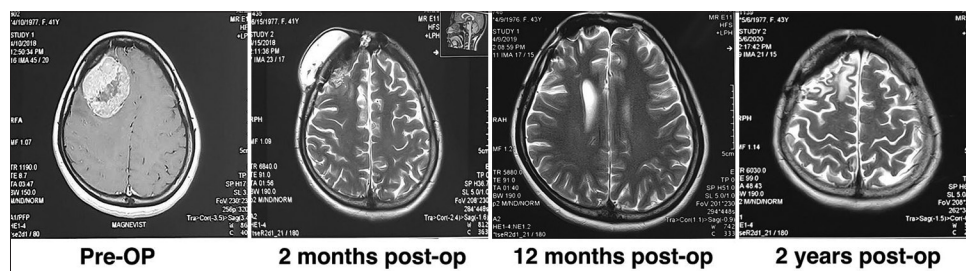


Figure 2: Magnetic resonance imaging demonstrated the spontaneous resolution of the pseudomeningocele after frontal meningioma resection Pre-OP: preoperative; post-op: postoperative

treated conservatively and half of them improved with temporary CSF diversion (i.e., lumbar drainage or endoscopic third ventriculostomy).^[4] This study supports the notion that the majority of these lesions should be treated conservatively. Birkholz *et al.* reported 4 spinal pseudomeningocele cases that recurred after dural repair but eventually resolved by undergoing temporary epidural drainage.^[19] These case reports demonstrated conservative therapy (e.g., epidural drainage) should be tried before considering any surgical procedure. There has been little evidence to determine when pseudomeningoceles will be resolved; however, we agree with the idea that if patient is suffering from pain, unable to lie comfortably, or having frustration while the lesion remains or progresses, it need to be re-examined sooner.^[10] Tu *et al.* suggested that the increasing size of the pseudomeningocele was a sign of conservative treatment failure and surgery should be indicated regardless of timing.^[10] However, our case showed that this lesion could resolve spontaneously despite its initial progression. Previous studies described hydrocephalus might be a risk factor of postoperative pseudomeningocele. The increasing pressure resulting from obstruction of CSF pathways could lead to an outflow through the recent dural defect, leading to extradural fluid accumulation.^[9,10,20] The present patient had no hydrocephalus after brain surgery but her pseudomeningocele increased progressively despite percutaneous aspiration and compressive bandage. Re-exploration may be indicated after this failure of conservative treatment, but the patient preferred to continue the close observation. It shrank remarkably from the 9th month postoperation then was completely resolved at the 15th month since the surgery. The exact mechanism of spontaneous resolution of pseudomeningocele has not been clear, but it is hypothesized that healing of the dural defect with gradual resorption of the intra-capsular CSF result in resolution of these pseudomeningoceles.^[21] There have been case reports about spontaneous resolution of a massive spinal pseudomeningocele,^[21,22] but to the best of our knowledge, the present case is the first postoperative giant cranial pseudomeningocele which resolve spontaneously despite of initial failure conservative treatment reported. In our opinion, nonoperative management with close observation could be a good option of treatment for asymptomatic giant pseudomeningoceles, even if they increase progressively at the beginning.

Conclusion

While there is very little evidence in the literature to support the timing of surgery for cranial pseudomeningocele after craniotomy, nonoperative treatment and close follow-up could be a good option for asymptomatic giant pseudomeningoceles, resulting in spontaneous resolution.

Declaration of patient consent

The authors certify that they have obtained all appropriate patient consent forms. In the form the patient(s) has/have given his/her/their consent for his/her/their images and other clinical information to be reported in the journal. The patients understand that their names and initials will not be published and due efforts will be made to conceal their identity, but anonymity cannot be guaranteed.

Financial support and sponsorship

Nil.

Conflicts of interest

There are no conflicts of interest.

References

- Couture D, Branch CL Jr. Spinal pseudomeningoceles and cerebrospinal fluid fistulas. *Neurosurg Focus* 2003;15:E6.
- Mehendale NH, Samy RN, Roland PS. Management of pseudomeningocele following neurologic procedures. *Otolaryngol Head Neck Surg* 2004;131:253-62.
- Zide BM. How to reduce the morbidity of wound closure following extensive and complicated laminectomy and tethered cord surgery. *Pediatr Neurosurg* 1992;18:157-66.
- Steinbok P, Singhal A, Mills J, Cochrane DD, Price AV. Cerebrospinal fluid (CSF) leak and pseudomeningocele formation after posterior fossa tumor resection in children: A retrospective analysis. *Childs Nerv Syst* 2007;23:171-4.
- Hawk MW, Kim KD. Review of spinal pseudomeningoceles and cerebrospinal fluid fistulas. *Neurosurg Focus* 2000;9:e5.
- Manley GT, Dillon W. Acute posterior fossa syndrome following lumbar drainage for treatment of suboccipital pseudomeningocele. Report of three cases. *J Neurosurg* 2000;92:469-74.
- Smith GA, Strohl MP, Manjila S, Miller JP. Incidence, management, and outcome of symptomatic postoperative posterior fossa pseudomeningocele: A retrospective single-institution experience. *Oper Neurosurg (Hagerstown)* 2016;12:298-304.
- Chiang JY, Lin HL. Life-threatening posterior fossa cyst induced by pseudomeningocele after operation for acoustic neuroma. *Surg Neurol Int* 2015;6 Suppl 2:S101-3.
- Pirouzmand F, Tator CH, Rutka J. Management of hydrocephalus associated with vestibular schwannoma and other cerebellopontine angle tumors. *Neurosurgery* 2001;48:1246-53.
- Tu A, Tamburrini G, Steinbok P. Management of postoperative pseudomeningoceles: An international survey study. *Childs Nerv Syst* 2014;30:1791-801.
- hyndman OR, GERBER WF. Spinal extradural cysts, congenital and acquired; report of cases. *J Neurosurg* 1946;3:474-86.
- Miller PR, Elder FW Jr. Meningeal pseudocysts (meningocele spurium) following laminectomy. Report of ten cases. *J Bone Joint Surg Am* 1968;50:268-76.
- Weng YJ, Cheng CC, Li YY, Huang TJ, Hsu RW. Management of giant pseudomeningoceles after spinal surgery. *BMC Musculoskelet Disord* 2010;11:53.
- Srilomsak P, Okuno K, Sakakibara T, Wang Z, Kasai Y. Giant pseudomeningocele after spinal surgery: A case report. *World J Orthop* 2012;3:109-13.
- Cobb C 3rd, Ehni G. Herniation of the spinal cord into an iatrogenic meningocele. Case report. *J Neurosurg* 1973;39:533-6.
- Tsuji H, Handa N, Handa O, Tajima G, Mori K. Postlaminectomy

- ossified extradural pseudocyst. Case report. *J Neurosurg* 1990;73:785-7.
17. Aoki N. Lumboperitoneal shunt for the treatment of postoperative persistent collection of subcutaneous cerebrospinal fluid (pseudomeningocele). *Acta Neurochir (Wien)* 1989;98:32-4.
 18. Waisman M, Schweppe Y. Postoperative cerebrospinal fluid leakage after lumbar spine operations. Conservative treatment. *Spine (Phila Pa 1976)* 1991;16:52-3.
 19. Birkholz SE, Patil AA, Chamczuk AJ, Treatment of postoperative recurrent cerebrospinal fluid leak with pseudo-meningocele formation using temporary epidural drain. *Interdiscip Neurosurg* 2019;16:25-8.
 20. Pahys JM, Chicorelli AM, Asghar J, Betz RR, Samdani AF. Cervical pseudomeningocele due to occult hydrocephalus. *Spine (Phila Pa 1976)* 2008;33:E394-6.
 21. Solomon P, Sekharappa V, Krishnan V, David KS. Spontaneous resolution of postoperative lumbar pseudomeningoceles: A report of four cases. *Indian J Orthop* 2013;47:417-21.
 22. Clarke A, Hutton M. Spontaneous resolution of a massive pseudomeningocele. *Acta Orthop Belg* 2009;75:277-9.