

The Correlation between Histopathology of Herniated Lumbar Intervertebral Disc and Clinical Findings

Abstract

Objective: Prolapsed lumbar disc is one of the most frequent diseases, which is usually presented by motor and sensory deficits. Consistency of herniated disc may play a significant role in surgical treatment and postoperative improvement. The objective of this study is to assess whether the histopathological degeneration in the sample of lumbar discs operated on is correlated to clinical variables and surgical outcomes. **Materials and Methods:** A randomized double-blind prospective study of lumbar disc prolapse cases over a period of 24 months was done. Forty cases were initially included in the study. All the included cases with a scheduled lumbar discectomy in the Department of Neurosurgery, King Fahd University Hospital, Al-Khobar, Saudi Arabia, during this period were examined histologically. **Results:** Finally, 21 patients were only considered in this study due to loss of follow-up of the other 19 patients; of these 21 patients, 18 were male and 3 were female. The youngest patient was 32 years old, and the oldest was 72 years old. There is no significant correlation between the major histopathological changes of the prolapsed discs and the clinical findings of low back pain (correlation coefficient = 0.058, $P < 0.8$), duration of sciatica (correlation coefficient = -0.337 , $P < 0.1$), paresthesia (correlation coefficient = 0.111, $P < 0.6$), motor weakness (correlation coefficient = 0.274, $P < 0.2$), and reflex (correlation coefficient = 0.081, $P < 0.7$). Meanwhile, the correlation coefficient between numbness and histopathological degeneration score (HPDS) is not defined because all reported cases were presented with numbness. **Conclusions:** There is no significant correlation between the histopathological changes of the prolapsed discs and some clinical findings. Moreover, the different types of prolapsed discs' histopathological changes have no impact on the outcome of the surgery. We also concluded that the disc material undergoes certain degenerative processes with age.

Keywords: *Herniated lumbar disc, histopathology, low back pain, microdiscectomy, sciatica*

Introduction

Low back pain (LBP) is one of the most common chronic problems, affecting millions of people at different stages of their lives.^[1,2] One of the possible causes of this condition is the intervertebral disc (IVD) degeneration.^[3,4] Nevertheless, the clinical picture of different degrees of IVD degeneration is highly variable, from one person to another.^[4] Patients may suffer from a severe radicular symptom in their legs with only tolerable, minimal, or even no LBP.^[4,5] Moreover, the association between IVD degeneration and the clinical manifestation of the patients is not fully understood yet.^[1,6] Except for the diffusion delay noticed across the IVD endplates, pathological disc degeneration is similar to the aging effect on the IVD.^[7] The most common cause of radicular/sciatic pain is

the lumbar disc herniation.^[8] The lifetime prevalence of this condition is about 10%, with a variable prevalence ranging from 1.6% to 43%.^[9-11] This type of pain characterized by downward radiation through the lower limbs, which is considered one of the main causes of occupational disability.^[12] In general, the radiological and histopathological characteristics of IVD herniation and degeneration have been studied well; however, the proper correlation to the patient's symptoms is not established yet.^[11,13,14] It is common in clinical practice to find a case with IVD degeneration/herniation with minimal or no symptoms.^[15-17] Moreover, the herniated disc may exhibit different consistency, including calcification, which might be associated with complicated surgical intervention and postoperative complications.^[18]

This is an open access journal, and articles are distributed under the terms of the Creative Commons Attribution-NonCommercial-ShareAlike 4.0 License, which allows others to remix, tweak, and build upon the work non-commercially, as long as appropriate credit is given and the new creations are licensed under the identical terms.

For reprints contact: WKHLRPMedknow_reprints@wolterskluwer.com

How to cite this article: Ammar A, Alwadei A, Al Hayek A, Alabbas FM, Almatrafi FR, Elshawarby M. The correlation between histopathology of herniated lumbar intervertebral disc and clinical findings. *Asian J Neurosurg* 2020;15:545-53.

Submitted: 02-May-2020

Revised: 26-Jun-2020

Accepted: 11-Jun-2020

Published: 28-Aug-2020

**Ahmed Ammar,
Ali Alwadei,
Ali Al Hayek,
Faisal M. Alabbas,
Faisal Rashed
Almatrafi,
Mohammed
Elshawarby¹**

*Departments of Neurosurgery
and ¹Pathology, King Fahd
University Hospital, Imam
Abdulrahman Bin Faisal
University, Dammam,
Saudi Arabia*

Address for correspondence:

*Dr. Ahmed Ammar,
Departments of Neurosurgery,
King Fahd University Hospital,
Imam Abdulrahman Bin Faisal
University, Dammam, Saudi
Arabia.
E-mail: ahmed@ahmedammar.
com*

Access this article online

Website: www.asianjns.org

DOI: 10.4103/ajns.AJNS_193_20

Quick Response Code:



In 2002, Boos *et al.*^[13] classified the histopathological changes in the degenerating IVDs, following analysis of cadaveric lumbar specimens, with a wide range of ages ranging from fetal to 88 years. Their study found that rim lesions and edge neovascularization, chondrocyte proliferation, tears or cleft formation, mucoid degeneration, and granular changes; are the most common changes in the degenerate IVDs.^[13] As a result, they proposed a detailed scale for grading the histological changes in the degenerated lumbar IVDs.^[13] In 2011, Weiler *et al.*^[19] have simplified this scale and validated it using specimens of surgically treated patients with disc herniation. We based our assessment on the final retained parameters of the modified scale, which were; cell proliferation, cracks and tears, and granular changes. We presumed that the consistency of herniated lumbar disc has an impact on clinical features and postoperative improvement. The objective of this study is to assess whether the degree of histological degeneration in the sample of lumbar discs operated on is related to clinical variables as well as the impact on surgical outcomes.

Materials and Methods

Study population and data collection

Period of the study: 24 months.

Inclusion criteria

All the cases that had been diagnosed with disc prolapse and confirmed clinically and radiologically and scheduled for lumbar discectomy in the department of neurosurgery during the determined period.

Exclusion criteria

Excluded cases are: Lumbar spine trauma, spondylolisthesis, recurrent disc prolapse, failed back surgery syndrome, and infection. Moreover, cases not operated by the principal investigator, and cases that are unable to be correctly traced to their histopathology specimen, were also excluded.

A randomized double-blind prospective study of lumbar disc prolapse cases initially included 40 cases in the study. All the included cases with a scheduled lumbar discectomy in the Department of Neurosurgery, King Fahd University Hospital, Al-Khobar, Saudi Arabia, during this period were examined histologically and subsequently correlated to clinical presentation and surgical outcome.

The data from the included cases had been obscured and labeled in two different sets of groups: A clinical group and a histopathology group. For all variables, a 0–3 scale was used with 0 = absent, + = mild, 2+ = moderate, and 3+ = marked.^[13,18]

The clinical investigating team collected data for the clinical group and arranged the data into tables according to particular variables. This team had no access to the histopathology results. The variables used in classification are the various motor (weakness and reflex response) and

sensory deficits (LBP, sciatica, paresthesia, and numbness) with recording the duration of any positive sign/symptom. The outcome of surgery has been evaluated for all patients with regular follow-up.

Follow up protocol

All patients were discharged postoperatively between the 5th and the 7th day. Patients were thoroughly examined before discharge (immediate). The patients were scheduled for outpatient clinics appointment at 1 month, 6 months, and 1 year. They were clinically examined during their follow-up and followed with radiological imaging.

The histopathology team collected and arranged the data into tables according to particular variables, for the histopathology group.

Similarly, this team had no access to the clinical data, operative notes, or radiological data.

Tissue preparation

Regarding the method used in the histopathological evaluation of the samples, four micron-thick hematoxylin and eosin stained sections, prepared from formalin-fixed paraffin-embedded disc material and resected from 21 herniated disc patients and eight cadaveric normal controls. The anatomist who removed these cadaveric discs claimed the cadaveric discs looked healthy at the time of death, and no sign of herniation or tear of the annulus fibrosis was noticed, after careful examination.

Data evaluation

At the end of the research period, two teams got together, and the patients' identities were revealed. Moreover, the correlation between the clinical findings and the histopathological findings were studied. The histopathological data were semi-quantitatively evaluated for any morphological changes including, cracks/fissures, vascularization/granulation tissue, scar tissue, calcification, cartilage cell proliferation (cell clusters), and degenerated fibrocartilaginous stroma.

Statistical analysis

Three types of correlations were used according to the type of variables. For measuring the correlation between two continuous variables, the Pearson correlation was used. The Spearman's rank correlation was used for measuring the correlation between ordinal and continuous variables, whereas the Point-Biserial correlation was used for measuring the correlation between nominal and continuous variables. The continuous variables in the study (Age and HPDS) were checked for normality using the Shapiro–Wilk test. All statistical analyses were performed in SPSS (Statistical Package for Social Sciences, version 25, SPSS Inc, Saudi Arabia).

Results

Of 40 patients, 21 patients were included in the study. Nineteen patients were excluded due to lost follow-up. Of these 21 patients, 18 were male and 3 were female. Patients' ages ranged from 32 to 72 years (mean = 51 years). In addition to that characteristics, the most common site of disc herniation was the level of L5–S1 (8 cases), followed by L4–L5 (7 cases) [Table 1]. The histopathological findings of the included patients were compared with a control group [Table 2] and were as follows: the most common changes noted were cracks/fissures [Figure 1a], and degenerated fibrocartilaginous stroma [Figure 1b]; they were seen in all study cases (100%) and 7/8 of the controls (87.5%). The third most common change was cartilage cell proliferation [Figure 1c], seen in 76.2% of the study cases compared to only 37.5% of the controls, thereby creating a significant difference between them. The proliferation was indicated as variable numbers of cartilage cell clusters. Scar tissue [Figure 1d], and vascularization/granulation tissue [Figure 1e], were noted in 23.8% of the study cases but were not noted in the controls. Finally, calcification [Figure 1f] was present in 19% of the study cases and 25% of the controls.

The correlation between the baseline characteristics of the patients and the histopathological findings

The mean of the histopathological degeneration score (HDPS) of all cases was 4.38 (standard deviation, 1.7). There was no significant difference in HDPS between males and females ($P < 0.7$). There was a significant correlation

between the age of the patients and HPDS (correlation coefficient = 0.496, $P < 0.02$) [Figure 2]. Moreover, when the patients' ages were classified into groups [Table 3], there was also a significant correlation between the age groups and HPDS (correlation coefficient = 0.535, $P < 0.01$). There was no significant correlation between the disc level and HPDS (correlation coefficient = 0.308, $P < 0.17$).

The clinical findings of the patients

Most cases suffered from LBP and sciatica for 2–6 months, followed by 1 week to 1-month duration. Numbness was reported in all cases, paresthesia was reported in 17 cases, motor weakness was reported in 11 cases, and absent of reflexes in 6 cases [Table 4]. Cracks/fissures, and degenerated fibrocartilaginous stroma were found in all cases with different grades scaled as absent, mild, moderate, and marked.

The correlation between the clinical and histopathological findings

Regarding the correlation between HPDS and the clinical findings, there was no significant correlation between any of them. The correlation coefficient between HPDS and each of the clinical findings was as follows: The duration of LBP [Table 5] (correlation coefficient = 0.058, $P < 0.8$), duration of sciatica [Table 6] (correlation coefficient = -0.337 , $P < 0.1$), paraesthesia [Table 7] (correlation coefficient = 0.111, $P < 0.6$), motor weakness [Table 8] (correlation coefficient = 0.274, $P < 0.2$), and reflex [Table 9] (correlation coefficient = 0.081, $P < 0.7$). Meanwhile, the correlation coefficient between numbness and HPDS is not defined because all reported cases were presented with numbness [Table 10].

Table 1: The baseline characteristics of the included patients

Patient ID	Gender	Age (years)	Disc level
1	Male	33	L4–L5
2	Male	40	L5–S1
3	Male	39	L4–L5 and L5–S1
4	Male	36	L4–L5
5	Female	32	L5–S1
6	Male	39	L5–S1
7	Female	37	L5–S1
8	Male	48	L4–L5
9	Male	45	L4–L5
10	Male	49	L4–L5
11	Male	57	L5–S1
12	Male	54	L5–S1
13	Male	53	L1–L2
14	Male	62	L4–L5
15	Female	60	L4–L5
16	Male	60	L5–S1
17	Male	55	L3–L4
18	Male	62	L3–L4 and L4–L5
19	Male	60	L3–L4 and L4–L5
20	Male	68	L5–S1
21	Male	72	L2–L3

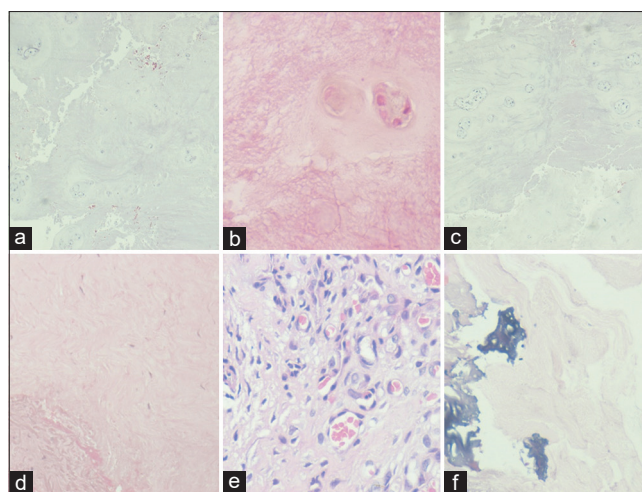


Figure 1: (a) Cracks/fissures in disc material. Note also cartilage cell clusters (H and E, $\times 100$); (b) degenerated fibrocartilaginous stroma (pale and fibrillated) (H and E, $\times 200$); (c) cartilage cell clusters. Note also focal scarring and cracks (H and E, $\times 50$); (d) Scarring (H and E, $\times 100$); (e) Vascularization (H and E, $\times 200$) (f) Calcification (Note also cracks and degeneration of fibrocartilaginous stroma) (H and E, $\times 100$)

Table 2: Histopathological findings in the study and control groups

Variable	Group	
	Study Group, n (%)	Control Group, n (%)
Cracks/fissures		
Absent	0 (0.0)	1 (12.5)
Mild	9 (42.9)	7 (87.5)
Moderate	6 (28.6)	0 (0.0)
Marked	6 (28.6)	0 (0.0)
Total positive findings	21 (100.0)	7 (87.5)
Vascularization (granulation tissue)		
Absent	16 (76.2)	8 (100.0)
Mild	3 (14.3)	0 (0.0)
Moderate	2 (9.5)	0 (0.0)
Total positive findings	5 (23.8)	0 (0.0)
Scar tissue		
Absent	16 (76.2)	8 (100.0)
Mild	5 (23.8)	0 (0.0)
Total positive findings	5 (23.8)	0 (0.0)
Calcification		
Absent	17 (81.0)	6 (75.0)
Mild	4 (19.0)	2 (25.0)
Total positive findings	4 (19.0)	2 (25.0)
Cartilage cell proliferation (cell clusters)		
Absent	5 (23.8)	5 (62.5)
Mild	5 (23.8)	1 (12.5)
Moderate	6 (28.6)	1 (12.5)
Marked	5 (23.8)	1 (12.5)
Total positive findings	16 (76.2)	3 (37.5)
Degenerated fibrocartilaginous stroma		
Absent	0 (0)	1 (12.5)
Mild	21 (100)	7 (87.5)
Total positive findings	100 (100)	7 (87.5)

Postoperative outcome

The postoperative prognosis of the patients varied from excellent to poor prognosis, measured immediately, at 1 month, 6 months, and 1 year. There was no significant correlation between HPDS and postoperative prognosis. The correlation coefficient and the *P* value between HPDS and postoperative prognoses immediately, at 1 month, at 6 months, and at 1 year, respectively, were as follows: (Correlation coefficient, *P* value) -0.063, 0.79; -0.102, 0.69; 0.156, 0.54; 0.74, 0.77; respectively. Figure 3 demonstrates the percentage of the total count of the prognoses postoperatively. Most of the patients (*n* = 17) had excellent immediate prognosis, where only 2 had very good, 1 had good, and 1 had poor prognoses. However, the prognosis shifted to be mostly very good at both 1-month (*n* = 15) and 6-month (*n* = 13) intervals. On assessing the patients after 1 year, 3 of them found to have a poor prognosis. There was no significant correlation between outcome of surgery and HPDS (coefficient correlation = -0.08 and *P* = 0.744).

Table 3: The correlation between age and the histopathological findings of the prolapsed disc

Age (years)	n	Cracks	Cartilage cell proliferation (cell clusters)	Degenerated fibrocartilaginous stroma
30-35	2	+	+	+
		+	-	+
36-40	5	3+	2+	+
		+	2+	+
		+	2+	+
		+	+	+
		3+	2+	+
41-45	1	+	-	+
46-50	2	2+	-	+
		2+	-	-
51-55	3	2+	+	+
		+	-	+
		3+	+	+
56-60	4	+	2+	+
		2+	3+	+
		3+	3+	+
		+	+	+
61-65	2	2+	2+	+
		3+	2+	+
66-70	1	3+	3+	+
71-75	1	2+	3+	+

Table 4. -- Absent; + - Mild; 2+ - Moderate; 3+ - Marked

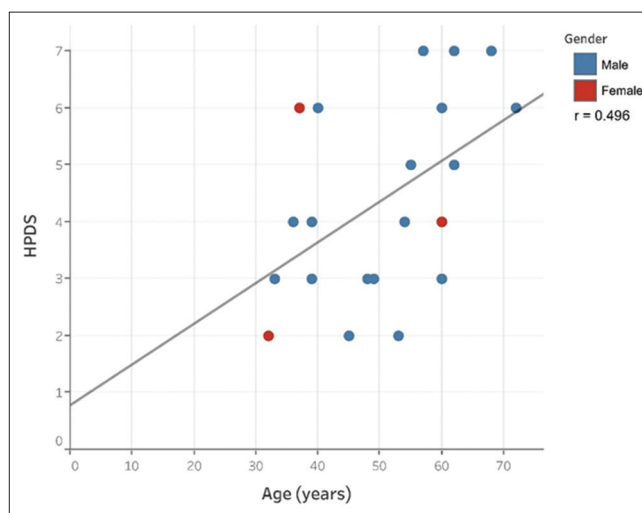


Figure 2: The correlation between the patients' age and HPDS

In summary, the only significant correlation coefficient noticed was between HPDS and both the patients' age and age groups. In contrast, there was no correlation between any of the clinical findings and HPDS, as was the correlation between postoperative prognosis and HPDS.

Table 4: Clinical findings of the sample

Patient ID	Sensory manifestations				Motor manifestations	
	LBP	Sciatica	Sensory deficit	Numbness	Weakness	Reflex
1	2-4 months	2-4 months	+	+	+	Reduced
2	2 weeks - 1 month	1 week - 1 month	+	+	-	Absent
3	2 weeks - 1 month	1 week - 1 month	+	+	+	Normal
4	2-4 months	2-4 months	+	+	-	Absent
5	4-6 years	4-6 years	+	+	-	Normal
6	5 months - 1 year	5 months - 1 year	+	+	-	Absent
7	4-6 years	2-4 months	+	+	+	Reduced
8	13-15 years	2-3 years	-	+	-	Normal
9	2-4 months	2-4 months	+	+	-	Reduced
10	5 months - 1 year	>30 years	+	+	+	Reduced
11	2-3 years	2-3 years	+	+	-	Absent
12	2-3 years	5 months - 1 years	-	+	-	Normal
13	13-15 years	13-15 years	+	+	+	Absent
14	2-4 months	2-4 months	+	+	+	Absent
15	2-4 months	2-4 months	-	+	+	Reduced
16	>30 years	5 months - 1 year	+	+	+	Reduced
17	13-15 years	7-9 years	+	+	+	Normal
18	2-3 years	2-4 months	-	+	-	Normal
19	2-4 months	1 week - 1 month	+	+	-	Normal
20	4-6 years	1 week - 1 month	+	+	+	Normal
21	2-3 years	2-4 months	+	+	+	Normal

Table 1. -- Absent; + – Present; LBP – Low back pain

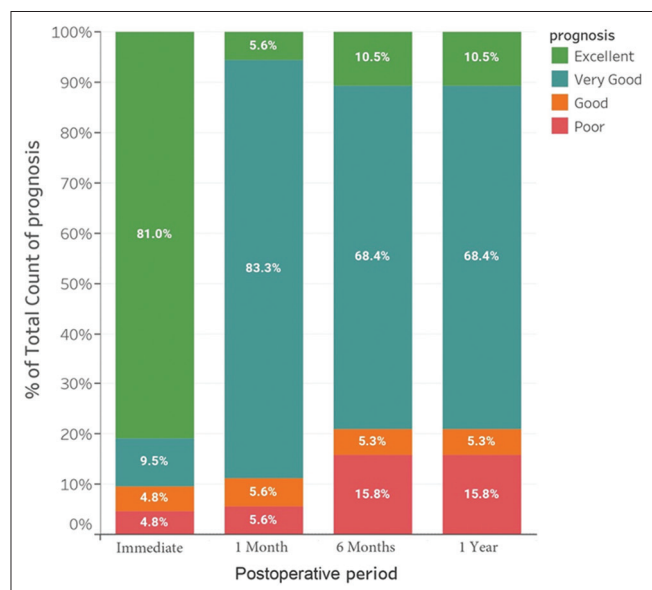


Figure 3: The percentage of the total count of prognosis postoperatively

The weak correlation between HPDS and the clinical findings may be due to the small sample size of the study. There is a need for more studies with large sample sizes for better estimation of the correlation.

Discussion

The normal IVD is anatomically located between vertebral bodies and separated from them by a thin “cartilaginous endplate.”^[20] The disc is histologically consisting of nucleus

pulposus (inner soft, hydrated structure) and annulus fibrosus (outer collagenous structure).^[21-23] It has very low cellularity (0.25%–0.5%) composed of chondrocyte-like cells in the nucleus and inner annulus (many appearing necrotic) and spindly (like tendon cells) in the outer annulus.^[21-23] It was reported that the disc materials go through certain changes with age.^[24,25] These changes are the nucleus becomes less hydrated, more collagenous and loses proteoglycan, the boundary between nucleus and annulus becomes increasingly blurred, annular-rings thicken, thin cracks and fissures appear in endplate, and nucleus and annulus.^[24,25] In the final stages, the matrix becomes replaced by granulation tissue, or scar ectopic calcification was seen in cases of spinal deformity.^[24,25]

The current study demonstrated that there are no significant histopathological changes seen in herniated disc materials within the nucleus pulposus, such as; increase disc cell proliferation (cartilage cell clusters), degenerated fibrocartilage (pale, fibrillary stroma), cracks and fissure, calcification, and ossification. Moreover, there was no significant correlation between the major histopathological changes of the prolapsed discs and the clinical findings of paresthesia, weakness, and reflex. Although other clinical features were associated with more histological findings, these changes declined over time, and the overall correlation was not significant. Furthermore, the different types of prolapsed discs’ histopathological changes have no impact on the outcome of the surgery. On the other hand, the only correlation found regarding HPDS in our

Table 5: The correlation between low back pain and the histopathological findings of the prolapsed disc

LBP	n	Cracks	Cartilage cell proliferation (cell clusters)	Degenerated fibrocartilaginous stroma
2 weeks - 1 month	2	+	2+	+
		3+	2+	+
2-4 months	6	+	-	+
		+	2+	+/+ calc
		+/+ scar	2+	+/+ calc
		+	+	+
		+	+	+
		3+	3+	+
5 months - 1 year	2	+/+ vas	+/+ scar	+/+ calc
		2+/+ vas	-	-
2-3 years	4	2+/+ vas	+/+ scar	+
		2+/2+vas	2+	+
		2+	3+	+
		3+	3+	+
4-6 years	3	+/+ vasc	-/+ scar	+
		3+	2+/+ scar	+
		3+	3+	+
13-15 years	3	2+	-	+
		+	-	+
		3+	+	+
>30 years	1	2+	3+	+

Table 5. -- Absent; + - Mild; 2+ - Moderate; 3+ - Marked; LBP - Low back pain

Table 6: The correlation between sciatica duration and the histopathological findings of the prolapsed disc

Sciatica duration	n	Cracks	Cartilage cell proliferation (cell clusters)	Degenerated fibrocartilaginous stroma
1 week-1 month	4	3+	2+	+
		3+	3+	+
		+	2+	+
		2+	2+	+
2-4 months	8	3+	2+	+
		2+	3+	+
		+	2+	+
		+	-	+
		3+	3+	+
		+	2+	+
		+	+	+
5 months - 1 year	3	2+	+	+
		+	+	+
		3+	2+	+
		2+	-	+
2-3 years	2	3+	3+	+
		3+	2+	+
4-6 years	1	+/+ vas	-/+scar	+
7-9 years	1	+/+ vas	-/+scar	+
13-15 years	1	+	-	+
>30 years	1	2+	-	-

Table 6. -- Absent; + - Mild; 2+ - Moderate; 3+ - Marked

study was only related to the age of the patient, while gender had no significant correlation.

The published literature has conflict reports regarding the correlation between histopathological changes and

clinical manifestations, which is consistent with our results, where most of the correlation faded away over time, and only a few components persisted. Munarriz *et al.*^[11] have conducted a retrospective consecutive analysis of 122 patients who underwent lumbar

Table 7: The correlation between paresthesia and the histopathological findings of the prolapsed disc

Paraesthesia	<i>n</i>	Cracks	Cartilage cell proliferation (cell clusters)	Degenerated fibrocartilaginous stroma
Yes	17	+	+	+
		+	+	+
		+	-	+
		3+	2+	+
		3+	2+	+
		3+	3+	+
		2+	3+	+
		2+	3+	+
		3+	3+	+
		2+	-	+
		3+	+	+
		3+	3+	+
		+	-	+
		+	2+	+
		+	-	+
No	4	2+	-	+
		2+	+	+
		2+	2+	+
		+	2+	+
		+	2+	+

Table 7. -- Absent; + - Mild; 2+ - Moderate; 3+ - Marked

Table 8: The correlation between motor weakness and the histopathological findings of the prolapsed disc

Motor weakness	<i>n</i>	Cracks	Cartilage cell proliferation (cell clusters)	Degenerated fibrocartilaginous stroma
Yes	11	+	-	+
		3+	2+	+
		3+	3+	+
		2+	3+	+
		2+	3+	+
		3+	3+	+
		2+	-	-
		3+	+	+
		+	2+	+
		+	2+	+
		+	+	+
No	10	2+	-	+
		2+	+	+
		2+	2+	+
		+	+	+
		+	+	+
		3+	2+	+
		3+	3+	+
		+	-	+
		+	2+	+
+	-	+		

Table 8. -- Absent; + - Mild; 2+ - Moderate; 3+ - Marked

disc herniation surgery. They found no significant association between the degree of histological degeneration and clinical (including age and duration of the symptoms) or radiological features of the included patients.^[11] A few other studies have also come to the same conclusion, with no significant correlation could

be established.^[26-29] In contrast, Willburger *et al.*^[30] have included 55 patients in their investigation of the correlation between the histologic composition of the herniated disc fragments and clinical features (pain, disability, clinical signs, and operative findings).

Table 9: The correlation between reflex and the histopathological findings of the prolapsed disc

Reflex	<i>n</i>	Cracks	Cartilage cell proliferation (cell clusters)	Degenerated fibrocartilagenous stroma
Reduce	8	+	-	+
		+	2+	+
		+	+	+
		2+	3+	+
		2+	-	-
		3+	3+	+
		3+	+	+
		3+	2+	+
Absent	6	+	2+	+
		3+	3+	+
		3+	2+	+
		+	+	+
		+	-	+
		3+	3+	+
Normal	7	+	-	+
		+	2+	+
		2+	3+	+
		2+	-	+
		2+	+	+
		2+	2+	+
		+	+	+

Table 10. -- Absent; +- Mild; 2+ - Moderate; 3+ - Marked

Table 10: The correlation between numbness and the histopathological findings of the prolapsed disc

Numbness	<i>n</i>	Cracks	Cartilage cell proliferation (cell clusters)	Degenerated fibrocartilagenous stroma
Yes	21	2+	-	+
		2+	+	+
		2+	2+	+
		+	+	+
		+	+	+
		+	-	+
		3+	2+	+
		3+	2+	+
		3+	3+	+
		2+	3+	+
		2+	3+	+
		3+	3+	+
		2+	-	-
		3+	+	+
		3+	3+	+
		+	-	+
		+	2+	+
		+	-	+
		+	2+	+
		+	+	+
+	-	-		
No	0	0	0	0

Table 8. -- Absent; +- Mild; 2+ - Moderate; 3+ - Marked

Their findings supported a correlation between the histologic composition of the herniated disc fragments and clinical manifestations, including; pain, impaired reflexes, and sensory impairment.^[30]

The limitations of this study may be due to the problems imposed by the small number of cases evaluated in this study. However, the number is still reasonable in comparison with the previous studies.

Conclusions

Our study showed that there is no significant correlation between the major histopathological changes of the prolapsed discs and the clinical findings of paresthesia, weakness, and reflex. Moreover, the different types of prolapsed discs' histopathological changes have no impact on the outcome of the surgery. We also concluded that the disc material undergoes certain degenerative processes with age.

Financial support and sponsorship

Nil.

Conflicts of interest

There are no conflicts of interest.

References

- Majeed SA, Seshadrinath NA, Binoy KR, Raji L. Lumbar disc herniation: Is there an association between histological and magnetic resonance imaging findings? *Indian J Orthop* 2016;50:234-42.
- Freburger JK, Holmes GM, Agans RP, Jackman AM, Darter JD, Wallace AS, *et al.* The rising prevalence of chronic low back pain. *Arch Intern Med* 2009;169:251-8.
- Rannou F, Lee TS, Zhou RH, Chin J, Lotz JC, Mayoux-Benhamou MA, *et al.* Intervertebral disc degeneration: The role of the mitochondrial pathway in annulus fibrosus cell apoptosis induced by overload. *Am J Pathol* 2004;164:915-24.
- Fujii K, Yamazaki M, Kang JD, Risbud MV, Cho SK, Qureshi SA, *et al.* Discogenic back pain: Literature review of definition, diagnosis, and treatment. *JBMR Plus* 2019;3:e10180.
- Baron R, Binder A, Attal N, Casale R, Dickenson AH, Treede RD. Neuropathic low back pain in clinical practice. *Eur J Pain* 2016;20:861-73.
- Murata K, Akeda K, Takegami N, Cheng K, Masuda K, Sudo A. Morphology of intervertebral disc ruptures evaluated by vacuum phenomenon using multi-detector computed tomography: Association with lumbar disc degeneration and canal stenosis. *BMC Musculoskelet Disord* 2018;19:164.
- Dowdell J, Erwin M, Choma T, Vaccaro A, Iatridis J, Cho SK. Intervertebral disk degeneration and repair. *Neurosurgery* 2017;80:S46-54.
- Davis D, Vasudevan A. *Sciatica*. StatPearls. Treasure Island (FL): StatPearls Publishing; 2019.
- Konstantinou K, Dunn KM. *Sciatica*: Review of epidemiological studies and prevalence estimates. *Spine (Phila Pa 1976)* 2008;33:2464-72.
- Damkot DK, Pope MH, Lord J, Frymoyer JW. The relationship between work history, work environment and low-back pain in men. *Spine (Phila Pa 1976)* 1984;9:395-9.
- Munarriz PM, Paredes I, Alén JF, Castaño-Leon AM, Cepeda S, Hernandez-Lain A, *et al.* Assessment of the correlation between histological degeneration and radiological and clinical parameters in a series of patients who underwent lumbar disc herniation surgery. *Neurocirugia (Astur)* 2018;29:79-85.
- Wilson CA, Roffey DM, Chow D, Alkherayf F, Wai EK. A systematic review of preoperative predictors for postoperative clinical outcomes following lumbar discectomy. *Spine J* 2016;16:1413-22.
- Boos N, Weissbach S, Rohrbach H, Weiler C, Spratt KF, Nerlich AG. Classification of age-related changes in lumbar intervertebral discs: 2002 Volvo Award in basic science. *Spine (Phila Pa 1976)* 2002;27:2631-44.
- Cheung KM, Karppinen J, Chan D, Ho DW, Song YQ, Sham P, *et al.* Prevalence and pattern of lumbar magnetic resonance imaging changes in a population study of one thousand forty-three individuals. *Spine (Phila Pa 1976)* 2009;34:934-40.
- Yang H, Liu H, Li Z, Zhang K, Wang J, Wang H, *et al.* Low back pain associated with lumbar disc herniation: Role of moderately degenerative disc and annulus fibrous tears. *Int J Clin Exp Med* 2015;8:1634-44.
- Amin RM, Andrade NS, Neuman BJ. Lumbar disc herniation. *Curr Rev Musculoskelet Med* 2017;10:507-16.
- Benzakour T, Benzakour A. Disc herniation and disc disease: The present and the future of management. *Int Orthop* 2019;43:755-60.
- Shao J, Yu M, Jiang L, Wei F, Wu F, Liu Z, *et al.* Differences in calcification and osteogenic potential of herniated discs according to the severity of degeneration based on Pfirrmann grade: A cross-sectional study. *BMC Musculoskelet Disord* 2016;17:191.
- Weiler C, Lopez-Ramos M, Mayer HM, Korge A, Siepe CJ, Wuertz K, *et al.* Histological analysis of surgical lumbar intervertebral disc tissue provides evidence for an association between disc degeneration and increased body mass index. *BMC Res Notes* 2011;4:497.
- Moore RJ. The vertebral end-plate: What do we know? *Eur Spine J* 2000;9:92-6.
- Urban JP, Roberts S, Ralphs JR. The nucleus of the intervertebral disc from development to degeneration. *Am Zool* 2000;40:53-61.
- Pattappa G, Li Z, Peroglio M, Wismer N, Alini M, Grad S. Diversity of intervertebral disc cells: Phenotype and function. *J Anat* 2012;221:480-96.
- Humzah MD, Soames RW. Human intervertebral disc: Structure and function. *Anat Rec* 1988;220:337-56.
- Choi YS. Pathophysiology of degenerative disc disease. *Asian Spine J* 2009;3:39-44.
- Vernon-Roberts B, Moore RJ, Fraser RD. The natural history of age-related disc degeneration: The pathology and sequelae of tears. *Spine (Phila Pa 1976)* 2007;32:2797-804.
- Rothoerl RD, Woertgen C, Holzschuh M, Rueschoff J, Brawanski A. Is there a clinical correlate to the histologic evidence of inflammation in herniated lumbar disc tissue? *Spine (Phila Pa 1976)* 1998;23:1197-200.
- Rothoerl R, Woertgen C, Holzschuh M, Brehme K, Rueschoff J, Brawanski A. Macrophage tissue infiltration, clinical symptoms, and signs in patients with lumbar disc herniation. A clinicopathological study on 179 patients. *Acta Neurochir (Wien)* 1998;140:1245-8.
- Virri J, Grönblad M, Seitsalo S, Habtemariam A, Kääpä E, Karaharju E. Comparison of the prevalence of inflammatory cells in subtypes of disc herniations and associations with straight leg raising. *Spine (Phila Pa 1976)* 2001;26:2311-5.
- Cayi SR, Koçak A, Alkan A, Kirimlioğlu H. Is there a clinical correlate to the histological and radiological evidence of inflammation in trans-ligamentous extruded and sequestered lumbar disc herniation? *Br J Neurosurg* 2004;18:576-83.
- Willburger RE, Ehiosun UK, Kuhnen C, Krämer J, Schmid G. Clinical symptoms in lumbar disc herniations and their correlation to the histological composition of the extruded disc material. *Spine (Phila Pa 1976)* 2004;29:1655-61.