

## Primary Intracranial Manifestation of a Carcinosarcoma

### Abstract

Carcinosarcomas are tumors comprising part adenocarcinoma and part sarcoma; the presence of carcinosarcoma in the head-and-neck region is very rare. These tumors are typically highly aggressive (G3) and arise most frequently from the salivary gland. Here, we present a case report on a brain metastasis as the primary manifestation of a carcinosarcoma. Magnetic resonance imaging showed a tumor of the pineal region with infiltration of the brainstem and the corpus. The staging following the histopathological diagnosis revealed the origin of the tumor in the left parotid gland. We present an overview of the significance of published treatment strategies in carcinosarcoma.

**Keywords:** Brain tumor, carcinosarcoma, salivary gland

### Introduction

Carcinosarcomas are malignant mixed salivary gland tumors with both malignant epithelial and mesenchymal components. Brain metastasis arising from this kind of tumor is extraordinarily rare. Carcinosarcoma accounts for approximately 0.4%–1.0% of all salivary gland malignancies<sup>[1]</sup> but is known to behave highly aggressively.<sup>[2]</sup>

Cases in which carcinosarcoma arises *de novo* or in the background of a preexisting pleomorphic adenoma have been reported.<sup>[3,4]</sup> If no evidence of benign mixed tumor is present, the lesion is known as carcinosarcoma *de novo*.

Carcinosarcomas are biphasic tumors exhibiting both carcinomatous and sarcomatous elements, and since the 2005 WHO classification of salivary gland tumors, they are recognized as a distinct entity (true malignant mixed tumors).<sup>[5,6]</sup> Generally, carcinosarcomas display frequent local recurrences and metastases, resulting in a poor, 5-year survival prognosis.<sup>[7,8]</sup>

We here report for the first time a patient that was suffering from a brain metastasis as the primary manifestation of carcinosarcoma.

### Case Report

A 42-year-old male was evaluated for headache and nausea in the Department of

This is an open access journal, and articles are distributed under the terms of the Creative Commons Attribution-NonCommercial-ShareAlike 4.0 License, which allows others to remix, tweak, and build upon the work non-commercially, as long as appropriate credit is given and the new creations are licensed under the identical terms.

For reprints contact: reprints@medknow.com

Neurosurgery at Islamic Azad University in Tehran, Iran. The patient reported no dysphagia, otalgia, hoarseness, dyspnea, weight loss, or facial weakness. He had no history of salivary gland pathology or prior head or neck surgery. Clinically, the patient had the signs and symptoms of elevated intracranial pressure. There was no palpable lymphadenopathy. There was a painless lump behind the angle of his left jaw, which he had had for years. It had increased in size over the past 6 months, and there were no associated systemic symptoms. On clinical examination, there was an immobile, firm 15 mm swelling in the area of the parotid tail. The skin overlying the lump was normal in appearance and temperature. His facial nerve function and the rest of his cranial nerve examinations were normal. All other ear, nose, and throat (ENT) examinations were also normal. The routine laboratory blood analyses, consisting of a full blood count, inflammatory markers (erythrocyte sedimentation rate and C-reactive protein), urea, and electrolytes, were within normal limits.

### Magnetic resonance imaging

The initial T1-weighted magnetic resonance (MR) image of the brain showed a large, heterogeneous tumor in the pineal region that infiltrated the surrounding brain tissue. The tumor extended to the midbrain, leading to an aqueduct stenosis and causing occlusive hydrocephalus with elevated intracranial pressure, periventricular edema on

**How to cite this article:** Akhavan-Sigari R, Abdolhoseinpour H, Meyer W, Rohde V, Schulz-Schaeffer W. Primary intracranial manifestation of a carcinosarcoma. *Asian J Neurosurg* 2018;13:923-7.

Reza Akhavan-Sigari<sup>1,2,\*</sup>, Hesam Abdolhoseinpour<sup>3,\*</sup>, Werner Meyer<sup>4</sup>, Veit Rohde<sup>1</sup>, Walter Schulz-Schaeffer<sup>5</sup>

Departments of <sup>1</sup>Neurosurgery and <sup>4</sup>Pathology, University Medical Center, Georg-August-University, Göttingen, <sup>3</sup>Department of Neuropathology, Saarland University Medical Center and Saarland University Faculty of Medicine, Homburg/Saar, Germany, <sup>2</sup>Department of Neurosurgery, Bouali Hospital, Islamic Azad University, <sup>3</sup>Department of Neurosurgery, Islamic Azad University, Tehran, Iran

\* Both authors contributed equally to this work

**Address for correspondence:**  
Prof. Reza Akhavan-Sigari,  
Robert-Koch-Strasse 40,  
37075 Göttingen, Germany.  
E-mail: rasigari@yahoo.de

Access this article online

Website: [www.asianjns.org](http://www.asianjns.org)

DOI: 10.4103/ajns.AJNS\_19\_18

Quick Response Code:



T2-weighted MR images, and enlargement of third and lateral ventricles [Figure 1a, b and d]. After gadolinium application, a contrast enhancement in the splenium of the corpus callosum and the pineal region was observed. On T2-weighted images, high signal intensities around the tumor suggested an extensive edema. An intra-axial tumor was diagnosed, with a likelihood of malignant glioma.

The differential diagnosis for a solitary, heterogeneously contrast medium-enhancing intra-axial tumor with necrosis also includes metastases. Although metastases differ widely in appearance, the large size of the lesion, the pattern of growth, and lack of multiplicity, in this case, suggest a primary tumor as most likely. A resection of the tumor was indicated.

### Neurosurgical procedure and gross pathology

The tumor was surgically removed as widely as possible using a supracerebellar infratentorial approach. The vein of Galen ran anterior and inferior to the tumor and was saved during tumor resection. Often no clear demarcation was found between tumor and healthy tissue. There was also a compression of the mesencephalic aqueduct. The tumor showed a prominent vascularization and some notably

yellowish areas of necrosis and hemorrhages. The adjacent tissue was edematous.

### Histology of the brain biopsy

Two completely different aspects of the tumor could be observed under the microscope: an adenocarcinoma and a sarcoma part, both with a malignancy Grade 3 [Figure 2]. The adenocarcinoma showed an infiltration into surrounding tissue. Some areas were differentiated to papillary and tubular structures. Areas of tumor necroses were seen. Some tubules contained necrotic cells, and atypical mitoses were seen frequently. Immunohistochemically, the cells of this area presented the pan-carcinoma antigen AE 1/3 and the cytokeratin 7. In 40% of the cells, the nuclear cell proliferation marker Ki-67 was detectable.

The sarcoma part showed a storiform growth pattern and clusters of very pleomorphic cells containing multinucleated giant cells within which several atypical mitoses were present. Immunohistochemically, the mesenchymal differentiation of this part of the tumor was demonstrated by the expression of vimentin. The giant cells and 50% of the storiform cells expressed the pan-macrophage antigen KiM1P. A proliferative activity

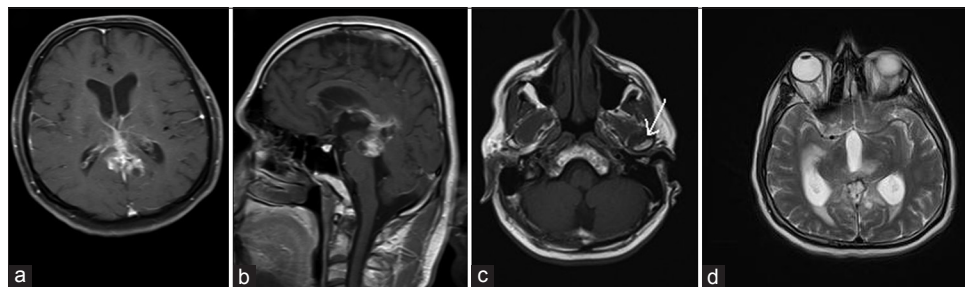


Figure 1: T1-weighted magnetic resonance images with gadolinium demonstrating the intracranial carcinosarcoma metastasis in an axial (a) and sagittal (b) plane. A partially cystic, partially hemorrhagic, space-occupying lesion with inhomogenous gadolinium-enhancing in the pineal region is seen infiltrating the brain stem, thalamus, and the splenium of the corpus callosum. A compression of the aqueduct caused an occlusive hydrocephalus with periventricular edema on T2-weighted magnetic resonance images and enlargement of third and lateral ventricles (d). Magnetic resonance images from the left parotid gland (c) show a gadolinium-enhancing cystic lesion (arrow) that is assumed to be the primary manifestation of the tumor

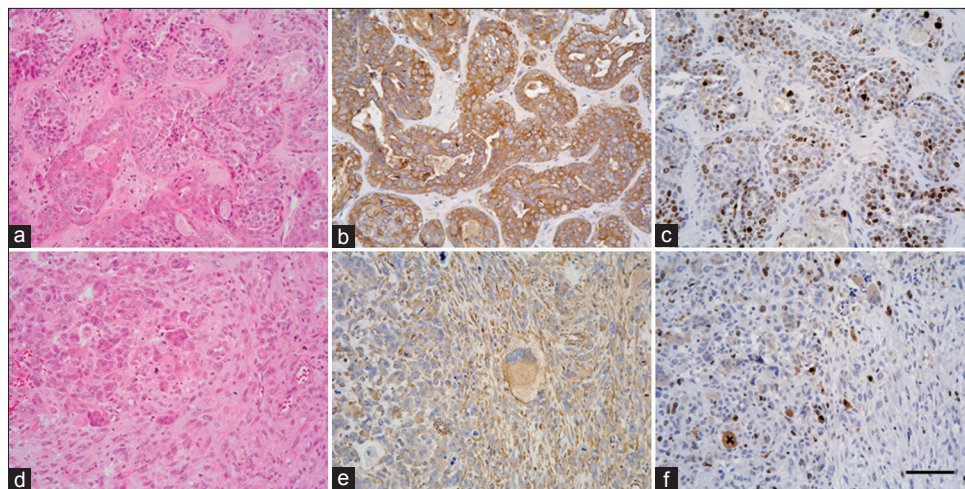


Figure 2: Histology of the adenocarcinoma (a-c) and the sarcoma part (d-f) of the brain metastasis of a carcinosarcoma. The carcinoma shows tubular and pseudopapillary structures (a, H and E), that express the pan-epithelial antigen AE1/3 (b) and is highly proliferative (c, MIB1). The sarcoma shows abundant giant cells (d, H and E), express vimentin (e), and is highly proliferative as well



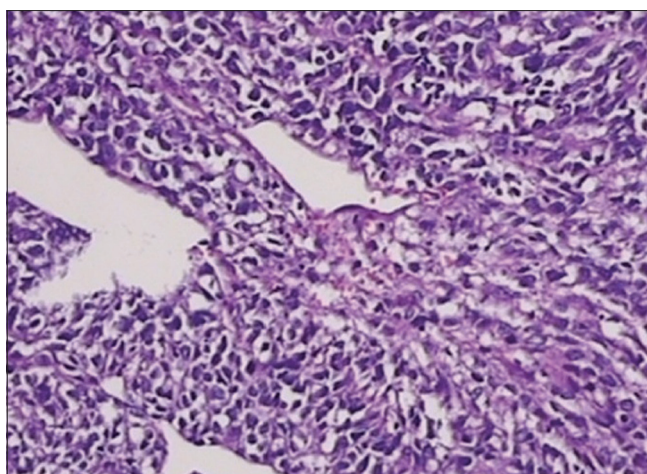


Figure 3: Histopathology image of the excised parotid gland carcinosarcoma – x10

was seen in 15% of the cells as determined by the antibody Ki-67.

### Staging after histopathological diagnosis

A complete physical examination and workup for additional tumor manifestations were performed but revealed no evidence of disease elsewhere, though a small cystic lesion with some mineralization in the left parotid gland was found on MR imaging (MRI)-Images [Figure 1c]. The parotid tumor was considered to be the primary manifestation. A connection between the extracranial and the intracranial tumor could not be found. The intracranial tumor was the only metastasis of the parotid tumor. The ENT colleagues were consulted.

The patient proceeded to have a left superficial parotidectomy [Figure 4]. Microscopically, the histological specimen showed a well-circumscribed tumor with some variability in appearance. Centrally, there was a hyalinized degenerative area, at the edge of which were some small islands and clusters of malignant epithelial cells [Figure 3]. These blended into a more spindled area with a sarcomatoid appearance having both a distinctive storiform pattern and focally numerous multinucleated tumor giant cells. There was no evidence of differentiation. This is in keeping with a primary tumor in the parotid gland. Immunohistochemistry showed that this had biphasic characteristic with a definite epithelial and sarcomatous component. Immunohistochemical analyses with vimentin, p63, S-100, and cytokeratin were positive. These findings are in keeping with carcinosarcoma of the parotid gland.

The postoperative course was uneventful. The House-Brackmann facial nerve grading revealed mild dysfunction (Grade II). Unfortunately, the patient refused any kind of further treatment and did not return for follow-up.

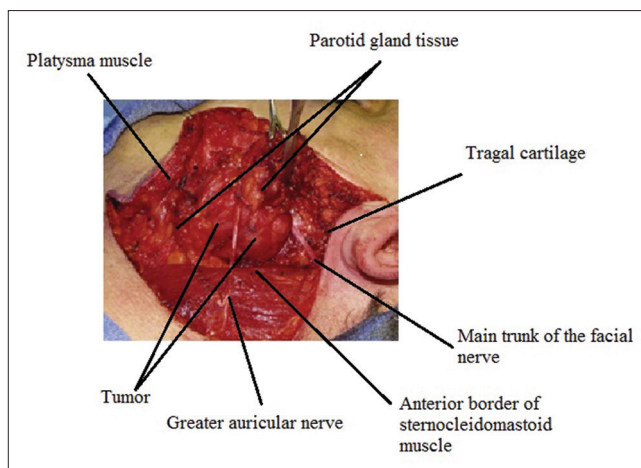


Figure 4: Surgical procedure of partial superficial parotidectomy. The skin incision is carried to the subcutaneous tissue and platysma muscle. The greater auricular nerve as it runs over the sternocleidomastoid muscle is identified and preserved. After finding the trunk of the facial nerve and its branches, partial superficial parotidectomy was performed, resulting in the removal of some surrounding parotid parenchyma

### Discussion

Carcinosarcomas of the head-and-neck region are extremely rare. Nearly 60 cases have been reported so far.<sup>[5,9-11]</sup> Two-thirds arise in the parotid gland, approximately 19% in the submandibular glands and 14% in the palate.<sup>[12]</sup> Single cases of tumors in the tongue and the supraglottic region have been reported.<sup>[13]</sup> However, to the best of our knowledge, a carcinosarcoma presenting as a supratentorial solid brain metastasis has not been reported before. The most common epithelial-origin tumor is squamous cell carcinoma or adenocarcinoma, whereas the most common sarcomatous tumors are chondrosarcoma and osteosarcoma.<sup>[14]</sup> There are reports of true malignant mixed tumors occurring up to 30 years after radiation therapy of a pleomorphic adenoma.<sup>[15,16]</sup>

Gnepp<sup>[5]</sup> summarized 43 cases of carcinosarcoma of the salivary glands published in the literature. The mean age at presentation for 34 patients with available data was 58 years (range: 14–87 years). There was no sex predominance.

The prognosis for the patients is poor. There is a recurrence rate of 70% within the first 2 years,<sup>[17,18]</sup> and of 90% within 3 years.<sup>[19]</sup> Metastases to the lung, bones, and central nervous system occur in 50% of patients within 18–60 months.<sup>[5,17]</sup> The 5-year survival rate for patients with carcinosarcoma is reported to be 0%.<sup>[20]</sup> Conversely, the reported global survival rate of patients with malignant tumors of the parotid gland is approximately 54%,<sup>[21]</sup> with an average survival ranging from 29 months to 3 years.<sup>[5,22]</sup>

Solitary brain metastases are sometimes difficult to distinguish from malignant gliomas with imaging techniques alone. MRI is the imaging modality of choice

for preoperative evaluation because of its soft-tissue resolution and capacity to detect perineural invasion.

Due to its rareness, there is no well-established therapeutic approach for the treatment of carcinosarcoma.<sup>[23]</sup> Surgical removal followed by radiotherapy seems to be the most rational approach, despite the fact that the available data are not prospective or statically significant and vary widely among studies.<sup>[13,14]</sup> The combination of surgery followed by radiotherapy seems to be statistically superior to resection alone.<sup>[18,19]</sup> The recurrence rate for carcinosarcoma patients who had undergone surgery plus radiotherapy is significantly lower than for those who were treated by surgery alone ( $P = 0.030$ ).<sup>[24]</sup>

Once a salivary gland tumor is detected, it is important that the tumor is resected as early as possible to prevent its evolving into a highly aggressive tumor.<sup>[16]</sup> A brain metastasis of a salivary gland carcinosarcoma is exceedingly rare, and therefore a well-established therapeutic approach is lacking.<sup>[23]</sup> The role of chemotherapy remains unclear.

Carcinosarcoma of the parotid arising after irradiation of a pleomorphic adenoma after resection has been described.<sup>[22,25]</sup> The disease recurs in approximately two-thirds of patients and metastases in about half of them.<sup>[26]</sup>

There is a good correlation between stage and local extension of irradiation-associated tumors and prognosis. Facial nerve palsy and grade of malignancy are important prognostic factors.<sup>[27]</sup>

## Conclusions

The primary intracranial manifestation of a carcinosarcoma mimicking a glioma has not been reported previously. Salivary gland carcinosarcoma is a rare and highly aggressive disease with poor prognosis because local recurrence and distal metastases are common. The biphasic nature of carcinosarcoma leads to the diagnosis. The current treatment of choice is a combination of radical surgical excision and radiotherapy, although the number of reported cases is limited. There are few data on the efficacy of chemotherapy, and further investigations are needed.

## Declaration of patient consent

The authors certify that they have obtained all appropriate patient consent forms. In the form the patient(s) has/have given his/her/their consent for his/her/their images and other clinical information to be reported in the journal. The patients understand that their names and initials will not be published and due efforts will be made to conceal their identity, but anonymity cannot be guaranteed.

## Financial support and sponsorship

Nil.

## Conflicts of interest

There are no conflicts of interest.

## References

1. Ellis GL, Gnepp DR. Surgical Pathology of the Salivary Glands. Vol. 25. Philadelphia, USA: WB Saunders Company; 1991.
2. Liess BD, Hirschi S, Zitsch RP 3<sup>rd</sup>, Frazier S, Konrad A. Carcinosarcoma of the parotid gland: Report of a case with immunohistochemical findings. *Ann Otol Rhinol Laryngol* 2007;116:702-4.
3. Bleiweiss IJ, Huvos AG, Lara J, Strong EW. Carcinosarcoma of the submandibular salivary gland. *Immunohistochemical findings. Cancer* 2006;69:2031-5.
4. Dardick I, Hardie J, Thomas MJ, Peter Nostrand AV. Ultrastructural contributions to the study of morphological differentiation in malignant mixed (pleomorphic) tumors of salivary gland. *Head Neck* 1989;11:5-21.
5. Gnepp DR. Malignant mixed tumors of the salivary glands: A review. *Pathol Annu* 1993;28 Pt 1:279-328.
6. Barnes L, Eveson JW, Reichart P, Sidransky D. World Health Organization Classification of tumors. Pathology and Genetic of Head and Neck Tumors. Lyon, France: SARC Press; 2005.
7. Götte K, Riedel F, Coy JF, Spahn V, Hörmann K. Salivary gland carcinosarcoma: immunohistochemical, molecular genetic and electron microscopic findings. *Oral Oncol* 2000;36:360-4.
8. Pang PC, To EW, Tsang WM, Liu TL. Carcinosarcoma (malignant mixed tumor) of the parotid gland: A case report. *J Oral Maxillofac Surg* 2001;59:583-7.
9. Alvarez-Cañas C, Rodilla IG. True malignant mixed tumor (carcinosarcoma) of the parotid gland. Report of a case with immunohistochemical study. *Oral Surg Oral Med Oral Pathol Oral Radiol Endod* 1996;81:454-8.
10. Gogas J, Markopoulos C, Karydakis V, Gogas G, Delladetsima J. Carcinosarcoma of the submandibular salivary gland. *Eur J Surg Oncol* 1999;25:333-5.
11. Sironi M, Isimbaldi G, Claren R, Delpiano C, Di Nuovo F, Spinelli M. Carcinosarcoma of the parotid gland: Cytological, clinicopathological and immunohistochemical study of a case. *Pathol Res Pract* 2000;196:511-7.
12. Douglas R, Gnepp M. Diagnostic Surgical Pathology of the Head and Neck. Philadelphia, USA: WB Saunders Company; 2001. p. 197-201.
13. Ja E, Dw F, Jp S. Initial report of a case of carcinosarcoma of the supraglottis. *Ear Nose Throat J* 2000;79:384-7.
14. Kwon MY, Gu M. True malignant mixed tumor (carcinosarcoma) of parotid gland with unusual mesenchymal component: A case report and review of the literature. *Arch Pathol Lab Med* 2001;125:812-5.
15. Alterio D, Jereczek-Fossa BA, Griseri M, D'Onofrio A, Giugliano G, Fiore MR, *et al.* Three-dimensional conformal postoperative radiotherapy in patients with parotid tumors: 10 years' experience at the European Institute of Oncology. *Tumori* 2011;97:328-34.
16. Withrow ST, Vail D, Page R. Withrow and MacEwen's Small Animal Clinical Oncology. St. Louis, Missouri: Elsevier Saunders; 5<sup>th</sup> ed. 2012. p. 240-2.
17. Tran L, Sadeghi A, Hanson D, Juillard G, Mackintosh R, Calcaterra TH, *et al.* Major salivary gland tumors: Treatment results and prognostic factors. *The Laryngoscope* 1986;96:1139-44.
18. Kane WJ, McCaffrey TV, Olsen KD, Lewis JE. Primary parotid malignancies. A clinical and pathologic review. *Arch Otolaryngol*

- Head Neck Surg 1991;117:307-15.
19. Byun TS, Fayos JV, Kim YH. Management of malignant salivary gland tumors. *Laryngoscope* 1980;90:1052-60.
  20. Tortoledo ME, Luna MA, Batsakis JG. Carcinomas ex pleomorphic adenoma and malignant mixed tumors. Histomorphologic indexes. *Arch Otolaryngol* 1984;110:172-6.
  21. Magnano M, Fernando Gervasio C, Cravero L, Machetta G, Lerda W, Beltramo G, *et al.* Treatment of malignant neoplasms of the parotid gland. *Otolaryngol Head Neck Surg* 1999;121:627-32.
  22. Spraggs PD, Rose DS, Grant HR, Gallimore AP. Post-irradiation carcinosarcoma of the parotid gland. *J Laryngol Otol* 1994;108:443-5.
  23. Horky JK, Chaloupka JC, Putman CM, Roth TC, Weaver EM, Sasaki CT. True malignant mixed tumor (carcinosarcoma) of tonsillar minor salivary gland origin: Diagnostic imaging and endovascular therapeutic embolization. *Am J Neuroradiol* 1997;18:1944-8.
  24. Staffieri C, Marioni G, Ferraro SM, Marino F, Staffieri A. Carcinosarcoma de novo of the parotid gland. *Oral Surg Oral Med Oral Pathol Oral Radiol Endodontol* 2007;104:e35-40.
  25. Granger JK, Houn HY. Malignant mixed tumor (carcinosarcoma) of parotid gland diagnosed by fine-needle aspiration biopsy. *Diagn Cytopathol* 1991;7:427-32.
  26. LiVolsi VA, Perzin KH. Malignant mixed tumors arising in salivary glands. I. Carcinomas arising in benign mixed tumors: A clinicopathologic study. *Cancer* 1977;39:2209-30.
  27. Pedersen D, Overgaard J, Søgaard H, Elbrønd O, Overgaard M. Malignant parotid tumors in 110 consecutive patients: Treatment results and prognosis. *Laryngoscope* 1992;102:1064-9.