

Atypical Symptomatic Bilateral Spontaneous Cavernous Carotid Aneurysm with Systemic Vessel Wall Pathology in Young Female: A Rare Case Report

Abstract

Bilateral cavernous carotid aneurysm (CCA) is a rare entity. Its association with connective tissue disorder makes the diagnosis and treatment of symptomatic patient an enigma. We present a case report of a 25-year-old female medical student presented to us with bilateral spontaneous atypically symptomatic CCA with incidentally diagnosed case of Ehlers–Danlos syndrome. Both surgical and endovascular options of treatment were weighed and were ultimately treated satisfactorily by high-flow bypass with carotid artery ligation with an insurance bypass.

Keywords: *Bilateral cavernous carotid aneurysm, Ehlers–Danlos syndrome, high-flow bypass, insurance bypass*

Introduction

Cavernous carotid aneurysms (CCAs) are considered benign and mostly asymptomatic vessel pathology. It accounts for 2%–5% of all intracranial aneurysms.^[1] Bilateral CCAs are even more rare. They can be idiopathic, traumatic, or infectious in etiology. Due to their location in cavernous sinus and encased in the dura layer, risk of life-threatening complications is less. CCAs are more commonly reported in women and older age, the youngest being 3 weeks old neonate. We intend to present a case who presented to us with atypical symptomatology and with suspected systemic vessel wall disease in a young female.

Case Report

History

A 25-year-old female student presented to us with a complaint of intermittent headache with tremor dysarthria and mild weakness on the right side of her body. The patient had no history of ptosis, diplopia, or decreased vision. There was no record of any systemic diseases and connective tissue disorders. Initially,

she was managed symptomatically and evaluated.

Neurological examination of the patient was not significant.

Computed tomography of the brain and angiogram and magnetic resonance imaging were done followed by digital subtraction angiography which showed bilateral large cavernous segment aneurysms of the internal carotid artery (ICA) right more than left with fusiform dilatation of V2 segment of vertebral arteries and right ICA at CCA bifurcation [Figure 1]. Although endovascular management was at our disposal, we preferred microvascular management because of the following reasons:

1. In the present case, the aneurysm neck was too wide for single flow diverter to be considered as an option. Although multiple flow diverters can be used in tandem, they are found to be more unstable and failure can occur
2. Our patient was young and flow diverter use would have left her on lifelong antiplatelets and anticoagulants
3. With systemic vessel wall disease, complications such as vessel wall

This is an open access journal, and articles are distributed under the terms of the Creative Commons Attribution-NonCommercial-ShareAlike 4.0 License, which allows others to remix, tweak, and build upon the work non-commercially, as long as appropriate credit is given and the new creations are licensed under the identical terms.

For reprints contact: reprints@medknow.com

How to cite this article: Miyatani K, Korde P, Yamada Y, Kawase T, Takizawa K, Kato Y. Atypical symptomatic bilateral spontaneous cavernous carotid aneurysm with systemic vessel wall pathology in young female: A rare case report. *Asian J Neurosurg* 2019;14:1245-8.

**Kyosuke Miyatani,
Paresh Korde,
Yasuhiro Yamada,
Tsukasa Kawase,
Katsumi Takizawa¹,
Yoko Kato**

Department of Neurosurgery, Banbutane Hotokukai Hospital, Fujita Health University, Nagoya, Aichi, ¹Department of Neurosurgery, Asahikawa Red Cross Hospital, Asahikawa, Japan

Address for correspondence:

*Dr. Paresh Korde,
Flat No. 8, Meghdoot Building
No. 3, JNMC Campus, Sawangi,
Meghe, Wardha - 442 001,
Maharashtra, India.
E-mail: pareshkorde4532@
gmail.com*

Access this article online

Website: www.asianjns.org

DOI: 10.4103/ajns.AJNS_210_19

Quick Response Code:



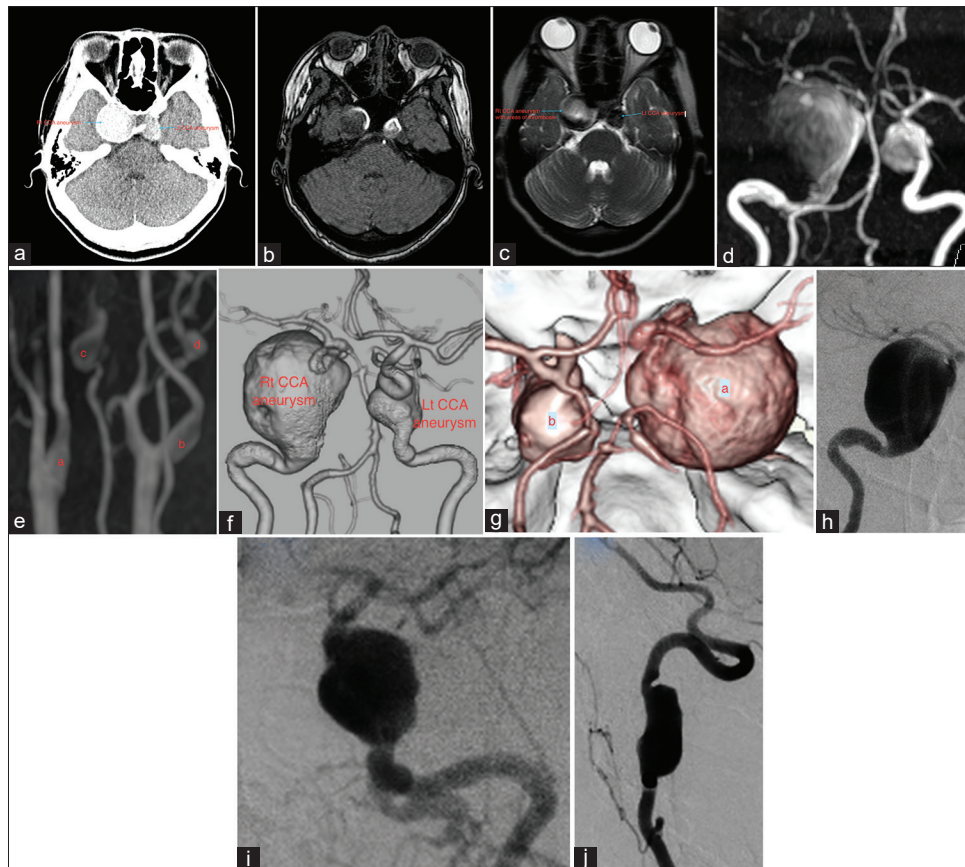


Figure 1: Preoperative computed tomography brain, magnetic resonance imaging brain and angiogram, three-dimensional computed tomography angiogram, and digital subtraction angiography. (a) Preoperative computed tomography. (b and c) T1- and T2-weighted image magnetic resonance imaging. (d) Magnetic resonance angiography brain. (e) Magnetic resonance angiography neck. (i) Right internal carotid artery. (ii) Left internal carotid artery. (iii) Right vertebral artery. (iv) Left vertebral artery. (f and g) Three-dimensional computed tomography angiogram. (h) Right cavernous carotid aneurysm. (i) Left cavernous carotid aneurysm. (j) Vertebral artery aneurysm on digital subtraction angiography

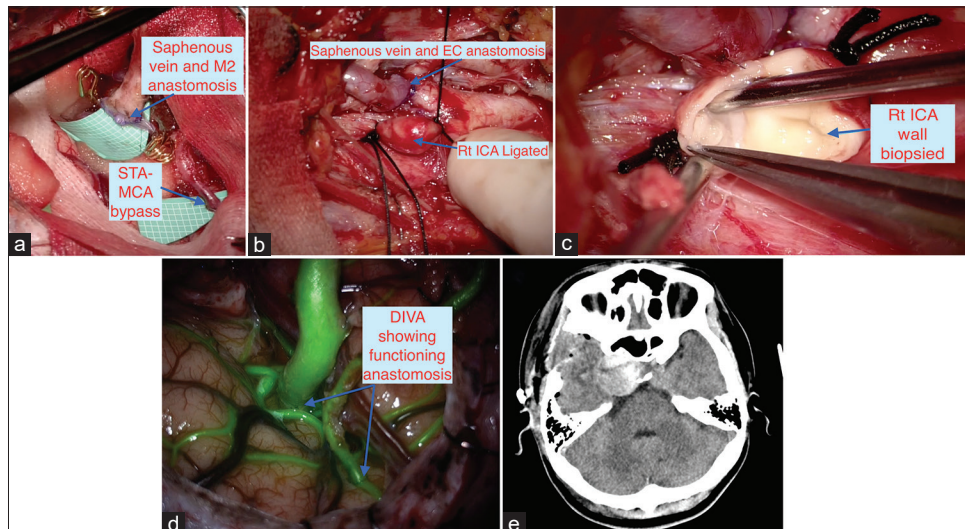


Figure 2: Intraoperative images and postoperative computed tomography. (a) Saphenous vein-M2 and superficial temporal artery-middle cerebral artery anastomosis. (b) Saphenous vein-EC anastomosis and ligation of the cervical internal carotid artery. (c) Wall biopsy of the internal carotid artery. (d) Final dual-image video angiography. (e) Postoperative computed tomography

dissection along with other known complications such as thromboembolic phenomenon from the thrombus in giant aneurysm can happen even at experienced hands during endovascular procedure

4. Due to our expertise in microvascular neurosurgery and patients and her relatives choice, microsurgical management in form of extracranial-intracranial (EC-IC) bypass was opted.

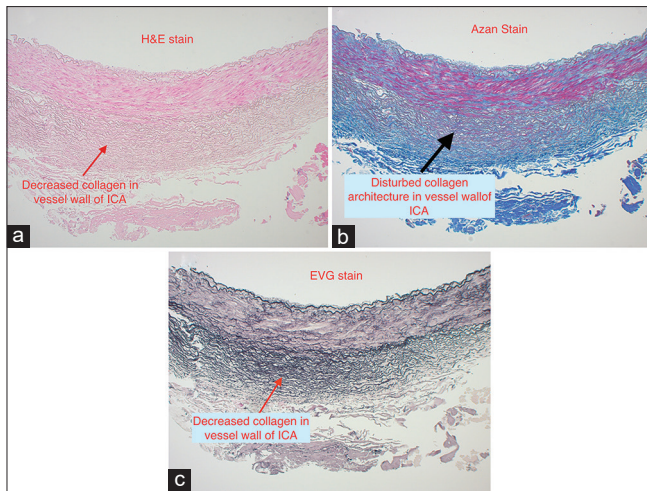


Figure 3: Histopathology slides with H and E, Azan and EVG staining of the internal carotid artery. (a) H and E stain. (b) Azan stain. (c) EVG stain

The patient underwent preoperative workup and optimized for planned surgery.

High-flow EC-IC bypass with radial artery graft with insurance superficial temporal artery-middle cerebral artery (STA-MCA) bypass was planned. Intraoperatively, the right radial artery which was exposed for harvesting was found to have abnormal fusiform dilatation in its wall. Decision of harvesting the saphenous vein from the right lower limb instead of the radial artery as a graft was made. The rest of the procedure went uneventful with STA-MCA bypass then EC-IC high-flow bypass with saphenous vein graft and ligation of the right ICA at CCA bifurcation. Intraoperatively, indocyanine green and dual-image video angiography revealed functional bypass and no flow in right ICA. Due to suspicion of vessel wall abnormality encountered at the right radial artery and right ICA, wall biopsy of the right ICA, right saphenous vein, and right extracranial aneurysm (ECA) was sent for histopathological examination [Figure 2]. H and E staining, Azan staining, and elastic-Van Gieson staining were used. Biopsy from right ICA showed decreased density of elastic fibers in intima of the vessel. Disturbed angioarchitecture with drop out and tears and fragile vessel wall [Figure 3]. It was reported to be suggestive of Ehlers-Danlos syndrome (EDS). Postoperatively, the patient did well and had transient right hypoglossal nerve palsy due to handling during the isolation of cervical ICA and preparing tunnel for the saphenous vein graft. The 12th cranial nerve palsy improved during the patient hospital stay. The patient is planned for endovascular procedure on the left side.

Discussion

Cavernous segment aneurysms of ICA are rare, and their bilateral presentation is still more uncommon.^[2] These are more common in women. Hypertension, trauma, connective tissue disease, systemic mycosis, fibromuscular dysplasia, and radiotherapy are known to be associated with CCA.^[3] Unlike

other aneurysms, subarachnoid hemorrhage (SAH) risk is 0.2%–0.4% per year. The International Study of Unruptured Intracranial Aneurysms study substantiates the same by measuring 5 years rupture rate 0% for size <12 mm, 3% for 13–24 mm, and 6.4% for >25mm aneurysm.^[4] Although complications such as rupture of aneurysm in cavernous sinus, SAH, carotico-cavernous fistula, compression of adjacent cranial nerves and acute thrombosis of aneurysm are known to happen, but are uncommon. Bilateral CCA may at times mimic other diseases such as myasthenia gravis and isolated nerve palsies, but most aneurysms remain relatively asymptomatic till they grow to larger size. Our patient presented with atypically with tremors and right-sided weakness and dysarthria.

Despite various treatment strategies, no consensus has been arrived.^[5] CCAs because of their indolent course and asymptomatic nature mostly managed by the regular follow-up.^[6] Some authors consider surgical treatment while others prefer endovascular management for symptomatic aneurysm. Surgical treatment can be direct and indirect. Clipping of the aneurysm, aneurysmorrhaphy, aneurysm trapping, and bypass grafting^[6] which is technically difficult and carries more risk of neurodeficits are included in direct surgical treatment. Indirect surgical treatment with or without bypass includes trapping or occlusion of proximal ICA with or without low-flow or high-flow bypass.^[2] Endovascular arm of this treatment protocol includes use of flow diverters or parent vessel occlusion if cross circulation is well enough and coil embolization.^[7]

Due to benign course of the disease and relatively asymptomatic presentation, choice of treatment modality to offer the patient is a double-edged sword. However, treating a symptomatic patient is a need. Long-term outcome has been stable or better for symptomatic patient who undergone treatment. On the other hand, the patient has been followed up despite being symptomatic has shown deterioration.^[8] We at our institute opted for the indirect surgical management usually high-flow bypass and ICA ligation due to our surgical expertise and experience.

Cerebral ischemia during the prolonged clipping of the aneurysm or during performing high-flow bypass is a matter of concern, as it can potentially cause deficits in the patient. Such a hurdle can be overcome by doing insurance bypass before the main bypass procedure to improve surgical outcome as done in our patient.^[9,10]

Furthermore, our patient seems to have some systemic vessel wall diseases as multiple fusiform dilatation of the vessel could be appreciated on preoperative angiograms in ICA and vertebral artery and confirmed intraoperatively on right ICA at common carotid artery bifurcation and right radial artery. Biopsy of the suspected disease segment of the right ICA, saphenous vein wall, and right ECA histopathology was suggestive of EDS. EDS is heterogeneous genetic disorder^[11] and due to its phenotypic variance is not easy to diagnose as happened in our case. EDS type IV is the most

common variant encountered by the surgeon as it presents with some kind of vessel wall pathology such as aneurysms, arteriovenous fistula, gastrointestinal bleeding, aortic or vessel wall dissection, and pseudoaneurysm. EDS type IV is the most malignant form caused by the mutation in COL3A1 gene coding for type III procollagen.^[12] The diagnosis can be confirmed by dermal fibroblast culture for type III procollagen molecules and genetic testing. Best possible management is conservative treatment and follow-up if possible. Even in experienced hands, endovascular procedures are known to cause dissection of the vessel wall during catheterization.^[11,13]

With such clinical picture, we find our offered treatment to be justifiable and cost-effective as compared to endovascular management. In the background of suspected vessel wall disease, multiple intra and ECA both in anterior and posterior circulations, the wide neck of the aneurysm and younger age of the patient opting for endovascular treatment, posing the patient to risk of vessel wall dissection, and keeping the patient on anticoagulants for flow diverter could have been a lurking danger. Apart from the transient right hypoglossal palsy, the patient recovered well. Occlusion of ICA on one side will definitely have some changes in circulatory flow dynamics which may lead to opposite and other aneurysms to grow.^[14] Hence, we plan to go for the second stage and operate patient on other side also once she recovers fully and gets optimized.

Conclusion

Bilateral CCA though rare mandate treatment whenever symptomatic. In an endovascular and minimally invasive era of neurosurgery, high-flow bypass continue to ground its feet. In cases with systemic vessel wall disease and symptomatic bilateral CCA in the younger group of patients, standard indirect surgical methods of treating them can be considered as a novel option. More number of such cases may be helpful to formulate a treatment protocol for the better management of patient.

Declaration of patient consent

The authors certify that they have obtained all appropriate patient consent forms. In the form the patient(s) has/have given his/her/their consent for his/her/their images and other clinical information to be reported in the journal. The patients understand that their names and initials will not be published and due efforts will be made to conceal their identity, but anonymity cannot be guaranteed.

Financial support and sponsorship

Nil.

Conflicts of interest

There are no conflicts of interest.

References

1. Matsumoto K, Kato A, Fujii K, Fujinaka T, Fukuhara R. Bilateral giant intracavernous carotid artery aneurysms mimicking a cavernous sinus neoplasm case report. *Neurol Med Chir (Tokyo)* 1996;36:583-5.
2. Sriamornrattanukul K, Sakarunchai I, Yamashiro K, Yamada Y, Suyama D, Kawase T, *et al.* Surgical treatment of large and giant cavernous carotid aneurysms. *Asian J Neurosurg* 2017;12:382-8.
3. Bodla AA, Ablett M, Inglis A. Bilateral intracavernous carotid artery aneurysms presenting as progressive cranial nerve palsies. *Clin Exp Optom* 2007;90:207-8.
4. Ambekar S, Madhugiri V, Sharma M, Cuellar H, Nanda A. Evolution of management strategies for cavernous carotid aneurysms: A review. *World Neurosurg* 2014;82:1077-85.
5. Menon S, Menon RG. Cavernous carotid aneurysms: To do or not to do? *J Neurosci Rural Pract* 2017;8:284-7.
6. Surgical Management of Intracavernous Carotid Artery Aneurysms: BNI Experience. Available from: <https://www.barrowneuro.org/education/grand-rounds-publications-and-media/barrow-quarterly/volume-13-no-2-1997/surgical-management-intracavernous-carotid-artery-aneurysms-bni-experience>. [Last accessed on 2019 Jun 07].
7. Tanweer O, Raz E, Brunswick A, Zumofen D, Shapiro M, Riina HA, *et al.* Cavernous carotid aneurysms in the era of flow diversion: A need to revisit treatment paradigms. *AJNR Am J Neuroradiol* 2014;35:2334-40.
8. Goldenberg-Cohen N, Curry C, Miller NR, Tamargo RJ, Murphy KP. Long term visual and neurological prognosis in patients with treated and untreated cavernous sinus aneurysms. *J Neurol Neurosurg Psychiatry* 2004;75:863-7.
9. Raheja A, Suri A, Sreenivasan SA, Singla R. Insurance and flow-alteration superficial temporal artery to middle cerebral artery (STA-MCA) bypass in management of complex anterior intracranial circulation aneurysms in postendovascular era. *World Neurosurg* 2019;126:e1387-98.
10. Ono H, Inoue T, Tanishima T, Tamura A, Saito I, Saito N, *et al.* High-flow bypass with radial artery graft followed by internal carotid artery ligation for large or giant aneurysms of cavernous or cervical portion: Clinical results and cognitive performance. *Neurosurg Rev* 2018;41:655-65.
11. Jindal R, Choong A, Arul D, Dhanjil S, Chataway J, Cheshire NJ. Vascular manifestations of Type 4 Ehlers-Danlos syndrome. *EJVES Extra* 2005;9:135-8. Available from: <https://www.sciencedirect.com/science/article/pii/S1533316705000476>. [Last accessed on 2019 Jun 11].
12. Germain DP, Herrera-Guzman Y. Vascular Ehlers-Danlos syndrome. *Ann Genet* 2004;47:1-9.
13. Horowitz MB, Purdy PD, Valentine RJ, Morrill K. Remote vascular catastrophes after neurovascular interventional therapy for Type 4 Ehlers-Danlos syndrome. *AJNR Am J Neuroradiol* 2000;21:974-6.
14. Nishino K, Hasegawa H, Ito Y, Fujii Y. Bilateral cavernous carotid aneurysms: The growth potential of a contralateral aneurysm after therapeutic unilateral internal carotid artery occlusion. *J Stroke Cerebrovasc Dis* 2015;24:1865-72.