

Case Report

Temporary Worsening of Perianeurysmal Edema Following Clipping of a Partially Thrombosed Giant Pericallosal Artery Aneurysm

Abstract

We present a case of a partially thrombosed giant aneurysm of the pericallosal artery that experienced a temporary worsening of perianeurysmal edema after clipping. A 66-year-old man presented with progressive weakness of the right leg. Imaging studies revealed a partially thrombosed giant aneurysm at the bifurcation of the left pericallosal artery with concomitant perianeurysmal edema. The aneurysm was thought responsible for the symptoms of the patient, and he agreed to undergo clipping surgery. The aneurysmal neck was clipped using two long aneurysm clips without dissecting the aneurysmal dome. The patient woke up from anesthesia with the right-sided hemiparesis, which progressed to hemiplegia by 12 h after surgery. Brain computed tomography revealed worsening of the perianeurysmal edema. Fortunately, his symptoms resolved completely by 2 weeks after surgery with conservative management. Perianeurysmal edema is frequently observed in patients with partially thrombosed giant aneurysms. Although worsening of perianeurysmal edema is a relatively common complication of endovascular procedures, its occurrence after clipping has rarely been reported. The worsening may have been induced by release of inflammatory cytokines from aneurysm wall, which was rendered ischemic due to obliteration of the vasa vasorum by the clips. Perianeurysmal edema may develop or worsen after clipping of a partially thrombosed giant aneurysm if the interface between the aneurysm and surrounding brain is not fully dissected.

Keywords: *Clipping, giant aneurysm, perianeurysmal edema, vasa vasorum*

Introduction

Despite recent advances in surgical technique and endovascular devices, treatment of giant intracranial aneurysms remains difficult; patients not infrequently sustain serious perioperative complications, particularly brain ischemia.^[1,2] Perianeurysmal edema is a frequent imaging finding in patients with partially thrombosed giant intracranial aneurysms at the time of diagnosis. Worsening of perianeurysmal edema is a relatively common complication of endovascular procedures.^[3-8] However, worsening of perianeurysmal edema after clipping has rarely been reported. Here, we report a case of a partially thrombosed giant aneurysm of the pericallosal artery that sustained temporary worsening of perianeurysmal edema after clipping.

Case Report

A 66-year-old man with a history of congestive heart failure presented with gradually worsening weakness of the right

leg. The patient reported no episodes of severe headache or seizure. Computed tomography (CT) of the brain revealed a homogeneously high-density mass (maximal length 39 mm) in the left frontal lobe with surrounding edema [Figure 1a-c]. Three-dimensional CT angiography (3D-CTA) revealed a partially thrombosed giant aneurysm at the bifurcation of the left pericallosal artery [Figure 1d and e] and his symptoms were likely caused by the aneurysm. The patient agreed to undergo treatment to obliterate the aneurysm and was brought to the operating theater for clipping. The aneurysmal neck was easily exposed after left frontal craniotomy and subsequent microscopic dissection between the left frontal lobe and falx cerebri. The falx was not excised, and we decided not to dissect the aneurysmal dome fully [Figure 2a] to shorten operation time, considering his suboptimal cardiac function. Two long titanium Sugita aneurysm clips (40 and 35 mm) were applied in a parallel manner to the aneurysmal neck [Figure 2a];

**Joji Inamasu,
Shunsuke Nakae,
Yoko Kato,
Yuichi Hirose**

*Department of Neurosurgery,
Fujita Health University
Hospital, Toyoake, Japan*

Address for correspondence:

*Dr. Joji Inamasu,
Department of Neurosurgery,
Fujita Health University
Hospital, 1-98 Kutsukake,
Toyoake 458-0831, Japan.
E-mail: inamasu@fujita-hu.ac.jp*

Access this article online

Website: www.asianjns.org

DOI: 10.4103/ajns.AJNS_213_16

Quick Response Code:



How to cite this article: Inamasu J, Nakae S, Kato Y, Hirose Y. Temporary worsening of perianeurysmal edema following clipping of a partially thrombosed giant pericallosal artery aneurysm. *Asian J Neurosurg* 2018;13:779-81.

This is an open access journal, and articles are distributed under the terms of the Creative Commons Attribution-NonCommercial-ShareAlike 4.0 License, which allows others to remix, tweak, and build upon the work non-commercially, as long as appropriate credit is given and the new creations are licensed under the identical terms.

For reprints contact: reprints@medknow.com

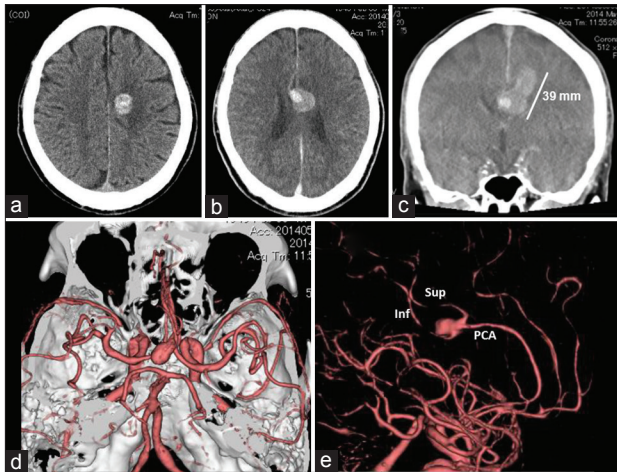


Figure 1: Computed tomography of the brain. An initial nonenhanced computed tomography showing a high-density mass in the left frontal lobe (a). Contrast-enhanced computed tomography showing strong enhancement inside the mass (b). Coronally reconstructed image showing the partially thrombosed aneurysm with maximum length of 39 mm (c). Three-dimensional computed tomography angiography showing the aneurysm located at the bifurcation of the left pericallosal artery (d and e)

patency of the left pericallosal artery and its two branches was confirmed on intraoperative indocyanine green videoangiography.^[9] The patient woke up from anesthesia with mild right-sided hemiparesis, which progressed to hemiplegia by 12 h after surgery. Brain CT obtained 6 h postoperatively showed a low-density area surrounding the aneurysm [Figure 3b]. Although we intended to rule out any ischemic complications by magnetic resonance imaging (MRI), radiologists at our institution advised against it for fear of iatrogenic burn injury as the patient had extensive tattoo over his body. Subsequent 3D-CTA revealed that the left pericallosal artery and its two branches were patent, and the aneurysm was completely obliterated [Figure 2b]. Therefore, we concluded that the low-density area around the aneurysm [Figure 3b] was due to worsening of perianeurysmal edema and not due to brain ischemia. Fortunately, his symptoms began to improve 2 days after surgery and disappeared completely by 2 weeks after surgery. Brain CT obtained 3 weeks after surgery showed disappearance of the perianeurysmal edema [Figure 3c]. The chronological change in the degree of perianeurysmal edema was summarized in Figure 3. He was discharged free of symptoms a month after surgery. Consent for publication of this report was obtained from the patient.

Discussion

Perianeurysmal edema is not uncommon in patients with giant intracranial aneurysms: In a recent observational study, perianeurysmal edema was observed in 33% of these patients.^[10] Further, partial thrombosis of aneurysm was found to be associated with perianeurysmal edema.^[10] Although the cause of perianeurysmal edema is not completely understood, release of inflammatory cytokines and metabolites from the thrombosed parts of the

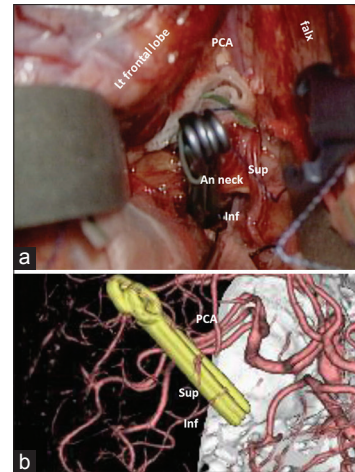


Figure 2: Intraoperative photograph after clipping showing relationship between the aneurysm, left pericallosal artery, and its two branches (superior and inferior). While the aneurysmal neck was exposed by microscopic dissection, aneurysmal dome remained covered with the overlying brain (a). Three-dimensional computed tomography angiography performed the day after surgery showing patent left pericallosal artery and its branches and obliterated aneurysm (b)

giant aneurysm into the neighboring brain parenchyma is implicated in its causation.^[10,11]

Reports of treatment-related perianeurysmal edema have been steadily increasing as more giant intracranial aneurysms are treated using endovascular techniques.^[3-8] Embolic materials with a potential of eliciting inflammation, such as hydrocoils, seem to be more frequently associated with perianeurysmal edema than bare metal coils.^[7] However, development or worsening of perianeurysmal edema after clipping has rarely been reported: A literature search on MEDLINE/PubMed using keywords such as perianeurysmal edema and clipping did not retrieve any articles. The worsening of perianeurysmal edema in the present case may have been elicited by inflammatory cytokines, such as tumor necrosis factor- α and transforming growth factor- β , which are released from the ischemic aneurysm wall due to disruption of blood supply to the vasa vasorum by clips.^[8,11] Technically, placement of aneurysm clips to a partially thrombosed giant aneurysm is usually preceded by circumferential dissection at the interface between the aneurysmal dome and surrounding brain and followed by thrombectomy. The space created between the aneurysmal dome and surrounding brain may serve to dilute the inflammatory cytokines, which may explain why most patients with partially thrombosed giant aneurysm do not develop perianeurysmal edema after clipping. In contrast, only the aneurysmal neck (but not the aneurysmal dome) was dissected and exposed in the present case. Due to the close contact between the aneurysmal dome and surrounding brain, worsening of perianeurysmal edema may have occurred after clipping.

There are several limitations in the present study. First, perianeurysmal edema may have been better evaluated with MRI,^[12] which was not performed owing to

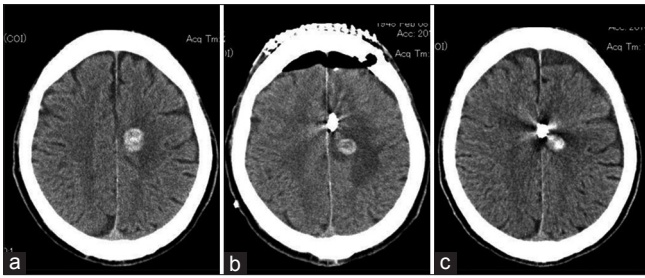


Figure 3: The chronological change in perianeurysmal edema. (a) Before surgery, (b) 12 h after surgery, (c) 3 weeks after surgery

extensive skin tattoos of the patient. However, according to the literature, MRI seems to be safely performed in patients with tattoos.^[13] Second, we did not measure the concentrations of inflammatory cytokines either in the blood or cerebrospinal fluid. Finally, a bilateral frontal craniotomy together with resection of the falx cerebri may have provided a wider surgical field and better exposure of the aneurysm,^[14] thus preventing postoperative perianeurysmal edema. We were concerned about his poor cardiac function; therefore, we performed a relatively small craniotomy and surgical exposure with the hope to shorten operation time.

Conclusion

The worsening of perianeurysmal edema in the present case may have been due to release of inflammatory cytokines from aneurysm wall, which was rendered ischemic after obliteration of the vasa vasorum by aneurysm clips. Our experience that perioperative edema may develop or worsen after clipping when the interface between the aneurysmal dome and the surrounding brain is not circumferentially dissected may be of some value to vascular neurosurgeons who treat partially thrombosed giant aneurysms.

Acknowledgment

The corresponding author (Joji Inamasu) received a medical research grant on traffic accident from the General Insurance Association of Japan.

Financial support and sponsorship

The corresponding author (Joji Inamasu) received a medical research grant on traffic accident from the General Insurance Association of Japan.

Conflicts of interest

There are no conflicts of interest.

References

- Inamasu J, Suga S, Sato S, Onozuka S, Kawase T. Long-term outcome of 17 cases of large-giant posterior fossa aneurysm. *Clin Neurol Neurosurg* 2000;102:65-71.
- Sano H, Kato Y, Shankar K, Kanaoka N, Hayakawa M, Katada K, *et al.* Treatment and results of partially thrombosed giant aneurysms. *Neurol Med Chir (Tokyo)* 1998;38 Suppl:58-61.
- Berge J, Tourdias T, Moreau JF, Barreau X, Dousset V. Perianeurysmal brain inflammation after flow-diversion treatment. *AJNR Am J Neuroradiol* 2011;32:1930-4.
- Horie N, Kitagawa N, Morikawa M, Tsutsumi K, Kaminogo M, Nagata I. Progressive perianeurysmal edema induced after endovascular coil embolization. Report of three cases and review of the literature. *J Neurosurg* 2007;106:916-20.
- Sim KJ, Yan B, Dowling RJ, Mitchell PJ. Intracranial aneurysms with perianeurysmal edema: Long-term outcomes post-endovascular treatment. *J Neuroradiol* 2015;42:72-9.
- Lukic S, Jankovic S, Popovic KS, Bankovic D, Popovic P, Mijailovic M. Analysis of risk factors for perifocal oedema after endovascular embolization of unruptured intracranial arterial aneurysms. *Radiol Oncol* 2015;49:341-6.
- White JB, Cloft HJ, Kallmes DF. But did you use HydroCoil? Perianeurysmal edema and hydrocephalus with bare platinum coils. *AJNR Am J Neuroradiol* 2008;29:299-300.
- Iihara K, Murao K, Sakai N, Soeda A, Ishibashi-Ueda H, Yutani C, *et al.* Continued growth of and increased symptoms from a thrombosed giant aneurysm of the vertebral artery after complete endovascular occlusion and trapping: The role of vasa vasorum. Case report. *J Neurosurg* 2003;98:407-13.
- Balamurugan S, Agrawal A, Kato Y, Sano H. Intra operative indocyanine green video-angiography in cerebrovascular surgery: An overview with review of literature. *Asian J Neurosurg* 2011;6:88-93.
- Dengler J, Maldaner N, Bijlenga P, Burkhardt JK, Graewe A, Guhl S, *et al.* Perianeurysmal edema in giant intracranial aneurysms in relation to aneurysm location, size, and partial thrombosis. *J Neurosurg* 2015;123:446-52.
- Umopathy SN, Kaczmarek E, Fatteh N, Burns N, Lucas R, Stenmark KR, *et al.* Adenosine A1 receptors promote vasa vasorum endothelial cell barrier integrity via Gi and Akt-dependent actin cytoskeleton remodeling. *PLoS One* 2013;8:e59733.
- Wostrack M, Mielke D, Kato N, Guhl S, Schmidt NO, Maldaner N, *et al.* Interobserver variability in the characterization of giant intracranial aneurysms with special emphasis on aneurysm diameter and shape. *Acta Neurochir (Wien)* 2015;157:1859-65.
- Tope WD, Shellock FG. Magnetic resonance imaging and permanent cosmetics (tattoos): Survey of complications and adverse events. *J Magn Reson Imaging* 2002;15:180-4.
- Baldawa S, Katikar D, Marda S. Giant saccular distal azygos artery aneurysm: Report of a case and review of literature. *Asian J Neurosurg* 2016;11:175.