

Collision Tumors: A Rare Case Report

Abstract

The presence of collision tumors without any evidence of phacomatoses, genetic syndromes, or any history of previous radiation to the brain is extremely rare. We report a case with two diverse primaries, a tentorial meningioma and a colloid cyst found in the same patient occurring in the absence of these conditions. To the best of our knowledge, a single case of a colloid cyst and meningioma found together in the same patient has been reported till date. In such cases, the surgical dilemma as to which tumor to operate first has been addressed in our case report.

Keywords: Collision tumors, colloid cyst, meningioma

Introduction

The incidence of multiple primary brain tumours with different histological types in the same patient is as little as 0.3% of all brain tumours. A lady presented to us with two diverse primaries, a tentorial meningioma and a colloid cyst which were seen away from each other on her scans. She had no evidence of any phacomatoses, genetic syndrome or any history of previous radiation to the brain. Here, the dilemma facing us was- which tumour is to be operated first?. As the lesion causing the main neurological symptom was the meningioma, it was dealt with first and the colloid cyst was operated later.

Case Report

A 48-year-old female, an operated case of abdominal hysterectomy in view of fibroid uterus with hemorrhagic ovarian cyst 2 weeks ago, was admitted with chief complaints of two episodes of generalised tonic clonic seizures (GTCS) 2 weeks ago followed by loss of consciousness and sudden onset diminution of vision in both the eyes. The neurological examination was normal, and the patient was able to count fingers close to the face. Radiological investigations revealed a colloid cyst [Figures 1 and 2] in the region of foramen of Monroe and a meningioma measuring 3 cm × 2.7 cm × 3.1 cm involving the tentorium cerebelli on the right side, with

its superior lobe in the right occipital region and inferior lobe in the right cerebellar region with mild surrounding edema [Figures 3-5]. In lieu of the mass effect caused by the meningioma, the patient first underwent a midline suboccipital craniotomy with Grade 1 excision of the meningioma in a sitting position, and a month later, the colloid cyst was operated by minimal access small craniotomy interhemispheric transcallosal transchoroidal approach [Figures 6 and 7]. Histopathology was consistent with a meningioma and a colloid cyst. Her vision improved, and the postoperative recovery was uneventful.

Discussion

Meningiomas are the most common extra-axial neoplasms and the second-most common primary tumors of the central nervous system, accounting for 24%–30% of all brain tumors.^[1,2]

Tentorial meningiomas are relatively uncommon tumors, representing about 5% of intracranial meningiomas. Approximately 70%–80% of cases occur in women. Tentorial meningiomas are notorious in their location and are considered a neurosurgical challenge because of their critical location adjacent to vital neurovascular structures and the brain stem.

Colloid cysts qualify as nonneoplastic true epithelium lined cysts of the central neuraxis. They generally present in the

**Vernon Velho,
Nidhisha
Sadhvani¹,
Anuj Bhide**

Departments of Neurosurgery and ¹General Surgery, Grant Government Medical College and Sir J.J. Group of Hospitals, Mumbai, Maharashtra, India

Address for correspondence:

*Dr. Nidhisha Sadhwani,
Department of Neurosurgery,
Grant Government Medical
College and Sir JJ Hospitals,
Byculla, Mumbai - 400 008,
Maharashtra, India.
E-mail: sadhwani.nidhisha@gmail.com*

Access this article online

Website: www.asianjns.org

DOI: 10.4103/ajns.AJNS_219_19

Quick Response Code:



How to cite this article: Velho V, Sadhwani N, Bhide A. Collision tumors: A rare case report. Asian J Neurosurg 2020;15:741-4.

Submitted: 13-Jul-2019

Revised: 14-Sep-2019

Accepted: 20-Feb-2020

Published: 28-Aug-2020

This is an open access journal, and articles are distributed under the terms of the Creative Commons Attribution-NonCommercial-ShareAlike 4.0 License, which allows others to remix, tweak, and build upon the work non-commercially, as long as appropriate credit is given and the new creations are licensed under the identical terms.

For reprints contact: WKHLRPMedknow_reprints@wolterskluwer.com

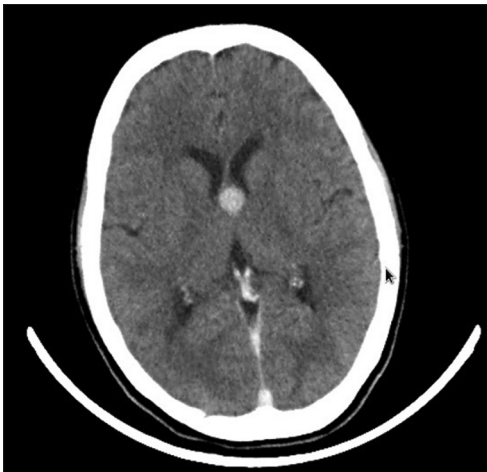

Figure 1: Preoperative axial computed tomography showing colloid cyst

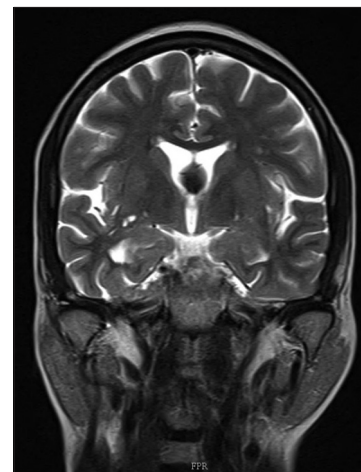


Figure 2: Coronal T2 magnetic resonance imaging showing colloid cyst

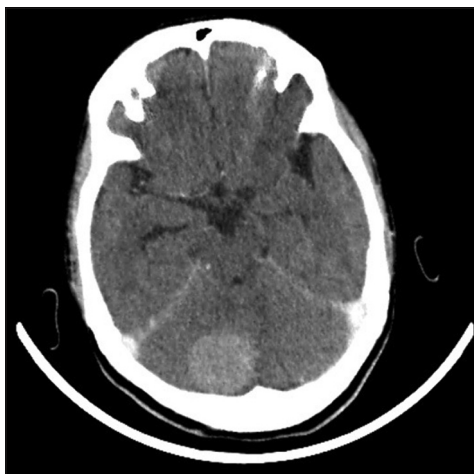

Figure 3: Preoperative axial computed tomography showing meningioma

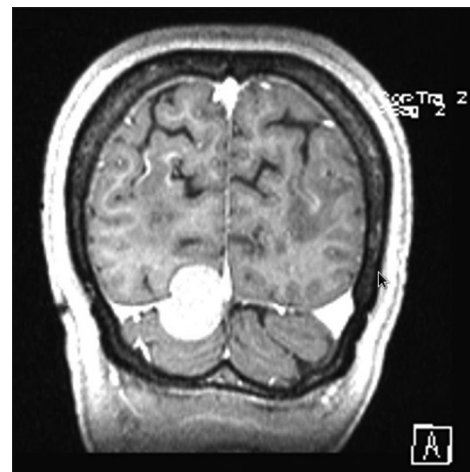

Figure 4: Coronal T2 magnetic resonance imaging showing tentorial meningioma with supratentorial and infratentorial meningioma

third-fifth decade, but they can present at both extremes of ages. Cyst size can range from 3 to 40 mm, but size may not be a reliable predictor of outcome as even small cysts may cause sudden death due to acute obstructing hydrocephalus or hypothalamic arrhythmias. They generally present with manifestations of ventricular outflow obstruction. The primary presenting complaint is headache. Associated symptoms include vertigo, memory deficit, diplopia, and behavioral disturbances.

The incidence of multiple primary brain tumors with different histological types in the same patient is only 0.3% of all brain tumors^[3] or 10–15 cases/100,000 who develop primary brain tumors.^[4] The simultaneous occurrence of multiple intracranial tumors is observed in phacomatoses, genetic syndromes, or after radiation exposure to the brain. The occurrence of multiple different intracranial tumors in the absence of these conditions is rather rare. The most frequently reported combination of histologically different brain tumors is meningioma and glioma.

We report a case with two diverse primaries, a tentorial meningioma, and a colloid cyst found far away from

each other in the same patient without any evidence of phacomatoses, genetic syndromes, or any history of previous radiation to the brain.

To the best of our knowledge, this is the second case reported.^[5]

Several hypothesis have been proposed to link the occurrence of two or more intracranial tumors of diverse germinal origin in the same individual, but none have gained conclusive support.^[6-8]

By chance or by other aetiologies, meningiomas have the potential to be associated with numerous other lesions in the brain and are the tumor type most often found in multiple intracranial tumors of different histology. This is both due to their frequent incidental occurrence even as isolated intracranial tumors and their long clinical evolution before diagnosis. Thus, they have an increased probability of simultaneously harboring another primary or secondary intracranial tumor.^[9-11]

The hypothesis that one tumor acts as an irritating factor for the other does not hold true in our case, as the tumors

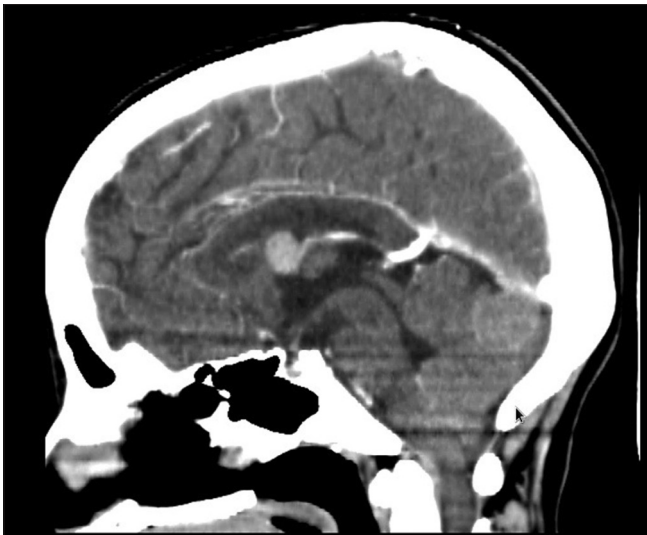


Figure 5: Sagittal computed tomography showing colloid cyst and meningioma

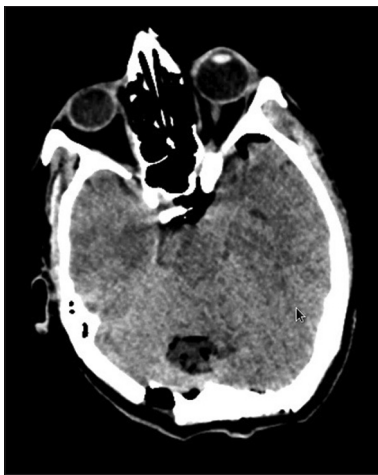

Figure 6: Postoperative computed tomography following excision of meningioma

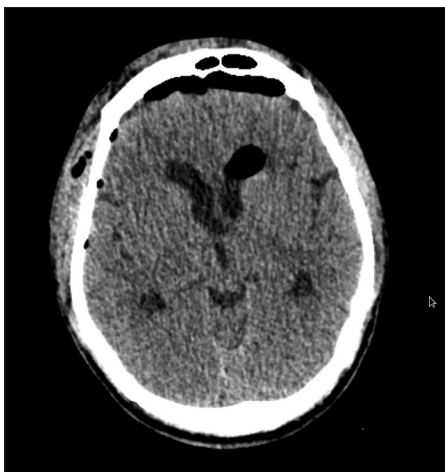

Figure 7: Postoperative computed tomography following excision of colloid cyst

are nonadjacent. This pattern of tumoral association most likely represents a coincidental event rather than the

result of a common pathway abnormality. Some remote inciting molecular or genetic agent causing a synchronous meningioma and a colloid cyst is still a possibility as immunohistochemistry, and molecular study was not done due to rule the same out at our institute due to financial constraints. Advanced molecular genetic techniques will be required in the future with emphasis over the importance of cell biology to understand this phenomenon of coexistence we observe in the given clinical scenario.

Thus by exclusion, the possible explanations pertaining to our case are:^[12]

1. Entirely coincidental development of the tumors
2. The initial tumor acts as a stimulus on the surrounding cerebral parenchyma or meningeal tissue to induce a new tumor at a different site
3. A common carcinogenic agent developing tumors at different sites simultaneously
4. A residual embryonic structure leading to subsequent multiple tumors.

The management priority for two tumors located far apart needs a case-by-case evaluation. An important aspect while dealing with such cases is to decide which tumor needs to be operated first or whether both the lesions can be operated in the same sitting. A simultaneous benign asymptomatic/deep-seated/a complex brain lesion which may require a more radical procedure for resection and place vital structures at risk during treatment is not worthwhile a surgical resection and can be observed. Conservative management of a benign brain lesion is thus an option.

In our case, we used a two-staged approach where the meningioma was operated first due to its larger size and the mass effect and the colloid cyst was operated a month later by minimal access small craniotomy interhemispheric transcalsal transchoroidal approach as it was symptomatic, easily accessible by surgery and large enough in size to warrant surgical decompression. The standpoint being that the lesion causing the main neurological symptom should be operated first, be it the meningioma or the colloid cyst. Both the tumors could not be operated in the same sitting as the surgical approaches to them were different.

Conclusion

In case of multiple brain tumors, the management priority needs case by case evaluation. The standpoint being that the lesion causing the main neurological symptom should be operated first. Clinicians should be aware of the possibility of finding a colloid cyst with a meningioma as otherwise, missing it would be catastrophic.

Declaration of patient consent

The authors certify that they have obtained all appropriate patient consent forms. In the form the patient(s) has/have given his/her/their consent for his/her/their images and

other clinical information to be reported in the journal. The patients understand that their names and initials will not be published and due efforts will be made to conceal their identity, but anonymity cannot be guaranteed.

Financial support and sponsorship

Nil.

Conflicts of interest

There are no conflicts of interest.

References

1. Louis DN, Ohgaki H, Wiestler OD, Cavenee WK, Burger PC, Jouvet A, *et al.* The 2007 WHO classification of tumours of the central nervous system. *Acta Neuropathol* 2007;114:97-109.
2. Riemenschneider MJ, Perry A, Reifenberger G. Histological classification and molecular genetics of meningiomas. *Lancet Neurol* 2006;5:1045-54.
3. Nomura K. Analysis of therapeutic factors related to survival rate for malignant glioma patients – Report from brain tumor registry in Japan, Vol. 6, 1987. *Gan No Rinsho* 1989;35:1219-25.
4. Lee EJ, Chang CH, Wang LC, Hung YC, Chen HH. Two primary brain tumors, meningioma and glioblastoma multiforme, in opposite hemispheres of the same patient. *J Clin Neurosci* 2002;9:589-91.
5. Li YL, Kwok SK, Shiu KC. Colloid cyst and multiple meningiomata in gorlin syndrome. *J Clin Neurosci* 2018;47:157-9.
6. Davis GA, Fabinyi GC, Kalnins RM, Brazenor GA, Rogers MA. Con – Current adjacent meningioma and astrocytoma: A report of three cases and review of the literature. *Neurosurgery* 1995;36:599-605.
7. Fox JL. Meningioma and associated lesions. In: Al-Mefty O, editor. *Meningioma*. New York: Raven Press; 1991. p. 129-36.
8. Spallone A, Santoro A, Palatinsky E, Giunta F. Intracranial meningiomas associated with glial tumours: A review based on 54 selected literature cases from the literature and 3 additional personal cases. *Acta Neurochir (Wien)* 1991;110:133-9.
9. Schoenberg BS. Multiple primary neoplasms and the nervous system. *Cancer* 1977;40:1961-7.
10. Domenicucci M, Artico M, Nucci F, Salvati M, Ferrante L. Meningioma following high-dose radiation therapy. Case report and review of the literature. *Clin Neurol Neurosurg* 1990;92:349-52.
11. Zuccarello M, Sawaya R, deCourten-Meyers G. Glioblastoma occurring after radiation therapy for meningioma: Case report and review of literature. *Neurosurgery* 1986;19:114-9.
12. Tokunaga T, Shigemori M, Hirohata M, Sugita Y, Miyagi J, Kuramoto S. Multiple primary brain tumors of different histological types – Report of two cases. *Neurol Med Chir (Tokyo)* 1991;31:141-5.