

Superficial Temporal Artery: Middle Cerebral Artery Bypass, Our Series of 20 Cases, Surgical Technique and Indications with Illustrative Cases

Abstract

The first extracranial-intracranial (EC-IC) bypass surgery was performed by professor Yasargil in 1967 since then this procedure has been widely used in vascular neurosurgery and sometimes, in tumors excision when a vascular sacrifice is necessary. In this article, we will illustrate the surgical technique of the superficial temporal artery-middle cerebral artery (STA-MCA) bypass with two cases; a 59-year-old male and 64-year-old female who presented with an occlusion of the MCA. The male presented also with a posterior communicating artery-IC aneurysm which was clipped in the same sitting. We also studied in this paper a series of 20 patients operated in Banbuntane Hotokukai Hospital, Fujita Health University, for which a low-flow STA-MCA anastomosis was done for steno-occlusive disease or moyamoya disease. In Banbuntane Hotokukai Hospital, Fujita Health University, 20 patients were operated since 2015, 12 patients were male. Five patients presented with moyamoya disease, while 15 patients presented with vascular steno-occlusive disease. The steno-occlusion was found in internal carotid artery in nine patients. The patients were divided into two categories (steno-occlusive disease and moyamoya). STA-MCA bypass is now one of the basic techniques to master in vascular neurosurgery. It requires to perform the anastomosis correctly within the permissible time. The goal is to have a long-term patency for the anastomosed vessel.

Keywords: Low flow bypass, moyamoya disease, steno-occlusive cerebrovascular disease, stroke, superficial temporal artery-middle cerebral artery bypass

Introduction

The superficial temporal artery-middle cerebral artery (STA-MCA) bypass was introduced by professor Yasargil in the late 60s^[1,2] since then this technique has been widely used in neurosurgery. Considered as the basic bypass^[3] to perform a low-flow revascularization in neurosurgery, this technique provides a blood flow augmentation^[1] to the anterior circulation of the brain from the external carotid artery. It was modified and developed during these last decades depending on the case and the indication.

First, it was performed for ischemic lesions,^[4-6] but actually, this technique must be mastered not only for the treatment of steno-occlusive disease and moyamoya but also for aneurysms surgery when the preservation of the parent vessel is impossible without sacrifice and also for treatment of skull base tumors when a vascular sacrifice is needed.^[3]

This is an open access journal, and articles are distributed under the terms of the Creative Commons Attribution-NonCommercial-ShareAlike 4.0 License, which allows others to remix, tweak, and build upon the work non-commercially, as long as appropriate credit is given and the new creations are licensed under the identical terms.

For reprints contact: reprints@medknow.com

The surgical technique depends on the surgeon and the case, it can be performed in one bypass directly from STA as a donor vessel to a branch of MCA as a recipient vessel, or it may require interposition of a venous graft to perform double-stage bypass when the length of STA is not sufficient. The most important aspect is to perform a complete revascularization in the permissible time.

Patients and Methods

In this article, we review a series of 20 patients who underwent a low-flow STA-MCA bypass surgery during 3 years in Fujita Health University, Banbutane Hotokukai Hospital (from March 2015 to August 2018).

All the data were provided by the senior author.

Patients were evaluated preoperatively using computed tomography (CT)-Perfusion to establish a better analysis of cerebral

How to cite this article: Cheikh A, Yasuhiro Y, Kasinathan S, Kawase T, Takao T, Kato Y. Superficial temporal artery: Middle cerebral artery bypass, our series of 20 cases, surgical technique and indications with illustrative cases. Asian J Neurosurg 2019;14:670-7.

**Abderrahmane Cheikh,
Yamada Yasuhiro,
Sudhakar Kasinathan¹,
Tsukasa Kawase,
Teranishi Takao,
Yoko Kato²**

Department of Neurosurgery, Ali Ait Idir Hospital and Medical School of Algiers, Algiers University, Algeria, ²Department of Neurosurgery, Banbutane Hotokukai Hospital, Fujita Health University, Toyoake, Nagoya, Aichi Prefecture, Japan, ¹Department of Neurosurgery, Institute of Neurosurgery, Madras Medical College and Rajiv Gandhi Government General Hospital, Chennai, Tamil Nadu, India

Address for correspondence:
Dr. Abderrahmane Cheikh,
Ali Ait Idir Teaching Hospital,
Bd Abderrezak Hahad,
La Casbah, Algiers, Algeria.
E-mail: doc.cheikh@gmail.com

Access this article online

Website: www.asianjns.org

DOI: 10.4103/ajns.AJNS_220_18

Quick Response Code:



blood flow (CBF) for patients who were candidates for bypass revascularization surgery.

Surgical technique

To describe the surgical technique, we will illustrate with two cases operated in August 2018 for which an STA-MCA bypass was done.

Illustrative case 1

A 59 years old, male with diabetes and hypertension, presents with a left MCA stenosis diagnosed 1 month ago after a stroke, with an associated internal carotid artery - Posterior communicating artery (IC-PCom) aneurysm. The preoperative radiological study was done before the surgery [Figure 1].

The patient was supinely positioned, the head rotated to the contralateral side in slight extension. STA was mapped using a Doppler probe. Frontotemporal curvilinear incision was done [Figure 2a].

STA was identified in an early stage of surgery, dissected in all its length from adjacent soft tissue carefully: it should be preserved to not be damaged [Figure 2b].

The temporal muscle was divided under the STA, dissected and retracted inferiorly to expose the frontotemporal area and perform a frontotemporal bone flap [Figure 2c].

After performing the craniotomy, the dura was incised circumferentially to the pterion.

In this case, the patient presented an IC-PC aneurysm, we first started by clipping the aneurysm, a distal transsylvian approach was performed to avoid brain retraction, the Sylvian fissure was widely opened, all the surrounding veins were preserved,

the aneurysm was exposed, dissected, and clipped [Figure 3]. Dual-image video-angiography (DIVA) was performed before and after clipping [Figure 3b]. Endoscopy was also used intraoperatively before and after clipping to allow exposure of the hidden parts of the aneurysm with surrounding vessels, and to check the position of the clip [Figure 3].

The second step of the surgery was the anastomosis. Cortical branches of the MCA exiting from the Sylvian fissure were identified, we chose an M4 segment as recipient vessel (depending on this vessels diameter) [Figure 4a]. The arachnoid surrounding this cortical vessel was widely dissected, and its small cortical branches were coagulated and cut to allow its mobilization.

The STA was prepared as a donor vessel, an appropriate length was calculated [Figure 4b], after putting a temporary clip in the emergence of the STA, the artery was cut (the artery should not be too short as this will cause an avulsion, or too long as this will cause twisting, and further thrombosis).^[7] The surrounding adjacent soft tissue was removed from the temporal artery on its last 10 mm [Figure 4c]. The extremity was prepared as a fish mouth and marked with ethylene blue (to facilitate its identification in the operative field) [Figure 4d]. Heparin was injected into the STA. Gelfoam was used in both working areas (STA and MCA preparation).

DIVA was done, then the recipient vessel was trapped into two temporary clips, the arteriotomy was also marked with ethylene blue [Figure 5].

We used 10-0 sutures, first, we started at the donor vessel in both borders of the fish mouth [Figure 6], after that the

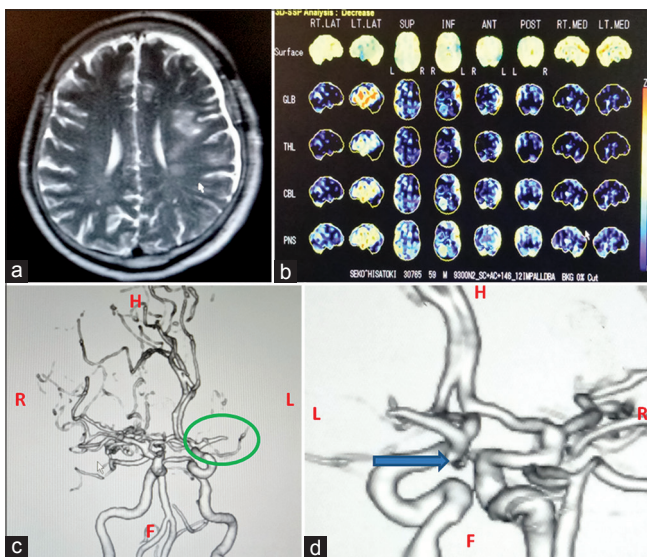


Figure 1: Preoperative imaging of the first case (a) magnetic resonance imaging showing a stroke in the territory of left middle cerebral artery. (b) Brain three-dimensional stereotactic surface projection spectrum analysis allowing cerebral blood flow study. (c) preoperative angio-computed tomography showing left middle cerebral artery stenosis (encircled). (d) arrow showing an intracranial-posterior communicating artery aneurysm

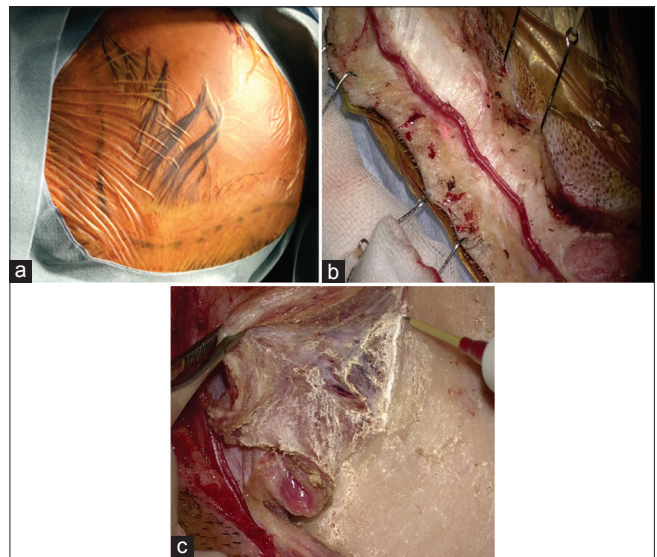


Figure 2: Step 1: Incision and dissection of soft-tissue allowing exposure of the superficial temporal artery and the frontotemporal area (a) a frontotemporal curvilinear incision. (b) superficial temporal artery exposed, harvested and preserved in the early stage of surgery. (c) Temporal muscle being dissected to expose the frontotemporal area to perform a frontotemporal bone flap

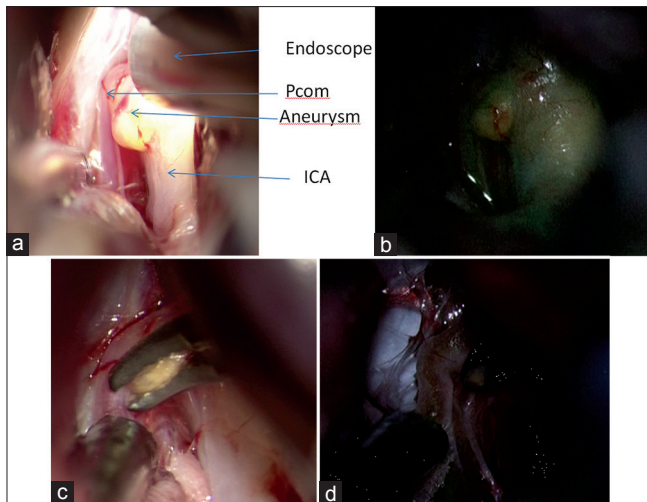


Figure 3: Aneurysm being clipped (a) exposure of the aneurysm through a transylvian approach, here we are exploring the surrounding anatomy by endoscope. (b) preclipping DIVA is done. (c) Clipping of the aneurysm. (d) postclipping DIVA showing a total exclusion of the aneurysm, good flow in probabilistic internal carotid artery and internal carotid artery

arteriotomy was performed, then both sutures are done either placed in both ends of the arteriotomy to start the anastomosis between the STA and the MCA.

Noncontinuous sutures are done, first in the proximal wall of the arteriotomy [Figure 7], then in the opposite wall [Figure 8].

The temporary clip on the STA is replaced in the distal end, and then we proceed to the removal of temporary clips one by one: first, the proximal temporary clip on the MCA was removed; second, we removed the distal clip on MCA; finally, the temporary clip on the STA was released allowing the verification of the patency of the anastomosis. DIVA was done it showed a good filling of blood through the anastomosis [Figure 9].

Finally, we verified the flow with a Doppler probe.

The dural closure is also an important step, usually we use the temporal muscle to ensure a good closure allowing a safety entrance of the STA without any compression [Figure 10].

Illustrative case 2

A 59-year-old female, without medical history, presents with a left MCA stenosis diagnosed 1 month ago after an episode of stroke, and confirmed by three-dimensional CT angiography [Figure 11].

The position and the skin incision are similar to those in the first case (as described above).

The exposure and dissection of STA was done carefully, in this case, both branches were exposed [Figure 12].

After bone flap removal and dura opening, we selected a branch of MCA as a recipient vessel in the cortical

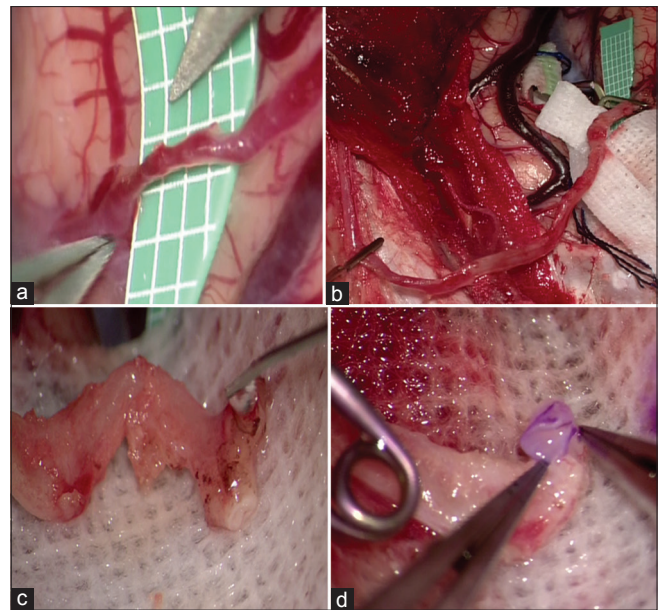


Figure 4: Preparation of the recipient and the donor vessels (a) the recipient vessel is identified prepared dissected from surrounding arachnoid. (b) the length of the donor vessel (superficial temporal artery) is calculated. (c) the extremity of the superficial temporal artery is cut like a fish mouth, heparin is injected. (d) The fish mouth is marked with methylene blue

brain, of which the diameter permitted to perform the anastomosis. This chosen vessel was dissected from adjacent arachnoid [Figure 13b].

DIVA was done first before starting the anastomosis [Figure 13c].

Frontal branch of STA was prepared as a donor vessel, clipped in its proximal and distal part using a temporary clip after calculating the ideal length. Its extremity was cut as a fish mouth and dissected in its last 10 mm from adjacent tissue, after that we marked it with methylene blue [Figure 13a]. Two 10-0 nonabsorbable sutures were placed in each extremity of the mouth fish [Figure 13d].

The recipient vessel was trapped between two temporary clips, a sufficient length for arteriotomy was marked with methylene blue, and then the arteriotomy was done [Figure 13d].

First, the anastomosis started in both corners, after that noncontinuous sutures using 10-0 sutures were done side by side. We verified at the end of the flow with DIVA [Figure 14].

Dural closure started from the front then the temporal side, using a pedicle layer of temporal muscle allowing a safe entrance of STA without compression.

Results

Twelve (60%) patients were male and 8 (40%) females with a mean age of 57 years. Nine (45%) patients presented with an ICA steno-occlusive pathology, 6 patients (30%) MCA

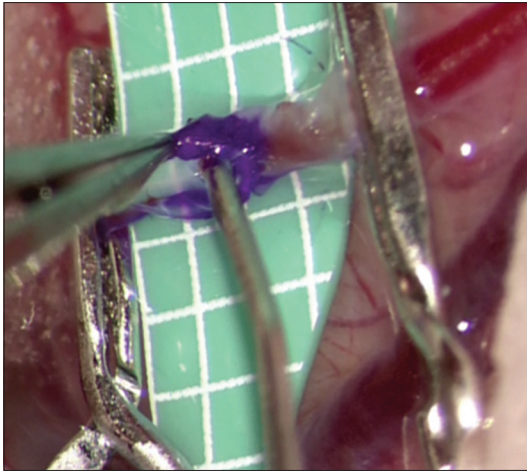


Figure 5: Arteriotomy is done after trapping of the recipient vessel between two clips

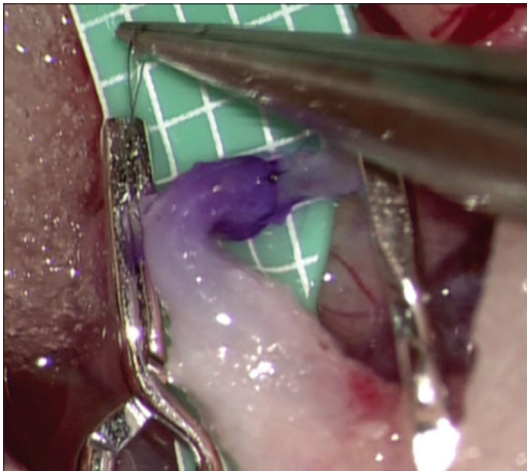


Figure 7: Anastomosis starts at extremities

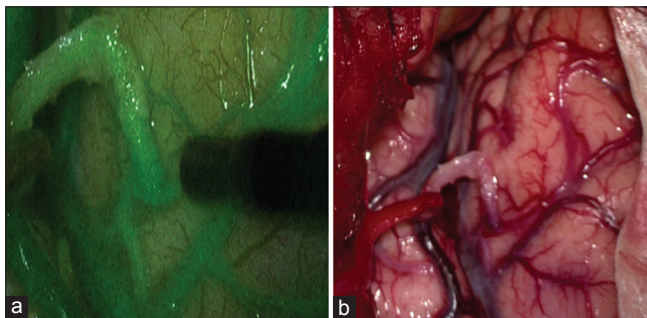


Figure 9: At the end of surgery, dual-image videoangiography is done (a) and we proceed to verification of the flow from the superficial temporal artery to middle cerebral artery with Doppler probe. (b) operative view showing the anastomosis between superficial temporal artery and middle cerebral artery

steno-occlusive disease, and 5 patients (25%) presented with moyamoya disease. Twelve bypasses (60%) were performed at the left side and for 8 (40%) in the right side. Bypass surgery was performed in all cases by an experienced bypass surgeon. In all cases, occlusion time does not exceed 25 min.

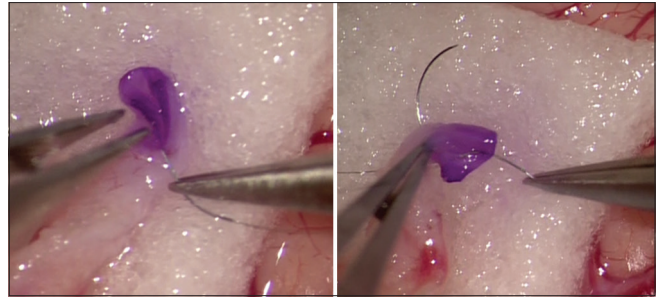


Figure 6: Two 10-0 sutures are applied in the heel and the toe of the superficial temporal artery

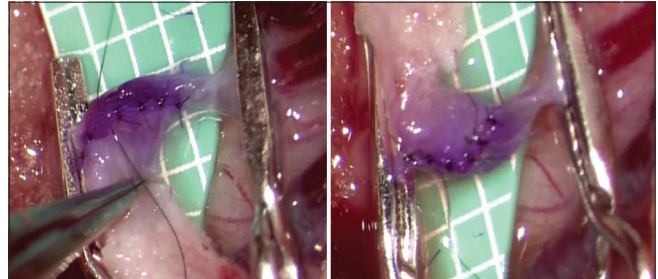


Figure 8: We proceed to sutures side by side with discontinuous nodes

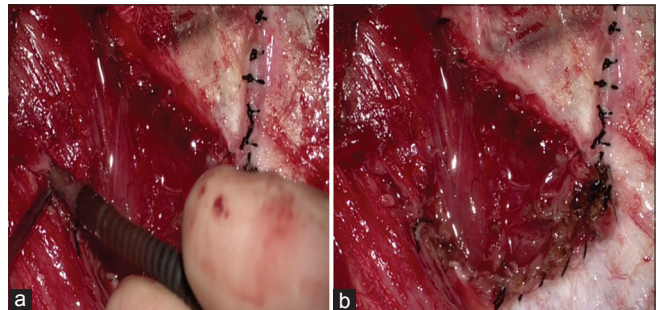


Figure 10: The closure is an important step (a) verification of superficial temporal artery with a Doppler probe. (b) the closure use a layer of temporalis muscle to allow a safety entrance of superficial temporal artery into the operative field

We divided these patients into two groups according to their pathologies for a better study. The results are reported in Table 1.

1-moyamoya disease

Five patients (25%) presented with moyamoya disease. Two were male (40%) and three were female (60%). Age ranges from 6 to 71 years old. The mean age was 37. Only one patient underwent surgery from the right side. Three patients (60%) of the five had already been operated before on the contralateral side.

2-steno-occlusive disease

Fifteen patients (75%) presented with a steno-occlusive disease. Ten males (66%) and 5 females. Age ranges from 16 to 78 with a mean age of 60 years old. Nine (45%) of these patients presented with a steno-occlusive disease of the ICA, while 6 (30%) of them were in MCA.

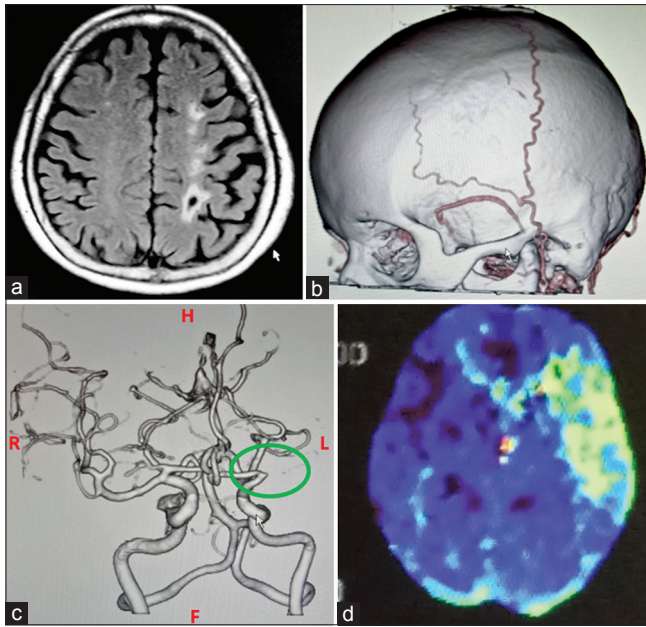


Figure 11: Preoperative imaging of the second case (a) magnetic resonance imaging showing a stroke in the territory of the left middle cerebral artery. (b) computed tomography angiography showing the superficial temporal artery for a better study before surgery. (c) computed tomography angiography showing left middle cerebral artery occlusion (middle cerebral artery Encircled) (d) Pre operative CBF Study

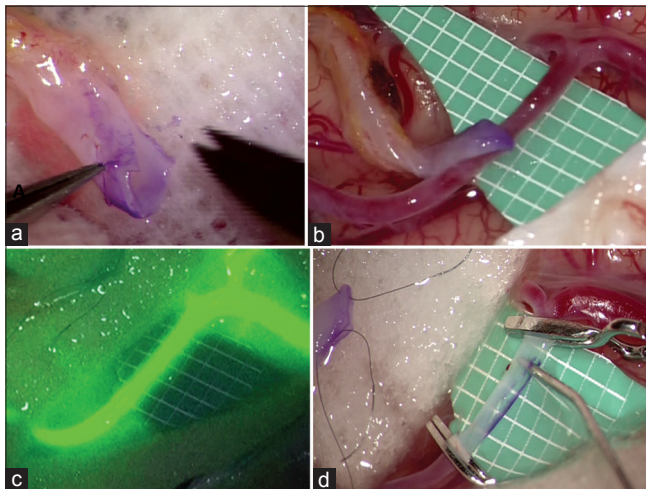


Figure 13: Preparation of both donor and recipient vessel (a) preparation of superficial temporal artery its extremity cut like a fish mouth, and the last 10 mm dissected from adjacent tissue. (b) calculating of sufficient length of superficial temporal artery. (c) dual-image videoangiography is done before bypass to verify feeling in the recipient vessel. (d) M4 segment trapped between two clips arteriotomy done and heparin injected, two 10-0 sutures applied in both extremities of mouth fish of superficial temporal artery

Glasgow outcome scale (GOS) was excellent for all patients in our series, GOS was at five for all patients.

Four patients presented with complications, three chronic subdural hematoma (CSDH), and two patients presented with wound infection (one of these two patients had CSDH).

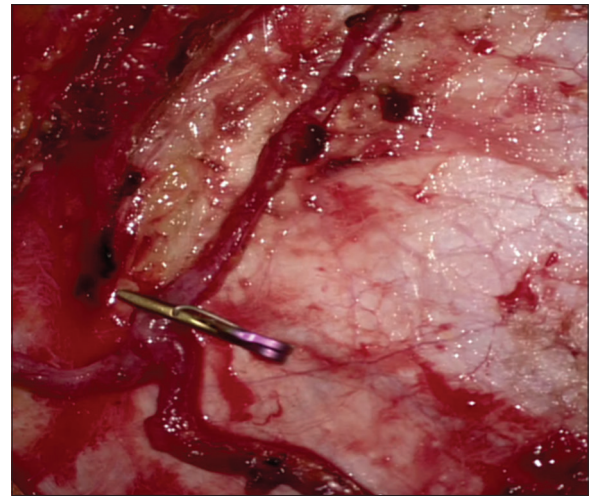


Figure 12: After skin incision, dissection and exposure of superficial temporal artery with its two branches, the frontal branch is clipped and prepared as a donor vessel

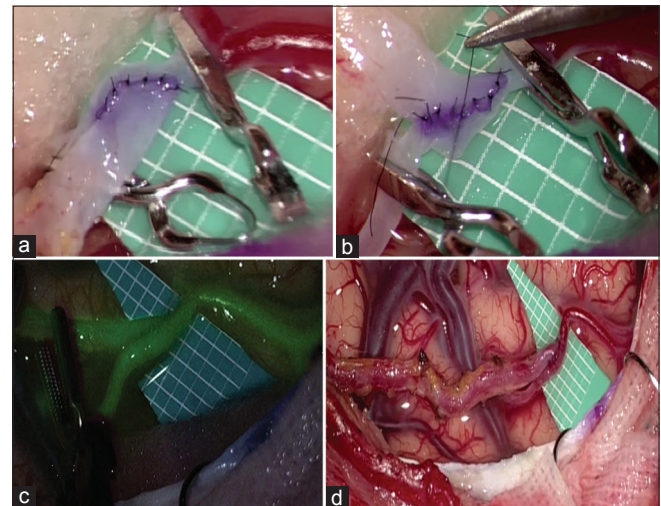


Figure 14: (a and b) showing the way to perform the anastomosis between donor and recipient vessel. (c) Dual-image videoangiography after anastomosis and removal of different clips showing good feeling in both donor and recipient vessels. (d) Operative view of the anastomosis

Discussion

Pre- and peri-operative considerations

Before performing an STA-MCA bypass, patients must be put on anticoagulant^[7,8] and antiagregant^[7] therapy to avoid thrombosis. There is no clear consensus but most surgeons prescribe aspirin 10 days before surgery, except cases of ruptured giant aneurysms. Heparin is only used during surgery and injected into both donor and recipient vessels.

Hemodynamic studies must be done before the surgery. Acetazolamide^[5,9] and single-photon emission CT^[10] are used in some centers. Cerebral blood flow (CBF)^[11,12] and cerebral blood volume (CBV)^[10] have to be recorded and

Table 1: Recap table of our series

	Date of surgery	Age	Sex	Pathology	Side	Complications
1	March 5, 2015	73	Male	Carotid stenosis	Left	
2	April 21, 2015	72	Male	Carotid occlusion	Right	CSDH
3	April 23, 2015	72	Male	Carotid occlusion	Right	CSDH- wound dehiscence
4	November 25, 2015	73	Female	Carotid occlusion	Left	
5	July 27, 2016	73	Male	Carotid stenosis	Left	
6	August 31, 2016	59	Male	Carotid stenosis	Left	
7	December 27, 2017	73	Female	Carotid stenosis	Right	CSDH
8	January 30, 2017	73	Male	Carotid stenosis	Right	
9	June 13, 2018	16	Male	Carotid stenosis	Left	
10	July 16, 2015	48	Male	Moya	Right	
11	September 27, 2017	6	Female	Moya	Left	
12	July 25, 2017	13	Female	Moya	Left	
13	April 19, 2018	51	Male	Moya	Left	
14	June 13, 2018	71	Female	Moya	Left	Wound dehiscence
15	February 04, 2015	78	Male	MCA occlusion	Left	
16	June 16, 2015	54	Male	MCA stenosis	Right	
17	May 31, 2016	49	Female	MCA Stenosis	Right	
18	January 30, 2017	64	Female	MCA Stenosis	Right	
19	August 07, 2018	59	Male	MCA Stenosis	Left	
20	August 07, 2018	64	Female	MCA Stenosis	Left	

MCA – Middle cerebral artery; CSDH – Chronic subdural hematoma

compared with contralateral side. Poor perfusion status was identified by a CBF ratio less than 0.95, and a CBV ratio greater than 1.05.^[10]

Patients must be managed during anesthesia with permanent normocapnia and perfect stability of arterial blood pressure.

Preoperative imaging studies should include the study of the STA with its different branches.

Indications

The most common cause of hemodynamic stroke is an atherosclerotic cerebrovascular disease.^[5] Cerebrovascular steno-occlusive disease is due to obstruction of ICA or MCA. The risk of subsequent stroke in carotid artery occlusion is 7% and the annual risk of stroke in the same side is 5.9%.^[5] The main goal of STA-MCA bypass here is to shunt an athero-occlusive stenosis even if there is ischemic but salvageable tissue or to prevent stroke. A large stroke on CT or magnetic resonance imaging (MRI) contraindicates bypass surgery because the brain tissue is not salvageable, and the blood flow augmentation may precipitate a hemorrhagic conversion. Even this indication remains controversial, the Saint Louis carotid stenosis study^[2,3] and the Japanese extracranial-intracranial bypass trial study showed better outcome for patients with stroke who underwent bypass surgery.^[10,13] The results of medically-treated patients are poor, STA-MCA bypass may provide better outcome. A CBF and brain metabolism study is essential in preoperative study for the success of this procedure. It allows a better selection for patients who present mismatches between blood supply and brain metabolism which increases the benefit of revascularization.

STA-MCA bypass is also indicated in moyamoya disease^[14,15] this cerebrovascular disorder characterized by a progressive occlusion of arteries around the carotid artery first reported by Takeuchi and Shimizu. Consequent to this occlusion, there will be formation of thin collateral vessels having the aspect of “puff of smoke” in angiography.^[3] Surgery is indicated for patients having symptomatic moyamoya disease. The goal of treatment in moyamoya disease is to improve cerebral flow.^[1,3,14] The optimal revascularization strategy remains controversial, STA-MCA bypass allows a direct revascularization; however, encephaloduroarteriosynangiosis (EDAS) can be used as indirect method.^[3,14] EDAS can be associated with the direct bypass surgery.

Bypass surgery is also used in the management of complex aneurysms.^[1,3,16,17] Anastomosis is considered when a sacrifice of parent vessel or one of its major branches is necessary. Even for complex ICA aneurysms, a high-flow bypass is sometimes recommended, STA-MCA bypass can be used in complex MCA aneurysms as a rescue bypass to provide a flow replacement before exclusion of the parent vessel.

Flow replacement may also be considered in skull base lesions^[3] involving vessels. Moreover, this indication remains controversial, in skull base cases, usually in almost cases there is a plan allowing peeling of the tumor from adjacent vessels. If the tumor is adherent to the vessel, it can be left to be managed conservatively and followed up by MRI or treated with radiosurgery.

Finally, STA-MCA bypass is also indicated in the incidental injury of MCA during aneurysm surgery or tumor removal when a direct repair of the vessel is not possible.

Surgical considerations

During the bypass, manipulation of both recipient and donor vessel should be correctly and carefully done to not damage the endothelium to avoid thrombosis of the bypass. Particularly in moyamoya, the recipient blood vessel is thinner than in normal cases, which makes manipulation and arteriotomy more difficult than usual STA-MCA bypass, the anastomosis should be done correctly and carefully.^[18]

In the literature, some authors prefer continuous sutures,^[5] in all our cases, we used noncontinuous sutures for all cases.

Complications

The most common complications of end-to-side STA-MCA bypass are perioperative stroke and graft occlusion. Millese *et al.*^[19] reported a case report of *de novo* aneurysm formation at the anastomosis side with a review of 17 cases published in the literature. Horiuchi *et al.*^[20] proposed a revision of the anastomosis in case of intraoperative occlusion. The use of antiplatelets in perioperative period, the maintain of a normal pressure while performing the anastomosis and the careful preparation of the anastomosis, decreases anastomosis difficulties and complications, and increases the patency of the anastomosis consequently improve the outcome.^[18] The Japan Adult Moyamoya study reported^[9] 9.4% of complications in 84 cases reported. In our current study, we did not observe any graft occlusion; GOS was at 5 for all patients of family health units series.

Limitations

If the diameter of STA is small, the anastomosis will not be feasible and it may require another surgical strategy. If STA is already used to provide blood supply to the hemisphere, indirect methods should be envisaged in moyamoya cases.^[21]

Conclusion

STA-MCA bypass is an elegant technique indicated for blood flow augmentation in symptomatic hemispheric hypoperfusion due to atherosclerotic steno-occlusive disease and moyamoya, or flow replacement in complex MCA aneurysms. This technique can also be used as a rescue method of revascularization of an incidentally injured vessel during surgery. Hemodynamic evaluation is important before the decision-making in ischemia. When correctly performed, this technique has a very low rate of complications with a high rate of patency (superior to 90%)^[7] and few complications as seen in Fujita Health University series where the bypass is performed by experienced hands with the use of multimodality treatment as DIVA and Doppler. Laboratory training, good learning of microsurgical and bypass techniques may help surgeons to improve the outcome of patients.

Declaration of patient consent

The authors certify that they have obtained all appropriate patient consent forms. In the form the patient(s) has/have given his/her/their consent for his/her/their images and other clinical information to be reported in the journal. The patients understand that their names and initials will not be published and due efforts will be made to conceal their identity, but anonymity cannot be guaranteed.

Financial support and sponsorship

Nil.

Conflicts of interest

There are no conflicts of interest.

References

1. Wessels L, Hecht N, Vajkoczy P. Bypass in neurosurgery – Indications and techniques. *Neurosurg Rev* 2018;1:1-5.
2. Vilela MD, Newell DW. Superficial temporal artery to middle cerebral artery bypass: Past, present, and future. *Neurosurg Focus* 2008;24:E2.
3. Sekhar LN, Natarajan SK, Ellenbogen RG, Ghodke B. Cerebral revascularization for ischemia, aneurysms, and cranial base tumors. *Neurosurgery* 2008;62:1373-408.
4. Hwang G, Oh CW, Bang JS, Jung CK, Kwon OK, Kim JE, *et al.* Superficial temporal artery to middle cerebral artery bypass in acute ischemic stroke and stroke in progress. *Neurosurgery* 2011;68:723-9.
5. Rodríguez-Hernández A, Josephson SA, Lawton MT. Bypass surgery for the prevention of ischemic stroke: Current indications and techniques. *Neurocirugia (Astur)* 2012;23:5-14.
6. Horiuchi T, Nitta J, Ishizaka S, Kanaya K, Yanagawa T, Hongo K, *et al.* Emergency EC-IC bypass for symptomatic atherosclerotic ischemic stroke. *Neurosurg Rev* 2013;36:559-64.
7. Thines L, Durand A, Penchet G, Proust F, Lenci H, Debailleul A, *et al.* Microsurgical neurovascular anastomosis: The example of superficial temporal artery to middle cerebral artery bypass. Technical principles. *Neurochirurgie* 2014;60:158-64.
8. Morton RP, Moore AE, Barber J, Tariq F, Hare K, Ghodke B, *et al.* Monitoring flow in extracranial-intracranial bypass grafts using duplex ultrasonography: A single-center experience in 80 grafts over 8 years. *Neurosurgery* 2014;74:62-70.
9. Miyamoto S, Yoshimoto T, Hashimoto N, Okada Y, Tsuji I, Tominaga T, *et al.* Effects of extracranial-intracranial bypass for patients with hemorrhagic moyamoya disease: Results of the Japan adult moyamoya trial. *Stroke* 2014;45:1415-21.
10. Ma Y, Yang F, Jiao L, Li M, Wang Y, Chen Y, *et al.* Superficial temporal artery-middle cerebral artery bypass surgery for refractory symptomatic intracranial atherosclerotic stenosis. *World Neurosurg* 2017;104:74-81.
11. Wang D, Zhu F, Fung KM, Zhu W, Luo Y, Chu WC, *et al.* Predicting cerebral hyperperfusion syndrome following superficial temporal artery to middle cerebral artery bypass based on intraoperative perfusion-weighted magnetic resonance imaging. *Sci Rep* 2015;5:14140.
12. Mukerji N, Cook DJ, Steinberg GK. Is local hypoperfusion the reason for transient neurological deficits after STA-MCA bypass for moyamoya disease? *J Neurosurg* 2015;122:90-4.

13. Jinnouchi J, Toyoda K, Inoue T, Fujimoto S, Gotoh S, Yasumori K, *et al.* Changes in brain volume 2 years after extracranial-intracranial bypass surgery: A preliminary subanalysis of the Japanese EC-IC trial. *Cerebrovasc Dis* 2006;22:177-82.
14. Amin-Hanjani S, Singh A, Rifai H, Thulborn KR, Alaraj A, Aletich V, *et al.* Combined direct and indirect bypass for moyamoya: Quantitative assessment of direct bypass flow over time. *Neurosurgery* 2013;73:962-7.
15. Abla AA, Gandhoke G, Clark JC, Oppenlander ME, Velat GJ, Zabramski JM, *et al.* Surgical outcomes for moyamoya angiopathy at barrow neurological institute with comparison of adult indirect encephaloduroarteriosynangiosis bypass, adult direct superficial temporal artery-to-middle cerebral artery bypass, and pediatric bypass: 154 revascularization surgeries in 140 affected hemispheres. *Neurosurgery* 2013;73:430-9.
16. Sanai N, Zador Z, Lawton MT. Bypass surgery for complex brain aneurysms: An assessment of intracranial-intracranial bypass. *Neurosurgery* 2009;65:670-83.
17. Kivipelto L, Niemelä M, Meling T, Lehecka M, Lehto H, Hernesniemi J, *et al.* Bypass surgery for complex middle cerebral artery aneurysms: Impact of the exact location in the MCA tree. *J Neurosurg* 2014;120:398-408.
18. Matano F, Murai Y, Tateyama K, Mizunari T, Umeoka K, Koketsu K, *et al.* Perioperative complications of superficial temporal artery to middle cerebral artery bypass for the treatment of complex middle cerebral artery aneurysms. *Clin Neurol Neurosurg* 2013;115:718-24.
19. Millesi M, Wang WT, Herta J, Bavinzski G, Knosp E, Gruber A, *et al.* *De novo* aneurysm formation at the anastomosis site incidentally detected 2 years after single-barrel STA-MCA bypass surgery: Case report and review of the literature. *J Neurol Surg A Cent Eur Neurosurg* 2015;76:323-7.
20. Horiuchi T, Tsutsumi K, Hasegawa T, Hongo K. Rescue revision techniques for end-to-side anastomosis: Technical note. *Surg Neurol Int* 2014;5:94.
21. Gross BA, Du R. STA-MCA bypass. *Acta Neurochir (Wien)* 2012;154:1463-7.