

Carotid Endarterectomy: The Need for *In vivo* Optical Spectroscopy in the Decision-Making on Intraoperative Shunt Usage – A Technical Note

Abstract

Background: Carotid endarterectomy (CEA) is the surgical excision of the atherosclerotic plaque in patients with severe carotid artery stenosis. It is a common surgical technique required by neurosurgeons that should be mastered. In this article, we provide an outline of the technique and multimodality adjuncts involved in performing an effective CEA with a better surgical outcome. **Materials and Methods:** We have operated a total of 14 patients in our institute from 2015 to 2018. The male to female ratio is 13:1. Four (28.5%) patients were symptomatic and 10 (71.5%) were asymptomatic; with an average percentage of carotid stenosis being 81.2% in symptomatic and 76.6% in asymptomatic patients. Two patients have undergone bilateral CEA. Intraoperative monitoring was done with continuous *in vivo* optical spectroscopy (INVOS). Furui's double balloon shunt system was used to maintain blood flow from common carotid artery to the internal carotid artery, thus preventing cerebral ischemia in selected cases with significantly lateralized cerebral oximetry (CO) recordings. **Results:** Of the 14 patients with 16 CEA procedures, continuous INVOS monitoring was used in 12 CEA procedures. Of the 12 cases, only 5 (41.6%) needed a shunt. Furui's shunt was not used in 7 (58.3%) CEA procedures, where there were no changes in the intraoperative CO and these patients had an uneventful postoperative period. INVOS monitoring not only reduced the use of routine intraoperative shunt but also reduced the total surgical time and thus aided in preventing neurological complications. **Conclusion:** CEA should be strongly considered for symptomatic patients with >70% of carotid stenosis and in patients with 50%–69% stenosis if no other etiological basis for the ischemic symptoms can be identified. Continuous INVOS monitoring is mandatory for the decision of the use of intraoperative shunt, which reduces the perioperative morbidity and mortality significantly.

Keywords: Dual-image videoangiography, endarterectomy, *in vivo* optical spectroscopy, intraoperative shunt

Introduction

Stroke is the third cause of disability and third leading cause of death in the world.^[1] Approximately 20%–30% of all strokes are caused by extracranial carotid artery stenosis. The prevalence of carotid stenosis is 7% in women and 9% in men. Stenosis is predominantly due to atherosclerosis. The major risk factors of atherosclerosis include dyslipidemia, hypertension, diabetes, obesity, cigarette smoking, advanced glycation end products (AGEs), and its receptors AGEs (RAGE and soluble RAGE), lack of exercise, and C-reactive protein.^[2] Extensive research in the past has identified carotid stenosis as a powerful predictor of stroke. The severity of stenosis is universally accepted to be directly proportional to an increased risk of future stroke.^[3,4]

DeBakey performed the first successful carotid endarterectomy (CEA) in 1953, but his seminal work, however, was only published in 1975.^[5] North American Symptomatic CEA Trial (NASCET) and European Carotid Surgery Trial (ECST) are the two largest well-consolidated trials that defined the indications and outcome of CEA in carotid stenosis patients.

Materials and Methods

We have operated a total of 14 patients in our institute from 2015 to 2018. Two patients have undergone bilateral CEA. The male to female ratio is 13:1. 13 (92.8%) patients had a positive history of hypertension. Four (28.5%) patients were symptomatic, and 10 (71.5%) were asymptomatic; with an average percentage

**Arun Balaji,
Niranjana
Rajagopal¹,
Yasuhiro Yamada²,
Takao Teranishi²,
Tsukasa Kawase²,
Yoko Kato²**

Department of Neurosurgery, Kovai Medical Centre and Hospital, Coimbatore, Tamil Nadu, ¹Department of Neurosurgery, Sri Sathya Sai Institute of Higher Medical Sciences, Bengaluru, Karnataka, India, ²Department of Neurosurgery, Banbuntane Hotokukai Hospital, Fujita Health University, Nagoya, Japan

Address for correspondence:

Dr. Arun Balaji,
41/D Sundaram Colony,
Jawahar Mill, Salem,
Coimbatore - 636 005,
Tamil Nadu, India.
E-mail: arunbal04@gmail.com

Access this article online

Website: www.asianjns.org

DOI: 10.4103/ajns.AJNS_223_18

Quick Response Code:



How to cite this article: Balaji A, Rajagopal N, Yamada Y, Teranishi T, Kawase T, Kato Y. Carotid endarterectomy: The need for *in vivo* optical spectroscopy in the decision-making on intraoperative shunt usage – A technical note. Asian J Neurosurg 2019;14:206-10.

This is an open access journal, and articles are distributed under the terms of the Creative Commons Attribution-NonCommercial-ShareAlike 4.0 License, which allows others to remix, tweak, and build upon the work non-commercially, as long as appropriate credit is given and the new creations are licensed under the identical terms.

For reprints contact: reprints@medknow.com

of carotid stenosis being 81.2% in symptomatic and 76.6% in asymptomatic patients. Intraoperative monitoring was done with (Somanetics, Inc., Troy, MI) *in vivo* optical spectroscopy (INVOS).^[6] Furui's double-balloon shunt system produced by Inter medical. Co, Ltd., was used to maintain blood flow from a common carotid artery (CCA) to internal carotid artery (ICA), thus preventing cerebral ischemia in selected cases with significantly lateralized cerebral oximetry (CO) recordings. Dual-image videoangiography (DIVA) was used intraoperatively to visualize the extent of plaque. It helps in planning the arterotomy and also provides the detail of extent of resection after the removal of plaque.

Illustrative case

A 60-year-old man presented with the transient ischemic attack. Carotid Doppler and three-dimensional (3D) computed tomography angiography (CTA) were done which showed >60% left carotid artery stenosis [Figure 1]. CEA was planned and executed as explained below.

Position and preparation

The patient under general anesthesia was positioned supine with his head turned right and in extension, on a horseshoe headrest for better exposure of the left side of the neck. Cranial strips of the INVOS monitor were placed over the patient's forehead and fixed properly. This continuously monitors the rSO₂ intraoperatively. Skin marking was done along the medial border of the sternocleidomastoid (SCM) followed by painting and draping [Figure 2].

Neck dissection

On lateralizing the SCM, hypoglossal nerve, and carotid sheath were seen. CCA, ICA, and ECA were dissected clearly after ligating the common facial vein from the internal jugular vein. Carotid sinus block was administered by injecting a small dose of the local anesthetic agent directly into the sinus. DIVA was performed before the opening of the carotid artery, which showed a filling defect, demarcating the extent of the atherosclerotic plaque intraoperatively [Figure 3].

In vivo optical spectroscopy and shunt placement

The temporary clip was placed over the ipsilateral ICA for about 30 s; following which there was a significant reduction in the CO recording. The rSO₂ reduced from 75 to 62, i.e., 17.3% reduction from the baseline value [Figure 4]. Therefore, we planned for a temporary shunt tube insertion between CCA and ICA, which maintained the cerebral blood flow during the entire time of the procedure and thus prevented cerebral ischemia. Furui's shunt tube system was prepared and inserted into the CCA and ICA. Distal balloons of the shunt were inflated with 0.5 ml of normal saline, and vascular clips were applied subsequently to keep the tubes from sliding out and to prevent the blood leakage around the sides of the tube. After successful shunt

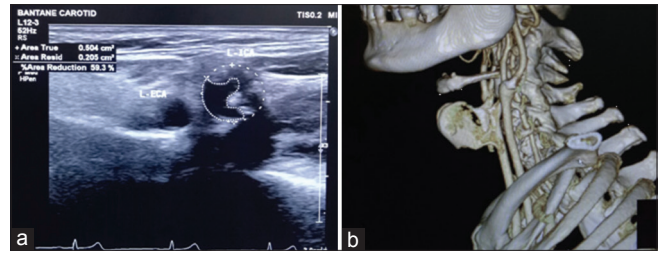


Figure 1: (a) Doppler and (b) three-dimensional computed tomography angiography, showing significant carotid artery stenosis

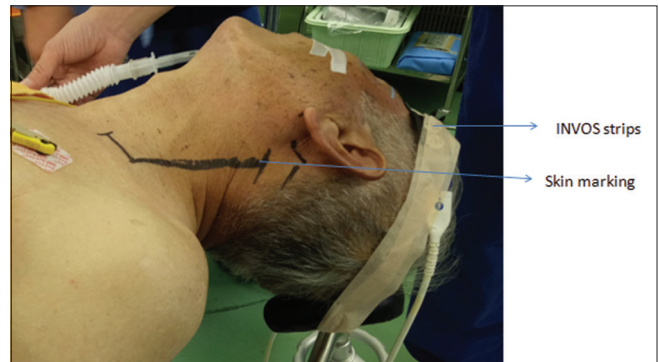


Figure 2: Patient positioned in horseshoe headrest, with *in vivo* optical spectroscopy cranial strips over the frontal region and skin marking over the medial border of SCM. *In vivo* optical spectroscopy - *in vivo* optical spectroscopy, SCM – Sternocleidomastoid

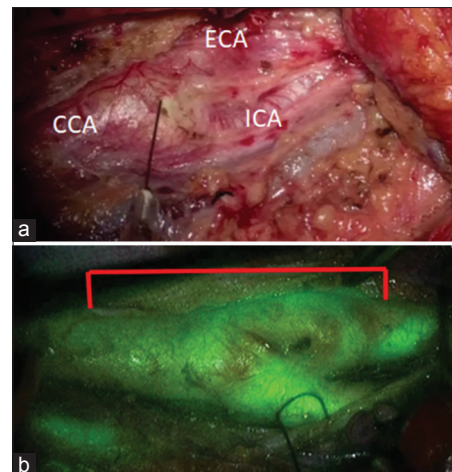


Figure 3: (a) Carotid sinus block with local anesthesia, (b) Dual-image videoangiography showing the extent of atherosclerotic plaque

placement, the INVOS recordings came back to baseline value.

Arterotomy and excision of plaque

ECA, CCA, and ICA were clamped, respectively. Arterotomy was done from the CCA to ICA; the plaque was identified and dissected all around, away from the arterial wall and excised completely [Figure 5]. We used 6-0 prolene to suture the arterotomy wound from ICA toward CCA and then from CCA to ICA with shunt tube *in situ*, subsequently, shunt tubes were removed and

suturing was completed. DIVA was done after the removal of all temporary clips which showed improvement in blood flow with no filling defect in comparison to the preoperative assessment [Figure 6]. Postoperative period was uneventful. Postoperative 3D-CTA showed an increase in the diameter of the operated carotid artery with improved blood flow and no filling defect [Figure 7].

Results

In our series of 14 patients with 16 CEA procedures, continuous INVOS monitoring was used in 12 CEA procedures. Of the 12 only 5 (41.6%) needed an intraoperative shunt. A shunt was not used in 7 (58.3%) CEA procedures, where there were no changes in the intraoperative CO, and these patients had an uneventful postoperative period. INVOS monitoring not only reduced the use of routine shunt but also reduced the total surgical time and aided in preventing neurological complications. DIVA was used in 12 CEA cases, which helped in demarcating the atherosclerotic plaque and helped in deciding the extent of resection of the plaque intraoperatively. Although intraoperative shunting was

not required in all the cases, it was found highly useful in cases with significantly reduced rsO_2 values to prevent postoperative deficits.

Postoperative carotid Doppler and CTA were done in all the patients. The preoperative and postoperative vessel caliber was compared in all patients. The diameter of the involved artery was significantly larger postoperatively thus proving the efficacy of the procedure. There was no morbidity or mortality in our series.

Discussion

Symptomatic and asymptomatic carotid artery stenosis

A patient with carotid artery stenosis is considered symptomatic if the patient has transient or permanent focal neurologic symptoms (visual field defect, hemiparesis/plegia, and aphasia in the case of dominant [usually left] hemisphere involvement). Nonspecific symptoms such as dizziness, generalized subjective weakness, syncope or near-syncope episodes or blurred vision, in patients with carotid artery stenosis, do not qualify as symptomatic ischemic events. These patients are considered asymptomatic even in the presence of high-grade carotid artery stenosis.^[7]

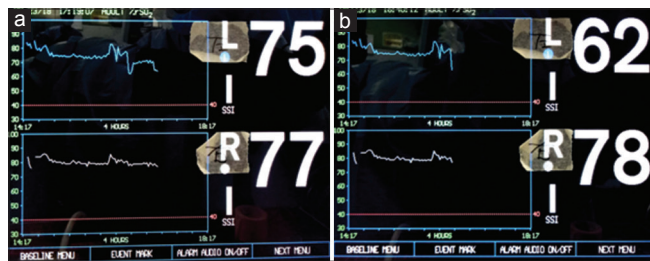


Figure 4: *In vivo* optical spectroscopy recordings, (a) baseline value, (b) after occlusion of the left internal carotid artery for 30 s, rsO_2 reduced from 75 to 62, i.e., 17.3% reduction in baseline value

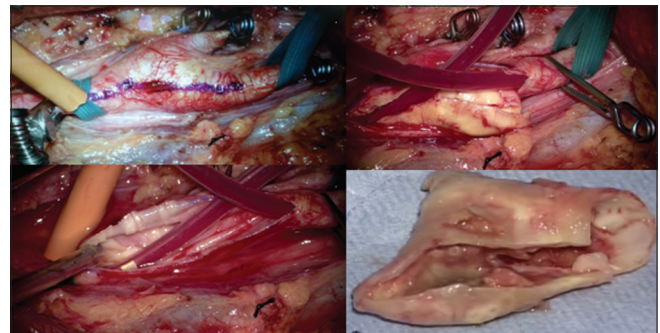


Figure 5: Furui's shunt inserted into common carotid artery and internal carotid artery, followed by excision of atherosclerotic plaque

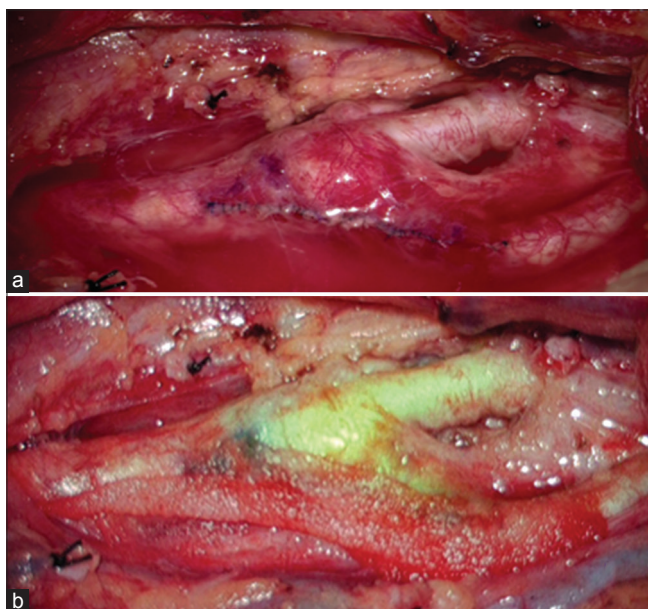


Figure 6: (a) Completely sutured arteriotomy wound, (b) postprocedural Dual-image videoangiography showing improved flow

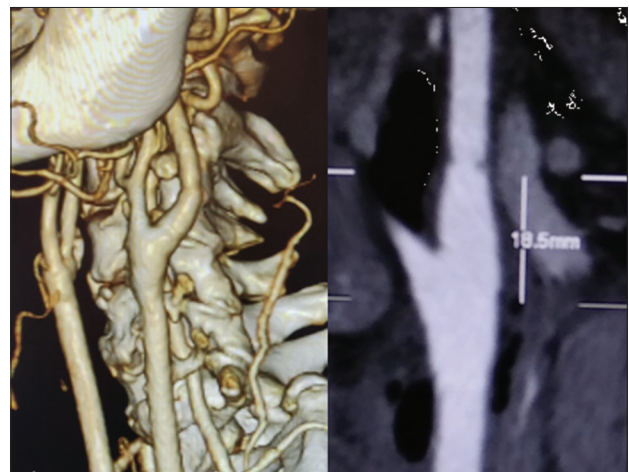


Figure 7: Postoperative three-dimensional computed tomography angiography shows an increase in the diameter of the carotid with improved blood flow

Diagnosis

Carotid auscultation should be a part of the routine physical examination of the patient. Although carotid bruit has limited value in the diagnosis of carotid artery stenosis, they are good markers of generalized atherosclerosis. Since Japan has a higher incidence of intracranial aneurysms and cerebrovascular diseases, routine head and neck imaging are a part of the screening protocol. Doppler ultrasonography is a noninvasive and the first imaging tool used to screen carotid artery stenosis. Compared to catheter angiography, Doppler ultrasonography has a sensitivity of 86% and a specificity of 87% for the detection of hemodynamically significant carotid artery stenosis. DSA is the gold standard for defining the degree of stenosis and the morphologic features of the offending plaque. 3D-CTA and magnetic resonance angiography have gained increasing popularity for use in the diagnosis of carotid artery stenosis, often replacing conventional catheter angiography.^[8,9]

Indications and benefits of carotid endarterectomy

Symptomatic patients according to NASCET^[10,11] is with >70% carotid stenosis, and there is also a proven benefit in symptomatic patients with a moderate (50%–69%) degree of stenosis in preventing ipsilateral stroke during a 2-year period. ECST^[12] showed benefits of CEA in symptomatic patients with >80% (corresponding NASCET = 60%) carotid stenosis. In asymptomatic carotid atherosclerosis study^[13] and^[14] (asymptomatic carotid surgery trial) trials, patients <75 years of age with asymptomatic a significant carotid artery stenosis ($\geq 60\%$), successful CEA reduced the 10-year risk of ipsilateral stroke with significant reduction in perioperative mortality and morbidity as compared to deferred CEA.

Technique

Most surgeons prefer selective shunting during carotid cross-clamping while performing a CEA. Selective shunting necessitates the use of a monitoring system to detect cerebral ischemia. Various monitoring systems such as transcranial Doppler (TCD), electroencephalograms, and INVOS are available to detect the cerebral blood flow and impending ischemia.

A Cochrane review in 2002 concluded that the available data were too limited to support or refute the use of routine or selective shunting in CEA, and no one method of monitoring selective shunting has been shown to produce better outcomes.^[15]

Cuadra *et al.*^[16] used the INVOS-4100 CO during 42 consecutive CEAs in 40 patients to measure the effect of carotid clamping and shunting on rSO_2 . Although this study showed statistically significant changes in rSO_2 as a result of clamping and shunting of the carotid artery, they were not convinced in using CO as a sole monitor for deciding on an intraoperative shunt.

Recent studies compared CO to other monitors such as TCD in performing CEA and found CO has a better correlation compared to the TCD. CO is more accurate than TCD in predicting the need for carotid shunting.^[17]

INOS [Figure 8] uses infrared light in the range of 650–1100 nm.^[18,19] This noninvasive monitoring system detects the hemoglobin oxygen saturation of blood in the brain of an individual. DIVA utilizes the intravenous indocyanine green with near-infrared fluorescence, which is visualized in a single monitor.^[20,21] It helps in identifying the atherosclerotic occlusion by opaque or nonglowing area in the monitor. Postprocedural DIVA delineates the extent of plaque resection.

The Furui's shunt system consists of a flexible silicone tube which is 20 cm long, equipped with silicone rubber balloons at both ends. Each balloon can be inflated individually, with saline of about 0.5ml to prevent bleeding from the gaps between the tube and the carotid arteries. Clamps are placed around the common and ICA to avoid further leakage, thus preventing blood loss which in turns reduces the possibility of ischemia and gives a bloodless field for the procedure.^[22,23]

Carotid stenting (CAS) was introduced as a treatment to prevent stroke in 1994. The carotid revascularization endarterectomy versus stenting trial^[24] is the largest trial comparing CAS and CEA in symptomatic and asymptomatic carotid stenosis patients. CAS and CEA had similar short- and long-term outcomes. During the perioperative period, there was a higher risk of stroke in CAS and a higher risk of myocardial infarction in CEA patients. Patients <70 years of age had lesser complications with CAS compared to people >70 years of age, who tolerated CEA well.^[25,26]

Conclusion

CEA should be considered for symptomatic patients with >70% of carotid stenosis and also with 50%–69%

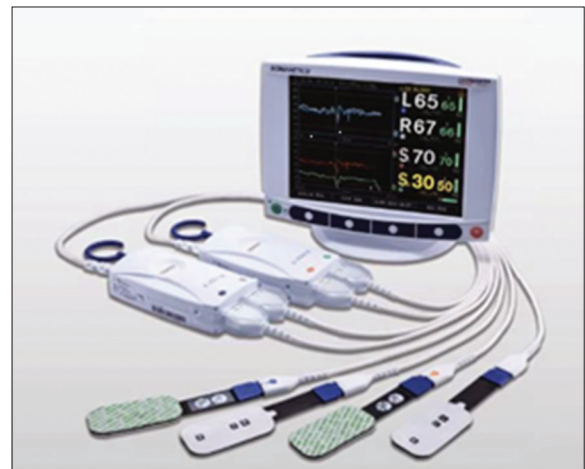

Figure 8: *In vivo* optical spectroscopy cerebral oximetry with cranial strips

stenosis if no other etiologic basis for the ischemic symptoms can be found. CEA should be considered in asymptomatic patients with >60% stenosis. Continuous INVOS monitoring is mandatory for the decision of the use of intraoperative shunt, which reduces the perioperative morbidity and mortality significantly. More randomized controlled trials are necessary to help clarify the indications and benefits of these procedures for different subgroups of patients with carotid artery disease.

Declaration of patient consent

The authors certify that they have obtained all appropriate patient consent forms. In the form the patient(s) has/have given his/her/their consent for his/her/their images and other clinical information to be reported in the journal. The patients understand that their names and initials will not be published and due efforts will be made to conceal their identity, but anonymity cannot be guaranteed.

Financial support and sponsorship

Nil.

Conflicts of interest

There are no conflicts of interest.

References

- Feigin VL, Lawes CM, Bennett DA, Anderson CS. Stroke epidemiology: A review of population-based studies of incidence, prevalence, and case-fatality in the late 20th century. *Lancet Neurol* 2003;2:43-53.
- Prasad K. Pathophysiology and medical treatment of carotid artery stenosis. *Int J Angiol* 2015;24:158-72.
- Liapis CD, Kakisis JD, Kostakis AG. Carotid stenosis: Factors affecting symptomatology. *Stroke* 2001;32:2782-6.
- Flaherty ML, Kissela B, Khoury JC, Alwell K, Moomaw CJ, Woo D, *et al.* Carotid artery stenosis as a cause of stroke. *Neuroepidemiology* 2013;40:36-41.
- DeBakey ME. Successful carotid endarterectomy for cerebrovascular insufficiency. Nineteen-year follow-up. *JAMA* 1975;233:1083-5.
- INVOS Monitor Serial Number; 2013. Available from: <http://www.covidien.com>. [Last accessed on 2018 Sep 23].
- Lanzino G, Rabinstein AA, Brown RD Jr. Treatment of carotid artery stenosis: Medical therapy, surgery, or stenting? *Mayo Clin Proc* 2009;84:362-87.
- Nederkorn PJ, van der Graaf Y, Hunink MG. Duplex ultrasound and magnetic resonance angiography compared with digital subtraction angiography in carotid artery stenosis: A systematic review. *Stroke* 2003;34:1324-32.
- Meschia JF, Brott TG, Hobson RW 2nd. Diagnosis and invasive management of carotid atherosclerotic stenosis. *Mayo Clin Proc* 2007;82:851-8.
- North American Symptomatic Carotid Endarterectomy Trial Collaborators, Barnett HJ, Taylor DW, Haynes RB, Sackett DL, Peerless SJ, *et al.* Beneficial effect of carotid endarterectomy in symptomatic patients with high-grade carotid stenosis. *N Engl J Med* 1991;325:445-53.
- Earnshaw JJ. Carotid endarterectomy – The evidence. *J R Soc Med* 2002;95:168-70.
- MRC European Carotid Surgery Trial: Interim results for symptomatic patients with severe (70-99%) or with mild (0-29%) carotid stenosis. European Carotid Surgery Trialists' Collaborative Group. *Lancet* 1991;337:1235-43.
- Endarterectomy for asymptomatic carotid artery stenosis. Executive committee for the asymptomatic carotid atherosclerosis study. *JAMA* 1995;273:1421-8.
- Halliday A, Harrison M, Hayter E, Kong X, Mansfield A, Marro J, *et al.* 10-year stroke prevention after successful carotid endarterectomy for asymptomatic stenosis (ACST-1): A multicentre randomised trial. *Lancet* 2010;376:1074-84.
- Bond R, Rerkasem K, Counsell C, Salinas R, Naylor R, Warlow CP, *et al.* Routine or selective carotid artery shunting for carotid endarterectomy (and different methods of monitoring in selective shunting). *Cochrane Database Syst Rev* 2002;(2):CD000190.
- Cuadra SA, Zwerling JS, Feuerman M, Gasparis AP, Hines GL. Cerebral oximetry monitoring during carotid endarterectomy: Effect of carotid clamping and shunting. *Vasc Endovascular Surg* 2003;37:407-13.
- Ali AM, Green D, Zayed H, Halawa M, El-Sakka K, Rashid HI, *et al.* Cerebral monitoring in patients undergoing carotid endarterectomy using a triple assessment technique. *Interact Cardiovasc Thorac Surg* 2011;12:454-7.
- McCormick PW, Stewart M, Lewis G, Dujovny M, Ausman JI. Intracerebral penetration of infrared light. Technical note. *J Neurosurg* 1992;76:315-8.
- de Letter JA, Sie TH, Moll FL, Algra A, Eikelboom BC, Ackerstaff GA, *et al.* Transcranial cerebral oximetry during carotid endarterectomy: Agreement between frontal and lateral probe measurements as compared with an electroencephalogram. *Cardiovasc Surg* 1998;6:373-7.
- Sato T, Suzuki K, Sakuma J, Takatsu N, Kojima Y, Sugano T, *et al.* Development of a new high-resolution intraoperative imaging system (dual-image videoangiography, DIVA) to simultaneously visualize light and near-infrared fluorescence images of indocyanine green angiography. *Acta Neurochir (Wien)* 2015;157:1295-301.
- Feletti A, Wang X, Tanaka R, Yamada Y, Suyama D, Kawase T, *et al.* Dual-image videoangiography during intracranial microvascular surgery. *World Neurosurg* 2017;99:572-9.
- Shima T, Okada Y, Nishida M, Yamane K. A newly developed shunt system for carotid surgery: T-shaped silicone shunt tubes and clamping devices: Technical note. *Neurosurgery* 1998;42:1182-4.
- Furui T, Hasuo M. Indwelling double-balloon shunt for carotid endarterectomy. Technical note. *J Neurosurg* 1984;60:861-3.
- Mantese VA, Timaran CH, Chiu D, Begg RJ, Brott TG; CREST Investigators. The carotid revascularization endarterectomy versus stenting trial (CREST): Stenting versus carotid endarterectomy for carotid disease. *Stroke* 2010;41:S31-4.
- Brott TG, Hobson RW 2nd, Howard G, Roubin GS, Clark WM, Brooks W, *et al.* Stenting versus endarterectomy for treatment of carotid-artery stenosis. *N Engl J Med* 2010;363:11-23.
- Adams HP Jr. Management of carotid artery stenosis: Endarterectomy or stenting? *Mayo Clin Proc* 2010;85:1071-2.