

Clinicopathological Characteristics of Meningiomas: Experience from a Tertiary Care Hospital in the Kashmir Valley

Abstract

Background: Meningiomas comprise 15%–20% of all primary intracranial tumors. They are generally benign tumors, and most patients are cured after surgery and remain free of recurrence. However, some tumors behave in an aggressive manner, and patients develop local recurrence or metastasis. Overall prognosis is good. **Patients and Methods:** This is an 11-year retrospective study conducted in the Departments of Pathology and Neurosurgery at Sheri-I-Kashmir Institute of Medical Sciences, Kashmir, India. Besides the demographic profile, the parameters analyzed were location of tumor on imaging, histopathological subtype, and grade of tumor according to the 2007 WHO classification and recurrence at follow-up. **Results:** A total of 254 patients were included in our study, of which 205 (80.7%) were brain meningiomas and 49 (19.3%) were spinal, with an overall female: male ratio of 2:1. Female: male ratio was more in spinal meningiomas, 15.3:1. Most of our patients were in the 4–6th decade of life with a mean age of 48 years (range: 5–73 years). Meningothelial meningioma was the most common histological type. Of ten patients who showed recurrence, seven cases showed only recurrence, but no progression to higher grade and three cases showed recurrence with progression by one WHO-grade. We also noticed that recurrence was higher in Simpson Grades II and III. **Conclusion:** Meningiomas are common in females and most of the meningiomas do well after surgery. The recurrence rate was 3.93% in our study and Simpson grade of tumor excision and histopathological grade contribute significantly to the recurrence of the tumor.

Keywords: Meningioma, recurrence, Simpson grade, WHO grading

Introduction

Meningiomas comprise 15%–20% of all primary intracranial tumors.^[1,2] They are twice as common in the female as in the male population, but a reverse male-to-female preponderance of 3:1 has been reported in the malignant form. The incidence increases with age with peak incidence between the ages of 40 and 60 years. A slight drop after the 8th decade has been noted.^[3] They are generally benign tumors, and most patients are cured after surgery and remain free of recurrence. However, some tumors behave in a more aggressive fashion, and patients develop local recurrence or metastasis. Histopathologically, meningiomas currently are separated into three grades, i.e., benign (ordinary) meningioma, atypical meningioma, and anaplastic (malignant) meningioma, that intend to reflect the clinical behavior of the tumors.^[4] In completely excised tumors, the 5-year recurrence rate for patients with benign meningiomas is 21%, and the rates for patients with atypical

and anaplastic meningiomas range between 38% and 78%, respectively.^[5,6]

Patients and Methods

This is a retrospective study conducted in the Departments of Pathology and Neurosurgery at Sheri-I-Kashmir Institute of Medical Sciences, Kashmir, India. The study period was from May 2003 to April 2014, a period of 11 years. All the patients diagnosed as meningiomas in our department were included in the study. The parameters analyzed included age, gender, location of tumor on imaging, histopathological subtype, and grade of tumor according to the 2007 WHO classification.^[4] All the cases were reviewed histologically by a single neuropathologist. In doubtful and high-grade lesions, special stains such as reticulin, phosphotungstic acid hematoxylin, and immunohistochemistry were used. Patients were followed up on outpatient basis in the Department of Neurosurgery. As per the departmental protocol, serial contrast

**Basharat Mubeen,
Rumana
Makhdoomi,
Khursheed Nayil¹,
Danish Rafiq,
Altaf Kirmani¹,
Othman Salim,
Farhat Mustafa,
Aifa Aimen,
Sumat Khursheed,
Shazia Bashir,
Saba Shafi,
Altaf Ramzan¹**

*Departments of Pathology and
¹Neurosurgery, Sher-I-Kashmir
Institute of Medical Sciences,
Srinagar, Jammu and Kashmir,
India*

Address for correspondence:

*Dr. Rumana Makhdoomi,
Department of Pathology,
Sher-I-Kashmir Institute
of Medical Sciences,
Srinagar - 190 011,
Jammu and Kashmir, India.
E-mail: rumanamak@gmail.com*

Access this article online

Website: www.asianjns.org

DOI: 10.4103/ajns.AJNS_228_16

Quick Response Code:



This is an open access journal, and articles are distributed under the terms of the Creative Commons Attribution-NonCommercial-ShareAlike 4.0 License, which allows others to remix, tweak, and build upon the work non-commercially, as long as appropriate credit is given and the new creations are licensed under the identical terms.

For reprints contact: reprints@medknow.com

How to cite this article: Mubeen B, Makhdoomi R, Nayil K, Rafiq D, Kirmani A, Salim O, *et al.* Clinicopathological characteristics of meningiomas: Experience from a tertiary care hospital in the Kashmir Valley. Asian J Neurosurg 2019;14:41-6.

computed tomography (CT) scans were performed at 1, 2, 5, and 10 years of surgery. Other than this, patients who presented with raised intracranial pressure symptoms or new onset neurodeficits were also subjected to contrast CT. There were three in-hospital mortalities and 1-year follow-up was available in 237, 2-year in 211, 5-year in 186, and 10-year in 83 patients.

Results

A total of 254 patients were included in the study. Overall, we had 170 females and 84 males; the ratio was 2:1, of which 205 (80.7%) were brain meningiomas and 49 (19.3%) were spinal. Location was supratentorial in 192 (75.6%) patients, infratentorial in 13 (5.1%), and spinal in 49 (19.3%) patients. Meningothelial meningioma was most common histological type (41.33%, 105/254), followed by transitional (18.50%, 47/254) and psammomatous (11.81%) [Table 1]. The WHO Grade I was seen in 229 (90.2%) patients, 14 (5.5%) had Grade II, and 11 (4.3%) had Grade III tumors [Table 2].

Brain meningiomas

Of 205 patients, 129 (60%) were female and 85 (40%) were male. Most of our patients were in the 4–6th decade of life

with age range of 5–73 years. Only 5 (0.02%) patients were in the pediatric age group. On the correlation of gender ratio with age, we found that females predominated males in the 4th, 5th, and 6th decade and this predominance is less pronounced in elderly and pediatric patients. Convexity meningioma was the most common subtype of meningioma, followed by parasagittal [Table 3 and Figure 1].

Meningothelial meningioma was the most common histological type (41.9%), followed by transitional (20.9%), fibroblastic (10.7%), psammomatous (6.8%), and angiomatous (5.3%) [Table 3].

The WHO Grade I was seen in 180 (87.8%) patients, 14 (6.8%) had Grade II, and 11 (5.4%) had Grade III tumors [Table 2]. Similarly, we found that higher grade WHO Grade II and III meningiomas are more common in males as opposed to Grade I lesions which are more common in females, and the difference was statistically significant ($P = 0.0084$) [Table 4].

There were ten patients who had recurrences with age ranging from 24 to 65 years, five patients were male and five were female. The mean time taken for recurrence to develop was 4.7 years ranging from 1 to 9 years; six recurrences took place within 5 years of surgery and 4 within >5–10 years. We did not encounter recurrence after 10 years [Figure 2]. On recurrence, four patients had WHO Grade I, 5 had Grade II, and 1 had Grade III lesions.

Table 1: Histopathological break up vis-à-vis location of the tumor

Histopathological subtype	Location		Total
	Cranial	Spinal	
1. Anaplastic	6 (2.9)	0	6 (2.36)
2. Angioblastic	1 (0.48)	0	1 (0.39)
3. Angiomatous	11 (5.3)	1 (2.04)	12 (4.72)
4. Atypical	15 (7.3)	0	15 (5.90)
5. Clear cell	1 (0.48)	0	1 (0.39)
6. Chordoid	1 (0.48)	0	1 (0.39)
7. Fibroblastic	22 (10.7)	2 (4.1)	24 (9.44)
8. Lymphoplasmacytic	2 (0.9)	0	2 (0.78)
9. Meningothelial	86 (41.9)	19 (38.8)	105 (41.3)
10. Metaplastic	1 (0.48)	0	1 (0.39)
11. Papillary	3 (1.4)	0	3 (1.18)
12. Psammomatous	14 (6.8)	16 (32.6)	30 (11.81)
13. Rhabdoid	2 (0.9)	0	2 (0.78)
14. Secretory	1 (0.48)	0	1 (0.39)
15. Syncytial	2 (0.9)	1 (2.04)	3 (1.18)
16. Transitional	43 (20.9)	4 (8.2)	47 (18.50)
Total	205	49	254

Table 2: WHO grade of tumor vis-à-vis location

WHO grade	n (%)		Total
	Brain	Spine	
I	180 (87.8)	49 (100)	229 (90.2)
II	14 (6.8)	0	14 (5.5)
III	11 (5.4)	0	11 (4.3)
Total	205	49	254 (100)

n: Number

Table 3: Location of tumors on imaging

Location	Gender		Total
	Female	Male	
Parasagittal	16	6	22
Intraventricular	1	0	1
Falcotentorial	1	0	1
Sellar/suprasellar	8	6	14
Convexity	64	50	114
Spinal	46	3	49
Falcine	10	8	18
Posterior fossa	8	1	9
ACF base	9	6	15
Sphenoid	2	1	3
CP angle	5	2	7
Primary intraosseous meningioma	0	1	1
Total	170	84	254

Table 4: Relation of gender with WHO grade of tumor

Grading	Gender		Total
	Female	Male	
WHO-I	116	64	180
WHO-II	3	11	14
WHO-III	6	5	11
Total	125	80	205

$P=0.0084$ (highly significant)

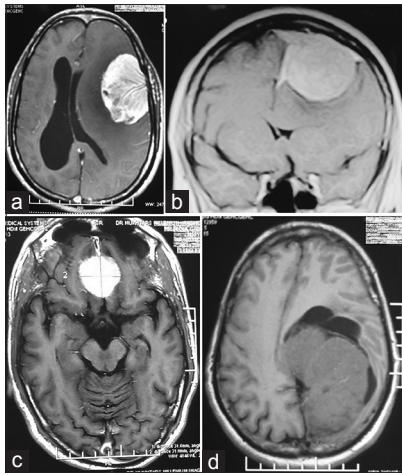


Figure 1: Magnetic resonance imaging brain shows convexity (a), parasagittal (b), anterior cranial base (c), and intraventricular meningiomas (d)

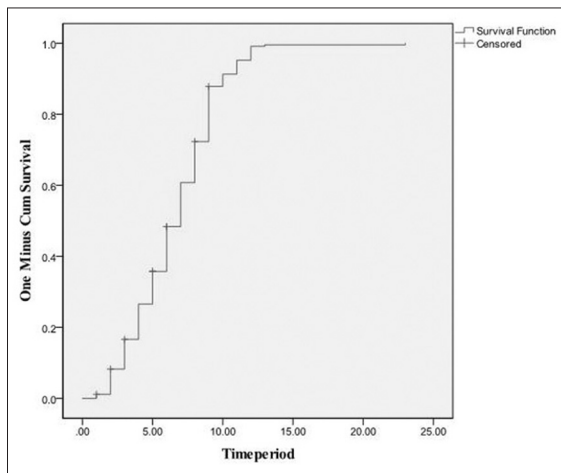


Figure 2: Kaplan–Meier survival analysis shows the pattern of recurrence with time

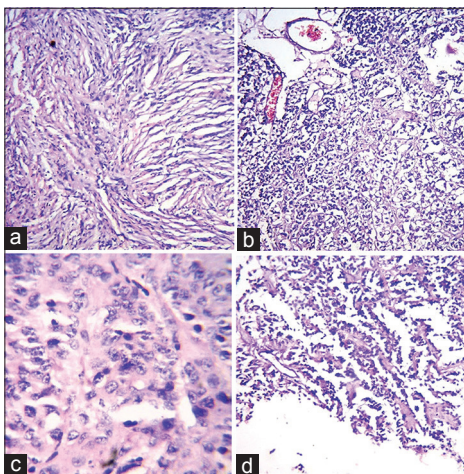


Figure 3: (a) Microphotograph showing a whorling pattern in a fibroblastic meningioma (H and E, ×200). (b) Microphotograph showing clear cells in a clear cell meningioma (H and E, ×200). (c) Pleomorphic tumor cells with mitotic figures in an anaplastic meningioma (H and E, ×400). (d) Microphotograph showing papillary arrangement of cells in a papillary meningioma (H and E, ×200)

On studying the previous grade, we found that seven cases had Grade I, 2 had Grade II, and 1 had Grade III lesions. Grade II and Grade III lesions did not change their grade on recurrence in our study, but out of seven Grade I tumors, three cases morphed to higher grade (Grade II) [Table 5]. On analyzing cases of recurrence, we noticed a statistically significant relation with Simpson grade of excision and the WHO histopathological grade [Tables 6 and 7].

Spinal meningiomas

Of 49 patients, 46 (94%) patients were female and only 3 (6%) were male. Most of our patients presented in the 4–6th decade. We did not notice any pediatric patient with spinal meningiomas in our study. All the lesions were intradural and extramedullary. Dorsal spine (69.57%) was the most common site, followed by cervical (15.22%), cervicodorsal (10.87%), dorsolumbar (2.17%), and lumbar (2.17%). Meningothelial meningiomas (38.8%) were the most common histological type, followed by psammomatous (32.6%) and transitional (8.2%) [Table 1]. All the cases were WHO Grade I lesions [Table 2] and we did not note any recurrence in spine.

Discussion

Meningiomas are common tumors of the central nervous system that originate from the meningeal coverings of the spinal cord and the brain. Although the cell of origin has yet to be proven, meningiomas are probably derived from arachnoid cap cells. These cells form the outer

Table 5: Progression of tumor grade with recurrence

WHO grade	Grade at first surgery	Grade after recurrence
I	7	4
II	2	5
III	1	1

Table 6: Relation of recurrence with Simpsons grade of tumor excision

Simpsons grade	No recurrence	Recurrence	Total
I	109	1	110[43.3]
II	133	7	140[55.2]
III	2	2	4[1.5]

P=0.04 (significant)

Table 7: Relation of WHO grade and recurrence

Grading	Recurrence		Total
	No recurrence	Recurrence	
WHO-I	225	4	229
WHO-II	9	5	14
WHO-III	10	1	11
Total	244	10	254

P=0.0001(significant)

layer of the arachnoid mater, and arachnoid villi show a striking cytological similarity to meningioma tumor cells.^[7] Meningiomas comprise 15%–20% of all primary intracranial tumors.^[1,2]

These tumors are the most commonly reported in elderly patients with a peak incidence in the 7th decade of life.^[7] Nonetheless, they also occur in children.^[4] Meningiomas of the first two decades of life are distinctly less common, with a corresponding incidence of 1%–4%.^[8] In our study, the peak was seen in the 4–6th decade of life. Only five of our patients presented in the pediatric age group of 18 years or less. There is a clear bias toward women with a female: male ratio of about 2:1. Spinal meningiomas have an even greater predilection for females.^[5] In our study, the female: male ratio for spinal meningiomas was 15.3:1. The vast majority of meningiomas arise intracranial, intraspinal, or orbital locations. Intraventricular and epidural examples are uncommon. Within the cranial cavity, most meningiomas occur over the cerebral convexities and in the parasagittal area in association with the falx and venous sinus.^[4] Although they can potentially occur at any site in the meninges, about 90% are supratentorial and 10% are infratentorial. Uncommonly sited tumors include intraosseous meningiomas and extraneuraxial meningiomas. Meningiomas have also been reported in the lungs, mediastinum, and adrenal gland.^[8] We did not notice any extraneuraxial meningioma in our series. Spinal meningiomas occur less frequently than intracranial ones and account for approximately 7.5%–12.7% of all meningiomas.^[9,10] We observed 80.7% and 19.3% cranial and spinal meningiomas, respectively. Most of our meningiomas were located over cerebral convexities followed by parasagittal meningiomas. Supratentorial meningiomas were seen in 75.6% and infratentorial in 5.1%. We observed one case of primary intraosseous meningiomas.^[11]

The most frequent location of spinal meningiomas is the thoracic region (67%–84%) followed by the cervical spine (14%–27%) and only rarely in the lumbar spine (2%–14%).^[12-19] In spine, all our cases were intradural extramedullary. Most spinal meningiomas occurred in the thoracic region in our study.

Meningiomas are usually solitary but can be multiple. Rarely, meningiomas may grow as a flat, carpet-like mass, a pattern termed “en plaque meningioma.” We noticed one such case.^[18] In our study, we noticed only three cases of multiple meningiomas. All the 49 spinal meningiomas were WHO Grade I. Among brain meningiomas, 87.8% of cases were Grade I lesions, 6.8% Grade II, and 5.4% Grade III lesions [Table 2] which are consistent with world literature.^[4,8,19-22] [Figure 3] Meningothelial, psammomatous, transitional, and fibroblastic meningiomas were the most common histological subtypes.

Histopathology of the tumors in the pediatric population varies from those in the adult population. Overall, most

series have shown a high incidence of atypical and anaplastic meningiomas in children as compared to the adult population.^[22] We in our series had only five children, two had rhabdoid and one each had anaplastic, meningothelial, and psammomatous meningioma. Overall in our series, 7.3% had an atypical and 2.9% had anaplastic histopathology. Meningiomas are predominantly seen in females.^[23] Mahmood *et al.* and Alvarez have reported male predominance for atypical and malignant meningiomas.^[24] Jääskeläinen *et al.* have reported an equal distribution for males and females.^[5] In our study, male: female ratio of 13:2 was seen in atypical meningiomas whereas equal gender distribution was seen in anaplastic meningiomas.

Meningiomas recur and some histological variants of meningioma are more likely to recur.^[25] While benign meningiomas have recurrence rates of about 7%–25%, atypical meningiomas recur in 29%–52% of cases, and anaplastic meningiomas at rates of 50%–94%.^[26,27] Malignant histopathological features are associated with shorter survival times,^[4] one series reporting a median survival of <2 years.^[26] In our 11-year study, only 10 (3.94%) cases were recurrent tumors. Several studies have reported higher recurrence rates for males than for females.^[28-31] Nakasu *et al.* and several other authors found no association between tumor development in young patients (<40 years) and a high likelihood of recurrence.^[31] However, there also is evidence in the literature wherein a significant difference between age and recurrence has not been found.^[32,33] In our study, we found a definite influence of gender and age on recurrence. Pediatric (<18 years) and elderly population (>60 years) constituted 50% of our recurrent tumors, thus signifying the increased incidence of recurrence at extremes of age. We, however, did not notice any role of gender on the recurrence pattern. We had an equal number of males and females in the recurrence group. When meningiomas recur, progression to a higher histological grade is relatively uncommon.^[34,35] When this does occur, the change is almost always by only one grade, even with multiple recurrences.^[35] In our study, of ten cases who showed recurrence, seven cases showed only recurrence but no progression to higher grade and three cases showed recurrence with progression by one grade. There is complete agreement in the literature that radical surgery is one of the positive factors influencing the prognosis of benign and malignant meningiomas.^[36,37] The Simpson grading system has been the best-accepted predictor of recurrence since publication of Simpson's landmark article in 1957.^[38]

In our study, of ten cases which recurred, the histopathological examination of these recurrent tumors showed that four were WHO Grade I, 5 were Grade II, and 1 was Grade III lesion [Table 5]. When we studied their Simpson grade of excision, we found that 1 case had Grade I, seven cases had Grade II, and two cases

had Grade III excision [Table 6]. Hence, in our study, we concluded that histological grade is not only the predictor of recurrence but Simpson grade of excision also has a considerable influence on recurrence pattern.

Conclusion

Meningiomas are benign tumors which are more common in females. The supratentorial location is more common than infratentorial, pediatric meningiomas are aggressive, and recurrence of meningiomas depends on the histological grade and Simpson grade of excision.

Financial support and sponsorship

Nil.

Conflicts of interest

There are no conflicts of interest.

References

- Ayerbe J, Lobato RD, de la Cruz J, Alday R, Rivas JJ, Gómez PA, et al. Risk factors predicting recurrence in patients operated on for intracranial meningioma. A multivariate analysis. *Acta Neurochir (Wien)* 1999;141:921-32.
- Coke CC, Corn BW, Werner-Wasik M, Xie Y, Curran WJ Jr. Atypical and malignant meningiomas: An outcome report of seventeen cases. *J Neurooncol* 1998;39:65-70.
- Sutherland GR, Florell R, Louw D, Choi NW, Sima AA. Epidemiology of primary intracranial neoplasms in Manitoba, Canada. *Can J Neurol Sci* 1987;14:586-92.
- Louis DN, Ohgaki H, Otmar DW, Cavenee WK, Burger PC, Jouvet A, et al. The 2007 WHO classification of tumors of the central nervous system. *Acta Neuropathol* 2007;114:97-109.
- Jääskeläinen J, Haltia M, Servo A. Atypical and anaplastic meningiomas: Radiology, surgery, radiotherapy, and outcome. *Surg Neurol* 1986;25:233-42.
- McCarthy BJ, Davis FG, Freels S, Surawicz TS, Damek DM, Grutsch J, et al. Factors associated with survival in patients with meningioma. *J Neurosurg* 1998;88:831-9.
- Riemenschneider MJ, Perry A, Reifenberger G. Histological classification and molecular genetics of meningiomas. *Lancet Neurol* 2006;5:1045-54.
- Germano IM, Edwards MS, Davis RL, Schiffer D. Intracranial meningiomas of the first two decades of life. *J Neurosurg* 1994;80:447-53.
- Solero CL, Fornari M, Giombini S, Lasio G, Oliveri G, Cimino C, et al. Spinal meningiomas: Review of 174 operated cases. *Neurosurgery* 1989;25:153-60.
- Gottfried ON, Gluf W, Quinones-Hinojosa A, Kan P, Schmidt MH. Spinal meningiomas: Surgical management and outcome. *Neurosurg Focus* 2003;14:e2.
- Khurshheed N, Rumana M, Ramzan A. Primary intraosseous meningioma-case of the week. *AJNR Am J Neuroradiol* 2012:e303-4.
- King AT, Sharr MM, Gullan RW, Bartlett JR. Spinal meningiomas: A 20-year review. *Br J Neurosurg* 1998;12:521-6.
- Klekamp J, Samii M. Surgical results for spinal meningiomas. *Surg Neurol* 1999;52:552-62.
- Levy WJ Jr., Bay J, Dohn D. Spinal cord meningioma. *J Neurosurg* 1982;57:804-12.
- Roux FX, Nataf F, Pinaudeau M, Borne G, Devaux B, Meder JF. Intraspinal meningiomas: Review of 54 cases with discussion of poor prognosis factors and modern therapeutic management. *Surg Neurol* 1996;46:458-63.
- Saito T, Arizono T, Maeda T, Terada K, Iwamoto Y. A novel technique for surgical resection of spinal meningioma. *Spine (Phila Pa 1976)* 2001;26:1805-8.
- Younis GA, Sawaya R, DeMonte F, Hess KR, Albrecht S, Bruner JM. Aggressive meningeal tumors: Review of a series. *J Neurosurg* 1995;82:17-27.
- Khurshheed N, Rumana M, Ramzan A, Abrar W. En-plaque spinal meningioma: A rare entity. *Neurosurg Q* 2013;23:61-3.
- Burger PC, Scheithauer BW, Vogel FS. *Surgical Pathology of the Nervous System and Its Coverings*. 3rd ed. London: Churchill Livingstone; 1991. p. 307-571.
- Keppes JJ. *Meningiomas-Biology, Pathology and Differential Diagnosis*. New York: Masson Publishing; 1982. p. 150-522.
- Lantos PL, Vanden Berg SR, Kleihues P. Tumours of the nervous system. In: Graham DI, Lantos PL, editors. *Greenfield's Neuropathology*. 6th ed. London: Arnold; 1996. p. 583-879.
- Mehta N, Bhagwati S, Parulekar G. Meningiomas in children: A study of 18 cases. *J Pediatr Neurosci* 2009;4:61-5.
- Palma L, Celli P, Franco C, Cervoni L, Cantore G. Long-term prognosis for atypical and malignant meningiomas: A study of 71 surgical cases. *J Neurosurg* 1997;86:793-800.
- Mahmood A, Caccamo DV, Tomecek FJ, Malik GM. Atypical and malignant meningiomas: A clinicopathological review. *Neurosurgery* 1993;33:955-63.
- Perry A, Gutmann DH, Reifenberger G. Molecular pathogenesis of meningiomas. *J Neurooncol* 2004;70:183-202.
- Perry A, Scheithauer BW, Stafford SL, Lohse CM, Wollan PC. "Malignancy" in meningiomas: A clinicopathologic study of 116 patients, with grading implications. *Cancer* 1999;85:2046-56.
- Perry A, Stafford SL, Scheithauer BW, Suman VJ, Lohse CM. Meningioma grading: An analysis of histologic parameters. *Am J Surg Pathol* 1997;21:1455-65.
- Boldrey E. The meningiomas. In: Minckler J, editor. *Pathology of the Nervous System*. New York: McGraw-Hill; 1971. p. 2125-44.
- Gupta PK, Sastry Kolluri VR, Das S, Chandra Mouli BA, Narayana Swamy KS, Das BS. Recurrences in meningioma after surgery. *Acta Neurochir (Wien)* 1989;100:104-7.
- Mahmood A, Qureshi NH, Malik GM. Intracranial meningiomas: Analysis of recurrence after surgical treatment. *Acta Neurochir (Wien)* 1994;126:53-8.
- Nakasu S, Nakasu Y, Nakajima M, Matsuda M, Handa J. Preoperative identification of meningiomas that are highly likely to recur. *J Neurosurg* 1999;90:455-62.
- Jääskeläinen J. Seemingly complete removal of histologically benign intracranial meningioma: Late recurrence rate and factors predicting recurrence in 657 patients. A multivariate analysis. *Surg Neurol* 1986;26:461-9.
- Adegbite AB, Khan MI, Paine KW, Tan LK. The recurrence of intracranial meningiomas after surgical treatment. *J Neurosurg* 1983;58:51-6.
- Modha A, Gutin PH. Diagnosis and treatment of atypical and anaplastic meningiomas: A review. *Neurosurgery* 2005;57:538-50.
- Nakasu S, Li DH, Okabe H, Nakajima M, Matsuda M. Significance of MIB-1 staining indices in meningiomas: Comparison of two counting methods. *Am J Surg Pathol* 2001;25:472-8.
- Salmon I, Kiss R, Levivier M, Rimmelink M, Pasteels JL,

- Brotchi J, *et al.* Characterization of nuclear DNA content, proliferation index, and nuclear size in a series of 181 meningiomas, including benign primary, recurrent, and malignant tumors. *Am J Surg Pathol* 1993;17:239-47.
37. Demaerel P, Wilms G, Lammens M, Marchal G, Plets C, Goffin J, *et al.* Intracranial meningiomas: Correlation between MR imaging and histology in fifty patients. *J Comput Assist Tomogr* 1991;15:45-51.
38. Simpson D. The recurrence of intracranial meningiomas after surgical treatment. *J Neurol Neurosurg Psychiatry* 1957;20:22-39.