

## Spontaneous Subdural Hematoma of Dorsal Spine Secondary to Dengue Fever: A Rare Case Report with Review of Literature

### Abstract

A 54-year-old female patient had a sudden onset of febrile illness following which she developed low backache and sudden onset paraplegia with urinary retention. Her hemogram, biochemistry, and coagulation profile was within normal limits. Her dengue serology was positive for IgG antibodies but negative for NS1 Ag. Magnetic resonance imaging of dorsolumbar spine revealed extensive subdural bleed from D6–D12 with cord compression. She underwent emergency laminectomy D6–D12 along with complete evacuation of hematoma. There was complete recovery of sensations in the immediate postoperative period though her motor weakness showed only marginal improvement.

**Keywords:** Dengue, paraplegia, spine, subdural hemorrhage

**Vikas Maheshwari,  
Sanjay Kumar,  
Arun Kumar,  
Ashok Kumar**

*Department of Neurosurgery,  
AFMC, Pune, Maharashtra,  
India*

### Introduction

*De novo* presentation of spontaneous spinal subdural hemorrhage is extremely rare. A multitude of etiologies has been associated with spontaneous spinal subdural hemorrhage. These include bleeding diatheses, drug-induced anticoagulation, vascular malformations or following lumbar puncture,<sup>[1]</sup> epidural anesthesia, and spinal surgery.<sup>[2,3]</sup> Spontaneous dorsal spinal subdural hemorrhage as a complication of dengue fever without thrombocytopenia is a further rare entity. Dengue fever is known to cause multisystemic complications such as bleeding tendencies, renal toxicity, heart failure, and shock and electrolyte abnormalities. However, neurological manifestations in dengue fever occur in <1% of the patients.<sup>[4]</sup> The exact mechanism is still at large but possible incriminated mechanisms are the direct entry of virus into the central nervous system causing metabolic disturbances, bleeding, or virus-induced autoimmune disorders. This results in inflammation, demyelination, and neuronal death.

We report a case who presented with sudden onset of short febrile illness that was diagnosed to have dengue fever (IgG-Positive, NS1 Ag – Negative) and then subsequently developed sudden onset

paraplegia. To the best of our knowledge and from literature review, there has been no earlier reported case of spontaneous dorsal spinal subdural hemorrhage secondary to dengue fever with normal platelet counts.

### Case Report

A 54-year-old female with no known comorbidities and not on any medication had a sudden onset of intermittent high-grade fever with chills and rigors. This was associated with joint pains and severe myalgia. There was no history of hemoptysis, purpuric rashes, weight loss. She was initially hospitalized in a private nursing home. Her hematological investigations revealed hemoglobin of 12.2 g/dl, with leukopenia ( $2.4 \times 10^9/L$ ) and platelet count of 2 lakhs  $mm^3$ . Her coagulation profile and biochemistry parameters were normal. The renal function tests and electrolytes were also within normal limits. Her peripheral blood smear did not show any malarial parasite. NS-1 antigen taken on day 2 of illness was negative but dengue IgG was positive, and IgM was negative. She continued to be febrile, and on day 3 the platelets dropped from 2 lakhs  $mm^3$  to 65,000  $mm^3$ . She was transfused 2 units of platelet and managed with intravenous fluids and supportive care.

She was subsequently discharged on the 8<sup>th</sup> day and the platelet count at the time

This is an open access journal, and articles are distributed under the terms of the Creative Commons Attribution-NonCommercial-ShareAlike 4.0 License, which allows others to remix, tweak, and build upon the work non-commercially, as long as appropriate credit is given and the new creations are licensed under the identical terms.

For reprints contact: reprints@medknow.com

**How to cite this article:** Maheshwari V, Kumar S, Kumar A, Kumar A. Spontaneous subdural hematoma of dorsal spine secondary to dengue fever: A rare case report with review of literature. *Asian J Neurosurg* 2019;14:550-2.

### Address for correspondence:

*Dr. Vikas Maheshwari,  
Department of Neurosurgery,  
AFMC, Pune, Maharashtra,  
India.  
E-mail: drvikas08@rediffmail.  
com*

### Access this article online

**Website:** www.asianjns.org

**DOI:** 10.4103/ajns.AJNS\_228\_18

### Quick Response Code:



of discharge was 180,000 mm<sup>3</sup>. While at home, 4 days later, she suddenly developed numbness and weakness of both lower limbs. She was unable to stand or bear weight on her limbs. She also noticed that there was a complete loss of sensations below the nipple level with inability to void urine. She was at this point of time brought to the emergency department of our hospital. There was no history of fever, seizures, loss of consciousness, altered sensorium, or neck rigidity. On examination, vitals were within normal limits. She was afebrile, and there were no petechiae. The neurological examination revealed flaccid paraplegia with complete sensory loss below D6 spine level and the anal tone was lax. Her hematological profile, coagulation workup, and biochemistry reports were within normal limits. Her urgent magnetic resonance imaging (MRI) Spine [Figure 1a and b] revealed a linear heterogeneously hyperintense signal in spinal canal from D6 to D12 vertebral level suggestive of subdural bleed.

She was taken up for emergency surgery whereby D6–D12 laminectomy was done. Dura was opened; there was a linear streak of clotted blood extending throughout the exposed region restricting the intraoperative visualization of the cord [Figure 2]. This clot was gently teased with blunt and sharp dissection and removed in toto. There was no evidence of vascular abnormality or tumor. The spinal cord could be well visualized with intact arachnoid. Watertight dural closure was done. She had a remarkable recovery of sensory symptoms in the immediate postoperative period with complete restoration of sensations but only a subtle improvement in power of both lower limbs. This possibly could be due to the lamination of the tracts in dorsal spine along with resolution of edema and cord decompression. Her postoperative MRI [Figure 3] showed a complete evacuation of the clot with cord adequately decompressed. She had an uneventful recovery postoperatively and discharged on the 10<sup>th</sup> day.

## Discussion

Dengue fever is a vector-borne ribonucleic acid virus<sup>[5]</sup> with four antigenically distinct serotypes dengue 1–4. It is an important arbovirus in tropical and subtropical regions.<sup>[6,7]</sup> There has been nearly 30 times increase in dengue cases worldwide over the past 5–6 decades.<sup>[8]</sup> The WHO regions of Southeast Asia and Western Pacific constitute nearly 75% of dengue burden globally.<sup>[9]</sup> In India, *Aedes aegypti* and *Aedes albopictus* are the main vectors for dengue virus.<sup>[10]</sup> The Dengue virus is well known to cause hemorrhagic manifestations such as thrombocytopenia, capillary leakage, and various degrees of coagulopathy that have been attributed to these bleeding manifestations. Minor bleeding manifestations such as skin petechiae or bruising are apparent in many patients with dengue hemorrhagic fever, but major hemorrhage is unusual. If severe bleeding does occur, it almost invariably presents with profound or protracted

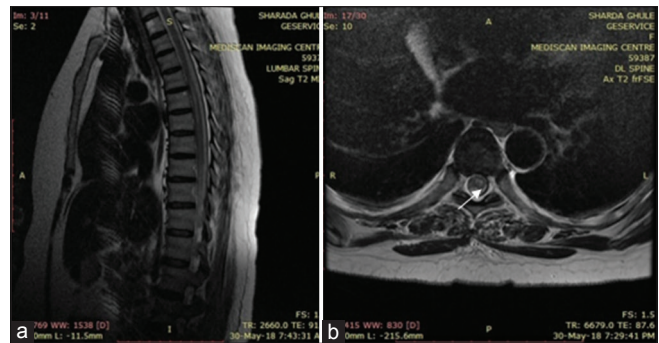


Figure 1: (a) Magnetic resonance imaging sagittal section showing hyperintense signal of cord from D6 to D12. (b) Axial section showing cord pushed to posterolateral aspect

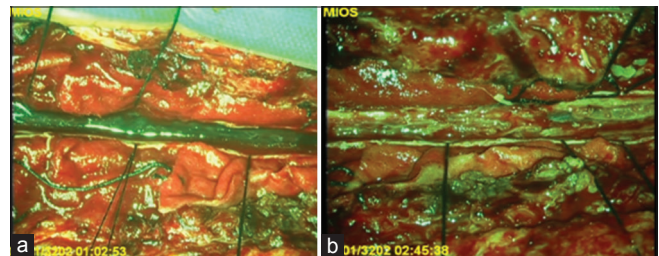


Figure 2: (a) Intraoperative view of hematoma. (b) Spinal cord visualized after the evacuation of hematoma

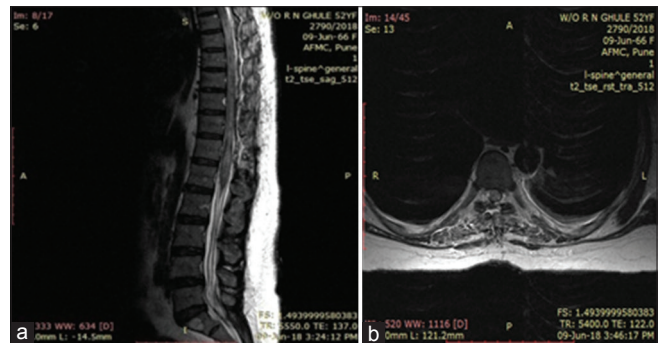


Figure 3: (a and b) – Sagittal and axial postoperative contrast-enhanced magnetic resonance imaging showed complete evacuation of clot

shock with multiorgan failure.<sup>[11]</sup> The neurological complications are rare and comprise <1% of the total systemic complications. The literature search has shown some reported cases of myositis, Guillain–Barre syndrome, myelitis, and hypokalemia secondary to dengue fever.<sup>[12]</sup> An atypical case of hemorrhagic fever presenting as quadriplegia secondary to compressive myelopathy has been mentioned in literature.<sup>[13]</sup> One case of spontaneous spinal subarachnoid hemorrhage has also been reported requiring surgical intervention.<sup>[14]</sup> Both these cases had thrombocytopenia which suggested a higher risk of spontaneous spinal hemorrhage at lower platelet levels. The possible cause of hematoma in our patient may be explained by platelet functional defect which is known to occur in dengue infection despite normal platelet count.

To the best of our knowledge and from literature review, there has been no reported case of spontaneous spinal subdural hemorrhage with normal platelet counts. An early diagnosis in patients of dengue fever presenting with atypical neurological manifestations especially from endemic areas should be made for good neurological recovery. Early surgical decompression during the temporal profile of the disease is mandatory. Our patient underwent emergency surgery on the 12<sup>th</sup> day since the onset of fever. The literature search has shown that the patient of cervical compressive myelopathy was operated on 3<sup>rd</sup> day whereas the case of spinal subarachnoid hemorrhage was operated on the 8<sup>th</sup> day.

### Conclusions

Neurological complications secondary to dengue fever are extremely rare. A high degree of clinical suspicion and prompt diagnosis is essential in alleviating the morbidity and mortality. Further research should be encouraged with regards to pathophysiological mechanisms of dengue infection leading to neurological involvement.

### Declaration of patient consent

The authors certify that they have obtained all appropriate patient consent forms. In the form the patient(s) has/have given his/her/their consent for his/her/their images and other clinical information to be reported in the journal. The patients understand that their names and initials will not be published and due efforts will be made to conceal their identity, but anonymity cannot be guaranteed.

### Financial support and sponsorship

Nil.

### Conflicts of interest

There are no conflicts of interest.

### References

1. Lee JI, Hong SC, Shin HJ, Eoh W, Byun HS, Kim JH, *et al.* Traumatic spinal subdural hematoma: Rapid resolution after repeated lumbar spinal puncture and drainage. *J Trauma* 1996;40:654-5.
2. Gordon WE, Kimball BY, Arthur AS. Traumatic lumbar spinal subdural hematoma. *Interdiscip Neurosurg J* 2014;1:123-7.
3. Cooper J, Gillick JL, LaBagnara M, Das K, Hillard VH. Traumatic lumbar subdural hematoma in the absence of intracranial disease. *World Neurosurg* 2016;90:706.e15-20.
4. Solomon T, Dung NM, Vaughn DW, Kneen R, Thu Thao LT, Raengsakulrach B, *et al.* Neurological manifestations of dengue infection. *Lancet* 2000;355:1053-9.
5. Rodenhuis-Zybert IA, Wilschut J, Smit JM. Dengue virus life cycle: Viral and host factors modulating infectivity. *Cell Mol Life Sci* 2010;67:2773-86.
6. Halstead SB. Dengue. *Lancet* 2007;370:1644-52.
7. Mustafa MS, Rasotgi V, Jain S, Gupta V. Discovery of fifth serotype of dengue virus (DENV-5): A new public health dilemma in dengue control. *Med J Armed Forces India* 2015;71:67-70.
8. World Health Organization Dengue: Guidelines for Diagnosis, Treatment, Prevention and Control: New Edition. Geneva: World Health Organization; 2009.
9. Aguiar M, Rocha F, Pessanha JE, Mateus L, Stollenwerk N. Corrigendum: Carnival or football, is there a real risk for acquiring dengue fever in Brazil during holidays seasons? *Sci Rep* 2015;5:10570.
10. Gubler DJ. Dengue and dengue hemorrhagic fever. *Clin Microbiol Rev* 1998;11:480-96.
11. George R, Lum LC. Clinical spectrum of dengue infection. In: Gubler DJ, Kuno G, editors. *Dengue and Dengue Haemorrhagic Fever*. Wallingford: CAB International; 1997. p. 89-13.
12. Gulati S, Maheshwari A. Atypical manifestations of dengue. *Trop Med Int Health* 2007;12:1087-95.
13. Verma SP, Himanshu D, Tripathi AK, Vaish AK, Jain N. An atypical case of dengue haemorrhagic fever presenting as quadriparesis due to compressive myelopathy. *BMJ Case Rep* 2011;2011. pii: bcr1020103421.
14. Mohd Sharif NH, Misnan NA, Saidon N, Ooi PY, Hashim H. Spontaneous spinal subarachnoid haemorrhage: A rare complication of dengue fever. *J Clin Health Sci* 2017;2:54-7.