

Safe Use of Tissue Plasminogen Activator in Conjunction with the Integra Camino Bolt for the Drainage of Chronic Subdural Hematoma

Abstract

Chronic subdural hematoma (CSDH) is a relatively common condition encountered in a neurosurgical practice. There have been increased efforts in creating different treatment regimens for CSDH to improve patients' outcomes, including the addition of tissue plasminogen activator (tPA) in drains to reduce recurrences. Here, we present the first case report of the safe use of tPA in conjunction with an Integra Camino bolt for maximized drainage of CSDH with a successful neurological recovery and the complete resolution of the hematoma.

Keywords: *Chronic subdural hematoma, integra camino bolt, subdural evacuating port system, surgical decompression, traumatic brain injury*

Introduction

Chronic subdural hematoma (CSDH) is a relatively common condition encountered in a neurosurgical practice with an estimated incidence of 58 per 100,000 and prevalence of 8.2 per 100,000 patients over the age of >65 years.^[1] The incidence of CSDH is expected to increase over the course of the next 25–30 years.^[1,2] Currently, there is no general consensus among the neurosurgical community regarding an optimal treatment protocol for these patients. Treatments for CSDH include burr hole drainage, twist drill drainage, or craniotomy for hematoma evacuation.^[1-3] While craniotomy and burr hole drainage are conducted under general anesthesia in an operating room setting, twist drill drainage can be conducted at the bedside without the need for general anesthesia.^[3-5] Published literature data suggest that both of these drainage procedures lead to similar success with recurrence rates of 21% for burr hole drainage versus 25% for twist drill drainage.^[6] There have been increased efforts in creating different treatment regimens for CSDH to improve patients' outcomes, including the addition of tissue plasminogen activator (tPA) in drains to reduce the recurrence of CSDH.^[1,7,8] Here, we present the first case report of the safe use of tPA in conjunction with an Integra

Camino bolt for maximized drainage of CSDH with a successful neurological recovery and the complete resolution of the hematoma.

Case Report

The patient is an 82-year-old male with a history of coronary artery disease, hypertension, and anxiety who presented with altered mental status after a fall, a week before the admission. Computed tomography (CT) of the head during this admission demonstrated a chronic left subdural hematoma [Figure 1a]. Given symptom and the size of the CSDH, the patient underwent the placement of the Integra Camino bolt to drain the CSDH [Figure 1b]. Due to poor drainage overnight, 0.5 mg of tPA was administered through the bolt to the subdural space to facilitate further drainage of CSDH. Following the administration, the drain was clamped for thirty minutes after which the device was placed back to negative pressure. A total output of 64 mL of oil-like fluid was collected over the course of 2 days at which time the drain was removed [Figure 1c]. At the 2-week neurosurgical follow-up, the patient has improved back to his neurological baseline, and CT of the head demonstrated the complete resolution of the CSDH [Figure 1d].

**Ninh B. Doan,
Mohit Patel,
Ha Son Nguyen,
Hayley Doan,
Andrew Montoure,
Saman Shabani,
Michael Gelsomino,
Karl Janich**

*Department of Neurosurgery,
Medical College of Wisconsin,
Milwaukee, Wisconsin, USA*

Address for correspondence:

*Dr. Ninh B. Doan,
Department of Neurosurgery,
Medical College of
Wisconsin, 9200 W Wisconsin,
Milwaukee, WI 53226, USA.
E-mail: ndoan@mcw.edu*

Access this article online

Website: www.asianjns.org

DOI: 10.4103/ajns.AJNS_230_16

Quick Response Code:



How to cite this article: Doan NB, Patel M, Nguyen HS, Doan H, Montoure A, Shabani S, *et al.* Safe use of tissue plasminogen activator in conjunction with the integra camino bolt for the drainage of chronic subdural hematoma. *Asian J Neurosurg* 2018;13:485-6.

This is an open access journal, and articles are distributed under the terms of the Creative Commons Attribution-NonCommercial-ShareAlike 4.0 License, which allows others to remix, tweak, and build upon the work non-commercially, as long as appropriate credit is given and the new creations are licensed under the identical terms.

For reprints contact: reprints@medknow.com

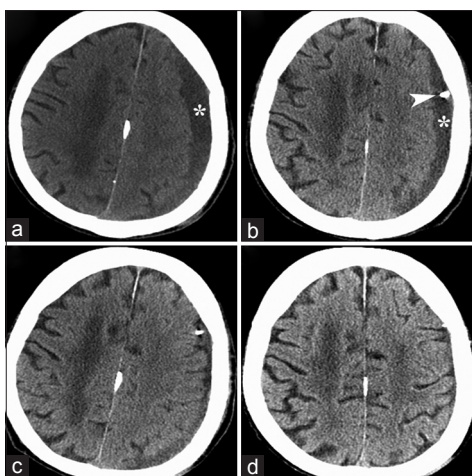


Figure 1: Computed tomography of the head demonstrates a left chronic subdural hematoma, which is indicated by the asterisk, the initial scan (a), the next day scan, following the placement of the Integra Camino bolt, reveals a minimal drainage of the chronic subdural hematoma with the arrow points at the tip of the bolt, which is within the subdural space (b), the next day scan, following the administration of tissue plasminogen activator through the bolt into the subdural space, reveals the almost complete evacuation of the chronic subdural hematoma (c), the 2-week interval scan demonstrates a complete evacuation of the chronic subdural hematoma with the restoration of well-visualized sulci and gyri (d)

Discussion

Current literature shows that both a twist drill drainage and burr hole drainage are adequate options in the treatment of CSDH with no statistical differences and that the placement of drains for postoperative drainage decreases recurrent rates by up to 60%.^[9] In fact, a drainage of at least >200 mL has been shown to decrease recurrent rates.^[10] There have been multiple efforts on introducing new changes to improve patients' outcomes such as an introduction of a hollow screw such as a subdural evacuating port system (SEPS) to improve draining of the hematoma and decrease complications.^[7,8] Furthermore, we recently proposed a novel, easy-to-do, low-cost technique on using the widely available Integra Camino bolt as a hollow screw to achieve similar outcomes compared to SEPS. In an effort to improve outcomes, recent research comparing the recurrent rates of patients who underwent evacuation of CSDH with tPA and without tPA demonstrated that patients who underwent evacuation

with tPA had zero recurrence compared to 22.5% recurrent rates in patients who did not receive tPA.^[1] In this report, we present the first case report of the safe use of tPA in conjunction with an Integra Camino bolt for maximized drainage of CSDH with a successful neurological recovery and the complete resolution of the hematoma [Figure 1].

Financial support and sponsorship

Nil.

Conflicts of interest

There are no conflicts of interest.

References

1. Neils DM, Singanallur PS, Wang H, Tracy P, Klopfenstein J, Dinh D, *et al.* Recurrence-free chronic subdural hematomas: A retrospective analysis of the instillation of tissue plasminogen activator in addition to twist drill or burr hole drainage in the treatment of chronic subdural hematomas. *World Neurosurg* 2012;78:145-9.
2. Cenic A, Bhandari M, Reddy K. Management of chronic subdural hematoma: A national survey and literature review. *Can J Neurol Sci* 2005;32:501-6.
3. Santarius T, Kirkpatrick PJ, Koliass AG, Hutchinson PJ. Working toward rational and evidence-based treatment of chronic subdural hematoma. *Clin Neurosurg* 2010;57:112-22.
4. Chari A, Koliass AG, Santarius T, Bond S, Hutchinson PJ. Twist-drill craniostomy with hollow screws for evacuation of chronic subdural hematoma. *J Neurosurg* 2014;121:176-83.
5. Tabaddor K, Shulmon K. Definitive treatment of chronic subdural hematoma by twist-drill craniostomy and closed-system drainage. *J Neurosurg* 1977;46:220-6.
6. Horn EM, Feiz-Erfan I, Bristol RE, Spetzler RF, Harrington TR. Bedside twist drill craniostomy for chronic subdural hematoma: A comparative study. *Surg Neurol* 2006;65:150-3.
7. Asfora WT, Schwebach L. A modified technique to treat chronic and subacute subdural hematoma: Technical note. *Surg Neurol* 2003;59:329-32.
8. Emonds N, Hassler WE. New device to treat chronic subdural hematoma – hollow screw. *Neurol Res* 1999;21:77-8.
9. Liu W, Bakker NA, Groen RJ. Chronic subdural hematoma: A systematic review and meta-analysis of surgical procedures. *J Neurosurg* 2014;121:665-73.
10. Kwon TH, Park YK, Lim DJ, Cho TH, Chung YG, Chung HS, *et al.* Chronic subdural hematoma: Evaluation of the clinical significance of postoperative drainage volume. *J Neurosurg* 2000;93:796-9.