

Pharyngocutaneous Fistula and Horner's Syndrome following Loosening of Locking Screw of Anterior Cervical Plating: A Rare Case Report and Management

Abstract

We hereby present a rare case of pharyngocutaneous fistula associated with locking screw loosening causing internal cricopharynx perforation and Horner's syndrome following anterior cervical plating. A 27-year-old male patient had undergone anterior cervical plating at C5–C7 level due to gunshot injury to the neck, and 1 month postsurgery, he developed fistula in the neck showing discharge of consumed food contents. He presented to us 1 year postsurgery with the discharging fistula, left upper-limb weakness, and Horner's syndrome that developed after surgery. The previously unexplored right side was used to remove implant, and owing to solid union at corpectomy, no additional fixation was performed. Intraoperatively, pharyngeal wall dehiscence was observed. Attempt of removal of impinged screw was abandoned since it migrated into the esophagus. Serial abdomen radiographs revealed successive passage of screw through the gastrointestinal (GI) tract until it could not be visualized. As the patient showed reduced discharge, a GI surgeon gave a conservative trial with nasogastric intubation. Currently, fistula is showing minimal discharge with no food. Having knowledge of this possible rare outcome and awareness of various multidisciplinary approaches for management makes practicing spine surgeon equipped to handle such undesirable complications.

Keywords: Anterior cervical plating, fistula, locking mechanism

Introduction

The use of anterior cervical approach for spinal surgery pioneered by Smith and Robinson,^[1] Bailey and Badgley,^[2] and Cloward^[3,4] is a commonly performed procedure. Although it is relatively safe and has acquired extensive approval for high fusion rate,^[5,6] still it is known to be associated with rare serious potentially life-threatening complications. We hereby present a rare case of pharyngocutaneous fistula associated with loosening of locking screw causing internal perforation of the cricopharynx and Horner's syndrome following anterior cervical plating in a 27-year-old male.

Case Report

A 27-year-old man presented with complaints of left upper-limb weakness and discharge from neck wound containing contents of consumed food and liquid occurring for 1 year (see additional file

1 for the video of discharge of consumed food and liquid from neck wound). He had well-established features of Horner's syndrome such as ptosis, miosis, anhidrosis, and enophthalmos developed probably due to the loosening of the locking screw about 1 month postsurgery. He had sustained a gunshot injury to his neck 1 year back. For management of the gunshot injury, the patient underwent anterior cervical plating at C5–C7 vertebral level in hospital at his native place. One month postsurgery, he developed a fistula in the neck which started discharging consumed food and liquids [Figure 1]. Clinically sprouting granulation tissue was present at the opening of the fistula, located in the left suprasternal area. Neurological examination revealed left upper-limb reduced handgrip strength. His preoperative imaging workup included plain radiographs, computed tomography (CT) scan, upper gastrointestinal (GI) endoscopy, and barium swallow. Plain radiographs

**Abhinav Jogani,
Tushar Rathod,
Nandan Marathe,
Shubhranshu
Mohanty,
Chetan Shende**

*Department of Orthopaedics,
Seth G.S. Medical College
and KEM Hospital, Mumbai,
Maharashtra, India*

Address for correspondence:

*Dr. Abhinav Jogani,
Dr Tushar Rathod, 6th
Floor, MS Building, KEM
Hospital, Parel, Mumbai-12,
Maharashtra, India.
E-mail: tnrathod@gmail.com*

Video available on: www.asianjns.org

Access this article online

Website: www.asianjns.org

DOI: 10.4103/ajns.AJNS_230_19

Quick Response Code:



This is an open access journal, and articles are distributed under the terms of the Creative Commons Attribution-NonCommercial-ShareAlike 4.0 License, which allows others to remix, tweak, and build upon the work non-commercially, as long as appropriate credit is given and the new creations are licensed under the identical terms.

For reprints contact: WKHLRPMedknow_reprints@wolterskluwer.com

How to cite this article: Jogani A, Rathod T, Marathe N, Mohanty S, Shende C. Pharyngocutaneous fistula and horner's syndrome following loosening of locking screw of anterior cervical plating: A rare case report and management. *Asian J Neurosurg* 2021;16:196-9

Submitted: 18-Jul-2019 **Revised:** 14-Sep-2019
Accepted: 26-Mar-2020 **Published:** 23-Feb-2021

revealed loosening of the anterior cervical plate with displaced locking screw [Figure 2]. On GI endoscopy, the presence of a displaced locking screw mechanism was causing internal perforation of the posterior aspect of the cricopharynx [Figure 3]. Barium swallow examination revealed extrusion of the dye through the fistula on the anterior aspect of the neck.

Indirect laryngoscopy was done to ensure the integrity of the vocal cords. Considering excessive scarring and presence of active discharge through fistula on the left side, the previously unexplored right side was used for anterior cervical spine surgery. Intraoperatively, pharyngeal wall dehiscence was observed. Considerably large defect in the posterior pharyngeal wall was noted. Endotracheal (ET) tube and Ryle's tube could be seen traversing through the deficient part of the posterior pharyngeal wall. Widespread adhesions between the implant and the overlying structures were released through sharp surgical dissections, and cervical plate was removed. On further exploration, dense fibrosis was noted around the locking screw in the cricopharynx. After failed attempt of removal of impinged cricopharyngeal screw, it was found to be migrated in the esophageal lumen through the pharynx. This migration of the screw may be attributed to the deficient posterior pharyngeal wall. Hence, its removal attempt was abandoned. Preoperative CT scan as well as intraoperative exploration of fusion mass showed solid union at the corpectomy site; hence, no additional fixation was performed. The patient was shifted postoperatively to the intensive care unit where he was mobilized on T-piece intubation. On giving a trial of deflation of the cuff of ET tube, the patient was experiencing breathlessness due to the collapse of the pharyngeal wall. A plan of prophylactic tracheostomy was made. Serial radiographs of the abdomen revealed successive passage of the screw through the gastrointestinal tract (GIT) until finally it could no longer be visualized [Figure 4]. Later, tracheostomy was weaned off. As the patient showed reduced discharge postoperatively, the GI surgery department gave a conservative trial for fistula to heal with nasogastric intubation. Currently, the original fistula is showing minimal discharge with no contents of food [Figure 5]. At 2-year follow-up, the fistula has almost healed with no discharge of consumed food or liquid.

Discussion and Conclusion

Implant loosening is known to occur following anterior cervical spine instrumentation. There are various case reports of oral extrusion of screw or plate loosening causing pharyngeal wall dehiscence. However, in our case, there was loosening of locking screw causing perforation of the cricopharyngeal wall which has not been reported till date. It was a sharp locking screw which migrated from the left to right side and invaded the cricopharyngeal wall from outside-in manner.

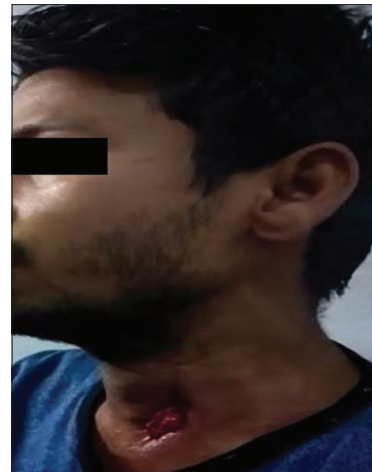

Figure 1: Clinical photograph revealing sprouting granulation tissue at the opening of the fistula located in the left suprasternal area

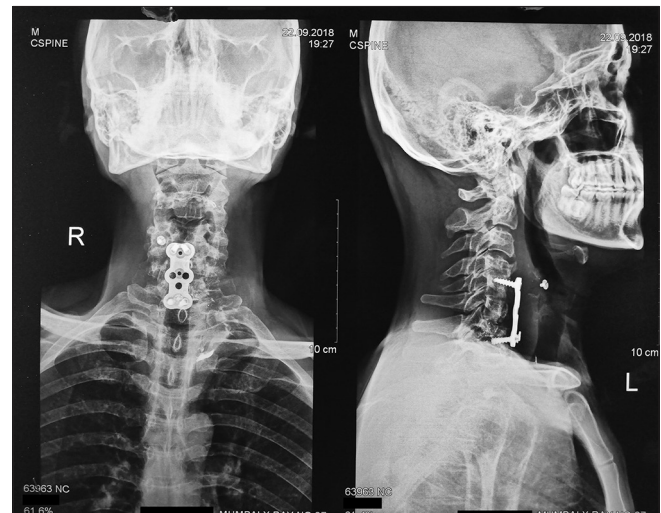

Figure 2: Anteroposterior and lateral radiograph of the cervical spine revealing loose anterior cervical plate extending from C5 to C7 vertebra. Furthermore, the locking screw can be seen abutting the posterior wall of the pharynx

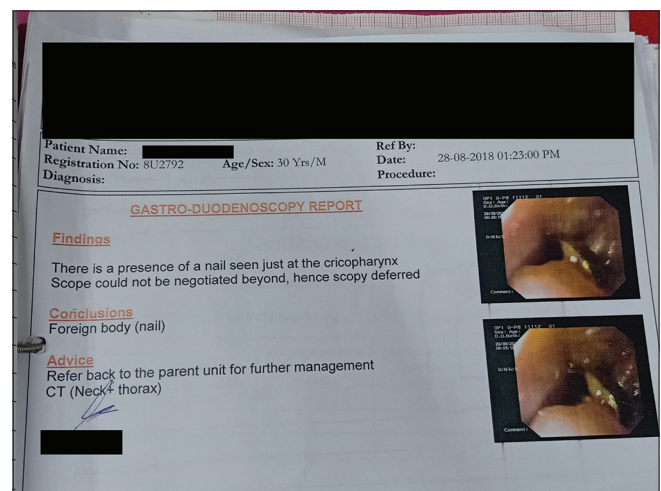


Figure 3: Gastrointestinal endoscopy report showing screw lodged in the cricopharynx

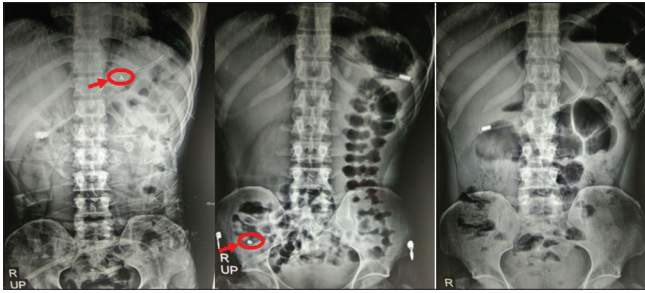


Figure 4: Serial radiographs of the abdomen revealing successive passage of the screw through the gastrointestinal tract until finally it could no longer be visualized in the last radiograph

The patient had persistent pharyngocutaneous fistula discharging food contents. Pharyngocutaneous fistulae are unusual complications of anterior cervical surgery for which literature quotes the rates to be <0.1% of all anterior cervical surgery cases.^[7] Newhouse *et al.*^[8] mentioned the most common level of perforation being C5–C6 as this level corresponds with pharynx and its transition to the esophagus. Our case had instrumentation being done at the same level. Apart from transition, the thickness of the pharyngeal wall is less in this region compared to other regions making it vulnerable to injury. There are two mechanisms of injury to the pharynx which leads to the formation of pharyngocutaneous fistula postinjury/surgery. The first one can occur following primary injury due to sudden hyperextension injury to the pharyngeal wall along with spinal injury. This leads to tear in the posterior pharyngeal wall and can be missed easily unless high index of suspicion is exercised for it. The second one can occur due to intraoperative pharyngeal wall dehiscence by inadvertent retraction of the pharyngeal wall along with sharp instrumentation technique like the use of burr. Unfortunately, such injury is not evident unless specifically looked for intraoperatively by various maneuvers such as methylene blue dye insertion.

Development of late pharyngocutaneous fistula can occur due to perforation by implant or loose screw. This mode of late perforation of the upper GIT due to implant loosening is very rare nowadays with the advent of low-profile ergonomic designs of the Anterior Cervical Plating (ACP) system. As our patient did not have any records of index surgery, it was difficult to speculate any reason for fistula formation in our case. However, history suggested of continuous discharge from surgical wound culminating later in fistula formation. Hence, we suspect it to be case of intraoperative pharyngeal wall dehiscence. Wound infection, fever, salivary discharge from wound, mediastinitis, and features of sepsis in immediate postoperative period are suggestive of visceral injury to pharynx or esophagus depending on the level of surgery. GI endoscopy along with imaging like CT scan and barium swallow delineates defect and confirms diagnosis. As our case presented to us 1 year after index surgery, treatment strategy differed from

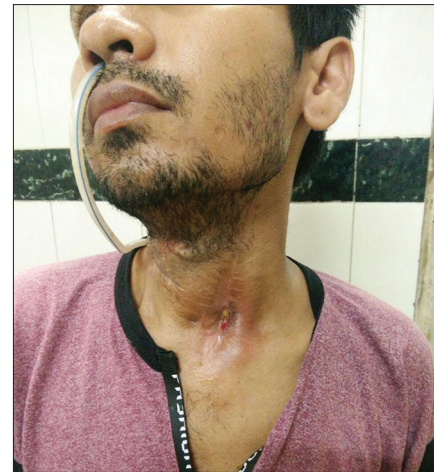

Figure 5: Latest clinical photograph of the patient showing healing wound and nasogastric intubation

acute presentation of fistula where direct/primary repair of the pharyngeal wall is the mainstay of treatment.^[9]

Handling of late presentation of pharyngocutaneous fistula requires a multidisciplinary approach. As per GI surgeons, controlling infection was the first step before they could consider any form of reconstruction. Hence, a combined plan for implant removal was done including removal of cricopharyngeal screw. Intraoperatively, a considerably large defect in the posterior pharyngeal wall was noted. Postoperatively, discharge from the neck reduced significantly. ENT and GI surgeons who considered option of local muscle flap preimplant removal decided to give conservative treatment for fistula by nasogastric feeding. The patient responded well to the above treatment with minimal discharge and complete stoppage of food contents in discharge.

Usually, chronic pharyngocutaneous fistula requires the use of local sternocleidomastoid muscle^[10,11] or omohyoid flap along with VAC application to keep salivary secretions away from the site of repair. Sternocleidomastoid flap detached from the clavicular end is preferred option because of the ease of access, easy mobilization, and reduced chances of microthrombosis in its vasculature. There are anecdotal case reports in literature about the management of pharyngocutaneous fistula with no major series of more than five patients.^[12,13]

The presence of plate locking screw in the cricopharynx highlights the necessity of robust locking mechanism for screws in plate with quality control during manufacturing process. The patient also showed features of Horner's syndrome due to damage to the sympathetic chain during index surgery which was managed in consultation with an ophthalmologist. This highlights careful precautions needed to dissect longus colli subperiosteally with minimal use of thermal coagulation over the surface of muscle to avoid damage to sympathetic chain. As we had interbody

fusion noted both intraoperatively after removal of anterior cervical plate and on preoperative CT scan, we did not require further posterior instrumentation.

Conclusion

This case report highlights a rare complication of faulty locking screw invading the cricopharyngeal wall along with postoperative pharyngocutaneous fistula discharging food contents following suspected intraoperative injury to the pharyngeal wall.

Clinical Message

Having knowledge of this possible rare outcomes and awareness of various multidisciplinary approaches for their management makes practicing spine surgeon equipped to handle such undesirable complications.

Financial support and sponsorship

Nil.

Conflicts of interest

There are no conflicts of interest.

References

1. Smith GW, Robinson RA. The treatment of certain cervical-spine disorders by anterior removal of the intervertebral disc and interbody fusion. *J Bone Joint Surg Am* 1958;40-A:607-24.
2. Bailey RW, Badgley CE. Stabilization of the cervical spine by anterior fusion. *J Bone Joint Surg Am* 1960;42-A:565-94.
3. Cloward RB. Vertebral body fusion for ruptured cervical discs. *Am J Surg* 1959;98:722-7.
4. Cloward RB. Treatment of acute fractures and fracture-dislocations of the cervical spine by vertebral-body fusion. A report of eleven cases. *J Neurosurg* 1961;18:201-9.
5. Kaiser MG, Haid RW Jr., Subach BR, Barnes B, Rodts GE Jr. Anterior cervical plating enhances arthrodesis after discectomy and fusion with cortical allograft. *Neurosurgery* 2002;50:229-36.
6. Panjabi MM, Isomi T, Wang JL. Loosening at the screw-vertebra junction in multilevel anterior cervical plate constructs. *Spine (Phila Pa 1976)* 1999;24:2383-8.
7. Cloward RB. Complications of anterior cervical disc operation and their treatment. *Surgery* 1971;69:175-82.
8. Newhouse KE, Lindsey RW, Clark CR, Lieponis J, Murphy MJ. Esophageal perforation following anterior cervical spine surgery-CSRS survey. *Spine* 1989;14:1051-3.
9. Simon C, Fürstenberg CH, Eichler M, Rohde S, Bulut C, Wiedenhöfer B. Management of Pharyngeal Fistulas After Anterior Cervical Spine Surgery: A Treatment Algorithm for Severe Complications. *Clin Spine Surg* 2017;30:E25-30.
10. Iyoob VA. Postoperative pharyngocutaneous fistula: Treated by sternocleidomastoid flap repair and cricopharyngeus myotomy. *Eur Spine J* 2013;22:107-12.
11. Navarro R, Javahery R, Eismont F, Arnold DJ, Bhatia NN, Vanni S, *et al.* The role of the sternocleidomastoid muscle flap for esophageal fistula repair in anterior cervical spine surgery. *Spine (Phila Pa 1976)* 2005;30:E617-22.
12. Benazzo M, Spasiano R, Bertino G, Occhini A, Gatti P. Sternocleidomastoid muscle flap in esophageal perforation repair after cervical spine surgery: Concepts, techniques, and personal experience. *J Spinal Disord Tech* 2008;21:597-605.
13. Al-Mourgi M. Sternocleidomastoid flap for repair of pharyngocutaneous fistula following anterior cervical spine surgery. *Saudi J Health Sci* 2015;4:199-201.