

The Utility of Cervical Spine Bracing as a Postoperative Adjunct to Single-level Anterior Cervical Spine Surgery

Abstract

Background Context: Use of cervical bracing/collar subsequent to anterior cervical spine discectomy and fusion (ACDF) is variable. Outcomes data regarding bracing after ACDF are limited. **Purpose:** The purpose of the study is to study the impact of bracing on short-term outcomes related to safety, quality of care, and direct costs in single-level ACDF. **Study Design/Setting:** This retrospective cohort analysis of all consecutive patients ($n = 578$) undergoing single-level ACDF with or without bracing from 2013 to 2017 was undertaken. **Methods:** Patient demographics and comorbidities were analyzed. Tests of independence (Chi-square, Fisher's exact, and Cochran–Mantel–Haenszel test), Mann–Whitney–Wilcoxon tests, and logistic regressions were used to assess differences in length of stay (LOS), discharge disposition (home, assisted rehabilitation facility, or skilled nursing facility), quality-adjusted life year (QALY), surgical site infection (SSI), direct cost, readmission within 30 days, and emergency room (ER) visits within 30 days. **Results:** Among the study population, 511 were braced and 67 were not braced. There was no difference in graft type ($P = 1.00$) or comorbidities ($P = 0.06$ – 0.73) such as obesity ($P = 0.504$), smoking (0.103), chronic obstructive pulmonary disease hypertension ($P = 0.543$), coronary artery disease ($P = 0.442$), congestive heart failure ($P = 0.207$), and problem list number ($P = 0.661$). LOS was extended for the unbraced group (median $34.00 + 112.15$ vs. $77.00 + 209.31$ h, $P < 0.001$). There was no difference in readmission ($P = 1.000$), ER visits ($P = 1.000$), SSI ($P = 1.000$), QALY gain ($P = 0.437$), and direct costs ($P = 0.732$). **Conclusions:** Bracing following single-level cervical fixation does not alter short-term postoperative course or reduce the risk for early adverse outcomes in a significant manner. The absence of bracing is associated with increased LOS, but cost analyses show no difference in direct costs between the two treatment approaches. Further evaluation of long-term outcomes and fusion rates will be necessary before definitive recommendations regarding bracing utility following single-level ACDF.

Keywords: Anterior cervical discectomy and fusion, cervical fixation, single-level bracing

Introduction

Anterior cervical discectomy and fusion (ACDF) is performed approximately 132,000 times a year in the United States.^[1] ACDF has wide-ranging indications, including cervical radiculopathy, myelopathy, degenerative disc disease, and degenerative spondylolysis with similar or improved fusion rates and low rates of subsidence compared to noninstrumented techniques.^[2–9] Frequently, patients are placed in a cervical brace postoperatively for a variable amount of time. Since the popularization of anterior plating, the utility of postoperative bracing has been debated, and there is a wide disparity in surgeon use.^[10]

Proponents of postoperative bracing suggest that using an external orthosis

will decrease axial load on the construct and thereby reduce the risk of pseudarthrosis, graft subsidence, and adjacent segment disease even in the presence of an anterior plate.^[11,12] Critics of bracing believe that the internal fixation afforded by an ACDF, in part due to continuing improvements in hardware, obviates any requirement for external bracing.^[13] Biomechanical analyses of cervical orthoses have produced evidence to suggest that bracing leads to a change in gait affecting patient quality of life or safety,^[14–16] although this finding remains contentious.^[17–19] Other studies have demonstrated that cervical braces are associated with dysphagia,^[20] pressure ulcers,^[21] and respiratory compromise.^[22]

There is evidence to suggest that short-term use of cervical bracing following ACDF

How to cite this article: Caplan I, Sinha S, Schuster J, Piazza M, Glauser G, Osiemo B, *et al.* The utility of cervical spine bracing as a postoperative adjunct to single-level anterior cervical spine surgery. *Asian J Neurosurg* 2019;14:461–6.

Ian Caplan¹,
Saurabh Sinha¹,
James Schuster¹,
Matthew Piazza^{1,2},
Gregory Glauser¹,
Benjamin Osiemo^{3,4},
Scott McClintock⁴,
William C. Welch¹,
Nikhil Sharma¹,
Ali Ozturk¹,
Neil Rainer
Malhotra^{1,2}

¹Department of Neurosurgery, Perelman School of Medicine, University of Pennsylvania, ²Departments of Neurosurgery and Orthopedic Surgery, Translational Spine Research Laboratory, University of Pennsylvania, ³Department of Neurosurgery, McKenna EpiLog Fellowship in Population Health, University of Pennsylvania, Philadelphia, ⁴Department of Mathematics, West Chester Statistical Institute, West Chester University, West Chester, PA, USA

Address for correspondence:
Dr. Neil Rainer Malhotra,
Department of Neurosurgery,
Perelman School of Medicine,
University of Pennsylvania,
3400 Spruce Street, 3rd Floor
Silverstein Pavilion,
Philadelphia, PA 19104, USA.
E-mail: neil.malhotra@uphs.
upenn.edu

Access this article online

Website: www.asianjns.org

DOI: 10.4103/ajns.AJNS_236_18

Quick Response Code:



This is an open access journal, and articles are distributed under the terms of the Creative Commons Attribution-NonCommercial-ShareAlike 4.0 License, which allows others to remix, tweak, and build upon the work non-commercially, as long as appropriate credit is given and the new creations are licensed under the identical terms.

For reprints contact: reprints@medknow.com

correlates with improvements in pain and short-term patient-reported outcomes.^[23] Yet other studies report no differences in surgical results.^[24,25] Although there are conflicting opinions, cervical bracing is regularly used in the setting of single-level ACDF.^[26,27] The current data regarding implementation of postoperative cervical bracing are somewhat equivocal and the current body of literature lacks adequate data for surgeon decision-making as to the use of cervical bracing subsequent to single-level surgery. We sought to clarify these uncertainties by analyzing short-term outcomes after single-level ACDF cases and the associated direct costs related to cervical bracing.

Methods

Study population

In this Institutional Review Board (IRB) approved the study, patients undergoing single-level ACDF surgical intervention across a university health system were enrolled retrospectively from July 1, 2013 to June 30, 2017. A waiver of informed consent was granted by the IRB as this study was considered to be minimal risk to patients. The Neurosurgery Quality Improvement Initiative (NQII) EpiLog tool provided prospective data acquisition on consecutive patients ($n = 577$) undergoing single-level ACDF between 2013 and 2017. Briefly, the NQII EpiLog tool is a nonproprietary clinical research and quality improvement architecture that was built and overlaid onto the electronic health record system and enables prospective data collection.

Data collection

Patients' data were collected through the NQII EpiLog tool from the electronic health record. Patient age, gender, race, and American Society of Anesthesiologists (ASA) score that rates perfect health as 1 and moribund as 5, and multiple common medical comorbidities, including diabetes, chronic obstructive pulmonary disease (COPD), coronary artery disease (CAD), and total number of preoperative medical comorbidities, which sums total adjacent diagnoses at the time of index surgery as surrogate for patient disease severity were recorded [Table 1]. Length of stay (LOS) [Table 2], discharge disposition, emergency room (ER) visit within 30 days, and readmission within 30 days were also recorded [Figure 1]. Of the total 577 patients included in the final study, a small cohort of patients ($n = 74$) prospectively completed the EQ-5D-3 L questionnaire, a validated measure of health outcomes for cost-utility analysis, to calculate quality-adjusted life years (QALY). Total cost was calculated as all actual costs directly incurred by the hospital, retrieved from billing databases [Table 2].

Statistical analysis

All continuous variables were assessed with the Student *t*-test or Wilcoxon rank-sum test where appropriate. All categorical variables were analyzed with Pearson's

Chi-square test or Fisher's exact test. Multinomial logistic regression analyses were used to determine disposition location based on independent variable of bracing. Significant results were defined as $P < 0.05$. Averages are presented as mean \pm standard deviation.

Results

Patient demographics

The retrospective cohort analysis consisted of patients who underwent single-level ACDF ($n = 577$), where 509 patients were braced and 68 were unbraced [Table 1]. There was a significant difference in gender, as men were less frequently braced than women ($P = 0.017$). Among the study population, there was no difference between the braced and unbraced cohorts with regard to race ($P = 0.299$) or age (52 vs. 51 years, $P = 0.540$). There were no differences in patient comorbidities including diabetes, COPD, CAD, obesity, smoking, body mass index, or total comorbidities. There were significant differences in the overall physical status of patients as defined by the ASA score with more ASA two patients in the braced cohort and more ASA three patients in the unbraced cohort ($P = 0.010$). Among the study population, there was a difference in graft type where unbraced patients received allograft more often than the braced patients ($P < 0.0001$).

Safety of care

LOS was extended for the unbraced cohort compared to the braced cohort (152.7 ± 209.3 vs. 72.63 ± 112.5 h, $P < 0.0001$). Discharge disposition for the two populations differed, with the braced cohort being 4.05 times more likely to be discharged home than to an assisted rehabilitation facility or a skilled nursing facility in comparison to the unbraced cohort ($P < 0.001$, confidence interval = 2.2771–7.2169). Readmissions within 30 days ($P = 0.828$) and ER visits within 30 days were no differences between the two groups ($P = 1.000$), as shown in Figure 1.

Quality and cost-effectiveness

Patient QALY gain, at 3.7 months, was no difference between the two groups ($P = 0.080$). Assessment of total costs also showed no difference between bracing and not bracing patients following ACDF ($P = 0.709$) [Table 2].

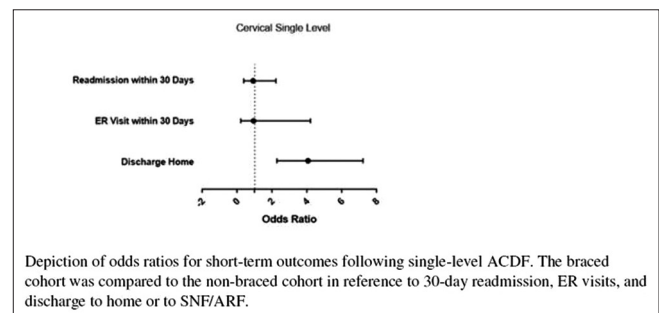


Figure 1: Short-term postoperative risk assessment

Table 1: Patient demographics and comorbidities

Variable	Brace, n (%)	No Brace, n (%)	P
Sex			0.0171
Male	251 (49.31)	44 (64.71)	
Female	258 (50.69)	24 (35.29)	
Diabetes	17 (3.71)	4 (7.02)	0.2743
COPD	2 (0.44)	2 (3.51)	0.0624
CAD	4 (0.87)	1 (1.75)	0.4451
Obesity	5 (1.09)	1 (1.74)	0.5071
CHF	1 (0.22)	1 (1.75)	0.2093
HTN	43 (9.39)	7 (12.28)	0.4868
Smoker	88 (17.46)	15 (26.32)	0.1017
Race			0.2986
Asian	4 (.79)	1 (1.47)	
Black	85 (16.70)	18 (26.47)	
White	393 (77.21)	44 (64.71)	
HLB	5 (0.98)	0 (0.0)	
HLW	4 (0.79)	0 (0.0)	
Unknown	10 (1.96)	4 (5.88)	
Other	6 (1.18)	1 (1.47)	
Pacific Island	1 (0.20)	0 (0.0)	
East Indian	1 (0.20)	0 (0.0)	
ASA Grade			0.0101
ASA 1	20 (3.93)	2 (2.94)	
ASA 2	292 (57.37)	33 (48.53)	
ASA 3	193 (37.92)	29 (42.65)	
ASA 4	4 (0.79)	4 (5.88)	
Graft Type			<0.0001
Allograft	263 (51.67)	61 (89.71)	
Autograft	147 (28.88)	0 (0.0)	
Biomechanical	57 (11.20)	0 (0.0)	
Allograft + Autograft	2 (0.39)	0 (0.0)	
Autograft + Biomechanical	17 (3.34)	1 (0.01)	
None	23 (4.52)	6 (8.82)	
	Mean (SD)	Mean (SD)	
Pack years	18.60 (14.07)	19.88 (11.80)	0.7249
Total number of comorbidities	4.73 (5.44)	4.87 (5.34)	0.6444
BMI	29.03 (6.06)	28.24 (5.74)	0.3183
Duration of follow-up	233.1 (283.4)	374.5 (357.9)	0.4481
Age	52.13 (12.07)	50.99 (14.69)	0.5402

Table 2: Comparison of quality and cost of care

Variable	Brace, mean (SD)	No Brace, mean (SD)	P
LOS	72.63 (112.5)	152.7 (209.3)	<0.0001
Total cost	2722.0 (1784.9)	2924.7 (2933.5)	0.7091
QALY	0.0303 (0.0736)	-0.0650 (0.1344)	0.0798

Discussion

The present analyses show decreased LOS and increased the frequency of home discharge for braced patients, but otherwise, indicate no difference in short-term outcomes or cost between the braced and unbraced cohorts. The use of cervical orthoses remains commonplace after cervical spine operation. Following early forms of ACDF and other cervical spine surgeries where internal stabilization

could not convincingly be achieved, cervical bracing was commonly used.^[28] With improvements in hardware, surgical technique, and efficacy of ACDF, one might have expected the rate of postoperative bracing to decline. However, the paucity of decisive literature has made informed decision-making challenging in the setting of single-level ACDF.

The recent literature includes several studies that assess the utility of bracing following instrumented or noninstrumented ACDF for multiple clinical indications. Campbell *et al.* demonstrated that bracing following single-level allograft ACDF did not confer any additional benefit in radiographic fusion or patient-reported quality of life.^[29] A meta-analysis performed by Camara *et al.*

analyzed seven previous studies of which only one showed that bracing was advantageous. The conclusions of the other six studies were divided between no benefit or unknown benefit.^[30] Another meta-analysis by Zhu *et al.* asked whether bracing was effective as measured by patient-reported efficacy, radiographic outcomes, safety, and cost-effectiveness. From five analyzed studies, there was no evidence to support bracing in improving patient outcome scores, radiographic fusion rates, or lowering complication rates.^[31]

Recent studies describe equivocal fusion rates in comparisons of braced and unbraced patients following ACDF, but due to the historically mixed data and few prospective studies, there is not yet sufficient evidence for a complete change in practice. In an analysis of cervical motion following ACDF, it was found that motion was detectable 2-week post-ACDF and that motion was independent of the number of levels fused.^[32] As an example of how these biomechanics may affect outcomes, it is well established that smoking has negative consequences on bone health and healing.^[33] This translates into lower fusion rates, increased rates of pseudarthrosis, and overall worse outcomes for these patients.^[34-37] For these patients, the above described postoperative motion may be a significant contributor to poor surgical outcomes given a poor protoplasm, and these patients may require the additional support of a cervical brace. The decision to brace may thus be better approached in an individualized manner with consideration of specific comorbidities and corresponding likelihood of complications for a given patient.

For a majority of the population, however, the current study is consistent with prior work, indicating that bracing does not afford superior outcomes in the setting of ACDF.^[24,25,29-31] Although a previous trial demonstrated no radiographic or self-reported health differences between braced and unbraced cohorts, the study assessed a subset of single-level ACDF patients and did not investigate differences in follow-up care.^[29] Here, we aimed to delineate the utility of postoperative bracing following single-level ACDF and found no difference in short-term complication rates, ER visits, or 30-day readmissions. These short-term results suggest that foregoing bracing after single-level ACDF would not affect short-term outcomes. In this study, the variation in cervical instrumentation and lack of specificity for bracing procedures are purposefully ill-defined. Actual surgical practice includes inherent differences in surgical planning for each case and the data used reflect this variability in practice for appropriate external validity. Therefore, the results of this study further support the nonsuperiority of bracing after single-level ACDF is consistent across varied operative choices.^[38]

Interestingly, the braced patients were 4.05 times more frequently discharged to home than the unbraced cohort. While the readmission and ER visit data do not

suggest any difference in complications, the difference in discharge disposition may suggest an underlying difference in the early postoperative course of single-level ACDF patients. The data also show that unbraced patients had an increased LOS as compared to the braced cohort. Despite these differences, the total cost analysis suggests that this increase in LOS did not result in any increase in direct cost to the hospital. The costs of braces themselves are not included in the cost analysis. It is worth noting that the popular cervical orthoses can range from \$25 to \$750 and restricting the use of these devices can help decrease costs to patients and insurers.^[39] Comparable, or improved, outcomes for patients while decreasing cost is a primary goal of high-value care and safely removing bracing from postoperative care may provide that value.^[40]

The prospective data collection made possible by NQII EpiLog allowed for the analysis of cervical bracing's effect on QALY gains. Bracing had no benefit on QALY gain, which provides a secondary measure of operative success that demonstrates the noninferiority of not bracing after single-level ACDF. These findings suggest that bracing may alter the discharge disposition and time to discharge without changing the total cost of care or sacrificing patient quality of life.

This study aimed to assess the efficacy of bracing in a broad and heterogeneous single-level ACDF population. The study population was constructed such that surgeon-specific practices of strictly bracing or not bracing patients following single-level ACDF removed bias of patient selection, which was confirmed in the similarity between the two cohorts. All patients received anterior plating, but graft type was not controlled for and showed significant differences between the two cohorts. Yet despite this difference, there was no effect on 30-day readmissions or ER visits between the two groups. This analysis was not powered to determine if differences in graft-type or surgical choice generated differential short-term outcomes in these patients, but again this study intended to include variability in patient presentation and surgical practice to generalize results to all elective single-level ACDF cases.

Limitations of this study are related to the retrospective nature of the cohort analysis despite the prospective data gathering tool used. There is potential bias in the data recorded in the electronic health record that cannot be corrected. To this end, we report data as means and standard deviations without removing outliers to prevent selection bias. All patients included in the study are reflective of the spectrum of complexity in ACDF cases seen at this institution. The QALY gain calculations consisted of only 71 braced patients and 2 unbraced patients from the entire study population of 577 patients. While this is a small sample size, we do not believe that it disqualifies

the results; the collection of QALY gains data began as a small pilot as a secondary measure of clinical safety and cost-effectiveness that substantiates the primary outcome measures mentioned above. The QALY gain evidence lends support to continuing this data acquisition in a future prospective trial, which would provide the best way to confirm these results.

Due to the imbalance in sample size between the two cohorts, we were unable to analyze the dataset with the strictest statistical measures. The univariate analyses reported above are representative of the relationship between bracing and patient outcomes but are not able to incorporate preoperative variables in the analysis. We aimed to expand the population to generate a propensity score-matched trial design to control for the differing demographic variables and in preparation for a future randomized control trial.

Conclusions

The use of cervical bracing following single-level ACDF remains a widespread practice despite the growing evidence base, suggesting equivocal outcomes in this setting. Here, we demonstrate that patients achieve similar outcomes with no difference in direct hospital costs and a reduction in costs to the patient by removing the cervical brace from their postoperative care. Future studies are needed to disentangle findings regarding discharge disposition and LOS differences between these populations.

Acknowledgments

The authors would like to thank the Neurological Surgery Quality Improvement (NQII) EpiLog Project.

Financial support and sponsorship

The study was financially supported by the Kevin and Bernadette McKenna Family Research Fund.

Conflicts of interest

There are no conflicts of interest.

References

1. Saifi C, Fein AW, Cazzulino A, Lehman RA, Phillips FM, An HS, et al. Trends in resource utilization and rate of cervical disc arthroplasty and anterior cervical discectomy and fusion throughout the United States from 2006 to 2013. *Spine J* 2018;18:1022-9.
2. Park Y, Maeda T, Cho W, Riew KD. Comparison of anterior cervical fusion after two-level discectomy or single-level corpectomy: Sagittal alignment, cervical lordosis, graft collapse, and adjacent-level ossification. *Spine J* 2010;10:193-9.
3. Marbacher S, Hidalgo-Staub T, Kienzler J, Wüergler-Hauri C, Landolt H, Fandino J, et al. Long-term outcome after adjacent two-level anterior cervical discectomy and fusion using stand-alone plasmaphore-covered titanium cages. *J Neurol Surg A Cent Eur Neurosurg* 2015;76:199-204.
4. Yue WM, Brodner W, Highland TR. Long-term results after anterior cervical discectomy and fusion with allograft and plating: A 5- to 11-year radiologic and clinical follow-up study. *Spine (Phila Pa 1976)* 2005;30:2138-44.
5. Wang JC, McDonough PW, Endow K, Kanim LE, Delamarter RB. The effect of cervical plating on single-level anterior cervical discectomy and fusion. *J Spinal Disord* 1999;12:467-71.
6. Samartzis D, Shen FH, Lyon C, Phillips M, Goldberg EJ, An HS, et al. Does rigid instrumentation increase the fusion rate in one-level anterior cervical discectomy and fusion? *Spine J* 2004;4:636-43.
7. McAnany SJ, Baird EO, Overley SC, Kim JS, Qureshi SA, Anderson PA, et al. A meta-analysis of the clinical and fusion results following treatment of symptomatic cervical pseudarthrosis. *Global Spine J* 2015;5:148-55.
8. Panchal RR, Kim KD, Eastlack R, Lopez J, Clavenna A, Brooks DM, et al. A clinical comparison of anterior cervical plates versus stand-alone intervertebral fusion devices for single-level anterior cervical discectomy and fusion procedures. *World Neurosurg* 2017;99:630-7.
9. Kaiser MG, Haid RW Jr., Subach BR, Barnes B, Rodts GE Jr. Anterior cervical plating enhances arthrodesis after discectomy and fusion with cortical allograft. *Neurosurgery* 2002;50:229-36.
10. Bible JE, Biswas D, Whang PG, Simpson AK, Rehtine GR, Grauer JN, et al. Postoperative bracing after Spine surgery for degenerative conditions: A questionnaire study. *Spine J* 2009;9:309-16.
11. Lee JC, Lee SH, Peters C, Riew KD. Adjacent segment pathology requiring reoperation after anterior cervical arthrodesis: The influence of smoking, sex, and number of operated levels. *Spine (Phila Pa 1976)* 2015;40:E571-7.
12. Shriver MF, Lewis DJ, Kshetry VR, Rosenbaum BP, Benzel EC, Mroz TE, et al. Pseudoarthrosis rates in anterior cervical discectomy and fusion: A meta-analysis. *Spine J* 2015;15:2016-27.
13. Connolly PJ, Grob D. Bracing of patients after fusion for degenerative problems of the lumbar spine – Yes or no? *Spine (Phila Pa 1976)* 1998;23:1426-8.
14. Russell DM, Kellerman KJ, Morrison S. Bracing the trunk and neck in young adults leads to a more aged-like gait. *Gait Posture* 2016;49:388-93.
15. Morrison S, Russell DM, Kellerman K, Walker ML. Bracing of the trunk and neck has a differential effect on head control during gait. *J Neurophysiol* 2015;114:1773-83.
16. Karlberg M, Magnusson M, Johansson R. Effects of restrained cervical mobility on voluntary eye movements and postural control. *Acta Otolaryngol* 1991;111:664-70.
17. Sandler AJ, Dvorak J, Humke T, Grob D, Daniels W. The effectiveness of various cervical orthoses. An *in vivo* comparison of the mechanical stability provided by several widely used models. *Spine (Phila Pa 1976)* 1996;21:1624-9.
18. Johnson RM, Hart DL, Simmons EF, Ramsby GR, Southwick WO. Cervical orthoses. A study comparing their effectiveness in restricting cervical motion in normal subjects. *J Bone Joint Surg Am* 1977;59:332-9.
19. Gao F. Effectiveness of adjustable cervical orthoses and modular cervical thoracic orthoses in restricting neck motion: A comparative *in vivo* biomechanical study. *Spine (Phila Pa 1976)* 2015;40:E1046-51.
20. Stambolis V, Brady S, Klos D, Wesling M, Fatianov T, Hildner C, et al. The effects of cervical bracing upon swallowing in young, normal, healthy volunteers. *Dysphagia* 2003;18:39-45.
21. Webber-Jones JE, Thomas CA, Bordeaux RE Jr. The management and prevention of rigid cervical collar complications. *Orthop*

- Nurs 2002;21:19-25.
22. Totten VY, Sugarman DB. Respiratory effects of spinal immobilization. *Prehosp Emerg Care* 1999;3:347-52.
 23. Abbott A, Halvorsen M, Dederig A. Is there a need for cervical collar usage post anterior cervical decompression and fusion using interbody cages? A randomized controlled pilot trial. *Physiother Theory Pract* 2013;29:290-300.
 24. Elliott RE, Tanweer O, Boah A, Morsi A, Ma T, Frempong-Boadu A, *et al.* Is external cervical orthotic bracing necessary after posterior atlantoaxial fusion with modern instrumentation: Meta-analysis and review of literature. *World Neurosurg* 2013;79:369-740.
 25. Overley SC, Merrill RK, Baird EO, Meaie JJ, Cho SK, Hecht AC, *et al.* Is cervical bracing necessary after one – And two-level instrumented anterior cervical discectomy and fusion? A prospective randomized study. *Global Spine J* 2018;8:40-6.
 26. Schneider AM, Hipp JA, Nguyen L, Reitman CA. Reduction in head and intervertebral motion provided by 7 contemporary cervical orthoses in 45 individuals. *Spine (Phila Pa 1976)* 2007;32:E1-6.
 27. Zhang S, Wortley M, Clowers K, Krusenklau JH. Evaluation of efficacy and 3D kinematic characteristics of cervical orthoses. *Clin Biomech (Bristol, Avon)* 2005;20:264-9.
 28. Smith GW, Robinson RA. The treatment of certain cervical-spine disorders by anterior removal of the intervertebral disc and interbody fusion. *J Bone Joint Surg Am* 1958;40-A: 607-24.
 29. Campbell MJ, Carreon LY, Traynelis V, Anderson PA. Use of cervical collar after single-level anterior cervical fusion with plate: Is it necessary? *Spine (Phila Pa 1976)* 2009;34:43-8.
 30. Camara R, Ajayi OO, Asgarzadie F. Are external cervical orthoses necessary after anterior cervical discectomy and fusion: A review of the literature. *Cureus* 2016;8:e688.
 31. Zhu MP, Tetreault LA, Sorefan-Mangou F, Garwood P, Wilson JR. Efficacy, safety, and economics of bracing after spine surgery: A systematic review of the literature. *Spine J* 2018;18:1513-25.
 32. Mourning D, Reitman CA, Heggeness MH, Esses SI, Hipp JA. Initial intervertebral stability after anterior cervical discectomy and fusion with plating. *Spine J* 2007;7:643-6.
 33. Yan C, Avadhani NG, Iqbal J. The effects of smoke carcinogens on bone. *Curr Osteoporos Rep* 2011;9:202-9.
 34. Hilibrand AS, Fye MA, Emery SE, Palumbo MA, Bohlman HH. Impact of smoking on the outcome of anterior cervical arthrodesis with interbody or strut-grafting. *J Bone Joint Surg Am* 2001;83-A: 668-73.
 35. Kusin DJ, Ahn UM, Ahn NU. The effect of smoking on spinal cord healing following surgical treatment of cervical myelopathy. *Spine (Phila Pa 1976)* 2015;40:1391-6.
 36. Tetreault LA, Côté P, Kopjar B, Arnold P, Fehlings MG; AOSpine North America and International Clinical Trial Research Network. *et al.* A clinical prediction model to assess surgical outcome in patients with cervical spondylotic myelopathy: Internal and external validations using the prospective multicenter AOSpine North American and international datasets of 743 patients. *Spine J* 2015;15:388-97.
 37. Lau D, Chou D, Ziewacz JE, Mummaneni PV. The effects of smoking on perioperative outcomes and pseudarthrosis following anterior cervical corpectomy: Clinical article. *J Neurosurg Spine* 2014;21:547-58.
 38. Yoon ST, Konopka JA, Wang JC, Youssef JA, Meisel HJ, Brodke DS, *et al.* ACDF graft selection by surgeons: Survey of AOSpine members. *Global Spine J* 2017;7:410-6.
 39. Agabegi SS, Asghar FA, Herkowitz HN. Spinal orthoses. *J Am Acad Orthop Surg* 2010;18:657-67.
 40. Porter ME. What is value in health care? *N Engl J Med* 2010;363:2477-81.