

## Oyster Calcification of Infected Bone Flap: A Rare Complication

### Abstract

An extremely rare case of chronic epidural empyema after cranioplasty is presented. It derives its extreme rareness from its association with calcification. This patient when presented to our department had a complaint of swelling with on and off discharging sinus for 2 months adjacent to old incision scar mark. The patient had a history of decompressive craniectomy and evacuation of acute subdural hematoma, in some other institution, 8 years back. Following that, the patient underwent cranioplasty with the exteriorized and preserved bone flap. In the meantime, he was asymptomatic. It is a unique interesting case of chronic epidural empyema with calcified walls after 8 years of long duration following cranioplasty.

**Keywords:** Calcification, chronic epidural empyema, cranioplasty, oyster

### Introduction

Decompressive craniectomy is known to improve clinical outcome and is widely performed in patients suffering from medically refractory elevation of intracranial pressure.<sup>[1]</sup> The patients who survive after decompressive craniectomy need to undergo cranioplasty. The complications following cranioplasty such as hematoma, infection, and bone graft resorption have been well studied and are considered as a significant cause of postoperative morbidity.<sup>[2,3]</sup> However, reports of chronic epidural empyema after cranioplasty are rare, and its association with calcification makes it rarest of rare.

### Case Report

A 44-year-old male patient was admitted to our department with a complaint of swelling with on and off discharging sinus for 2 months over the right frontal region adjacent to old incision scar mark. The patient had a history of right fronto-temporo-parietal decompressive craniectomy and evacuation of acute subdural hematoma with exteriorization of bone flap for severe traumatic brain injury due to road traffic accident in October 2007, in some other institution. Following that, the patient underwent cranioplasty with the exteriorized and preserved bone flap in December 2007,

and discharged on the 4<sup>th</sup> postoperative day with uneventful hospital stay. Since then, the patient was asymptomatic. We evaluated and investigated the patient with computed tomography scan of head which showed right fronto-temporo-parietal extraaxial lesion with calcified walls and craniotomy defect [Figure 1a and b]. Magnetic resonance imaging brain revealed T1 hypointense and T2 hyperintense extradural collection with hypointense rim in the right fronto-temporo-parietal region. No postcontrast enhancement seen. Evidence of surgical intervention involving calvarium on the right side was also seen [Figure 1c and d]. The patient underwent re-exploration of the previously operated site with the removal of infected bone flap and evacuation of chronic extradural empyema followed by complete excision of the calcified capsule. Intraoperatively, there was the presence of thick fibrous layers in subcutaneous plane over the bone flap as well as over the dura [Figure 2b and c]. There was purulent collection between the bone flap and the calcified layer over the dura [Figure 2a]. Pus culture report was sterile. Histopathology report of excised fibrous layer showed fibrocollagenous tissue with areas of calcification [Figure 3].

### Discussion

Among the survivors of decompressive craniectomy reconstructive cranial surgery

**Pawan Kumar Verma,  
Ashok Gandhi,  
Pradeep Kumar,  
S. K. Jain**

*Department of Neurosurgery,  
SMS Medical College, Jaipur,  
Rajasthan, India*

#### Address for correspondence:

*Dr. Pawan Kumar Verma,  
Department of Neurosurgery,  
SMS Medical College, Jaipur,  
Rajasthan, India.  
E-mail: dr.pawankverma@gmail.com*

#### Access this article online

**Website:** www.asianjns.org

**DOI:** 10.4103/ajns.AJNS\_237\_16

#### Quick Response Code:



**How to cite this article:** Verma PK, Gandhi A, Kumar P, Jain SK. Oyster calcification of infected bone flap: A rare complication. Asian J Neurosurg 2018;13:797-9.

This is an open access journal, and articles are distributed under the terms of the Creative Commons Attribution-NonCommercial-ShareAlike 4.0 License, which allows others to remix, tweak, and build upon the work non-commercially, as long as appropriate credit is given and the new creations are licensed under the identical terms.

**For reprints contact:** reprints@medknow.com

i.e cranioplasty is well known procedure. This can be done with the help of autologous boneflap, polymethylmethacrylate and titanium mesh. The complications of cranioplasty include bone resorption, wound infection, hematoma, sunken bone plate, epidural fluid collection, and seizure. Recent studies indicated complication rate ranging from 16.4% to 34%.<sup>[2]</sup> One of most serious complication of cranioplasty is delayed infection.<sup>[4]</sup> The incidence of delayed infection has been reported to be 4.5%.<sup>[4]</sup> It may be presented as bacterial meningitis, purulent wound discharge, osteomyelitis, multiple stitch abscesses, or epidural and subdural empyema.<sup>[5]</sup> Our case presents uniquely as a postcranioplasty complication, delayed infection in the form of oyster calcification of infected bone flap with chronic epidural empyema after 8 years of cranioplasty. With the best of our knowledge, no report is available in literature about postcranioplasty delayed infection after 8 years. The causative factors for delayed infection are previous infection due to penetrating open head injury, introduction of foreign body during the drilling of bone or newly introduced bacteria from the environment. Calcification's mechanism is not yet clear. However,

it is believed to be caused by poor circulation and absorption, cell necrosis, and hyalinization of connective tissue caused by vascular thrombosis.<sup>[6]</sup> The time interval for calcification varies from 1 month to over 3 years.<sup>[6]</sup>

Conventionally, the management of delayed infection following cranioplasty consists of operative debridement and removal of devitalized bone flaps.<sup>[7]</sup> Within the limits of possibility, preservation of bone flap has the advantage of treating infection, but we suggest that aggressive operative debridement with removal of the bone flap and antibiotic irrigation to remove all dead tissue, debris, suture, and foreign materials are desirable.

Our patient treated by re-exploration of the previously operated site with the removal of infected bone flap and evacuation of chronic extradural empyema followed by complete excision of calcified capsule [Figure 4]. Patient discharged uneventfully on the 7<sup>th</sup> postoperative day with plan of cranioplasty in near future.

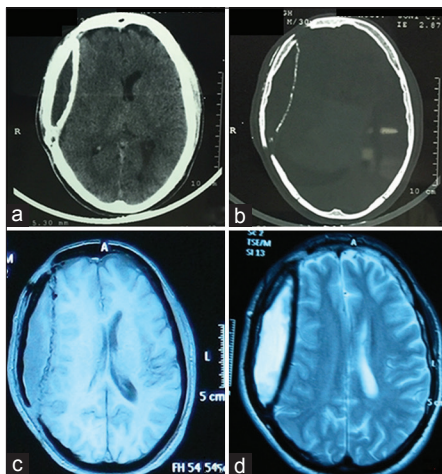


Figure 1: Computed tomography scans of head showing right fronto-temporo-parietal extraaxial lesion with calcified walls and craniotomy defect (a and b) magnetic resonance imaging brain showing T1 hypointense and T2 hyperintense extradural collection with hypointense rim in right fronto-temporo-parietal region (c and d)

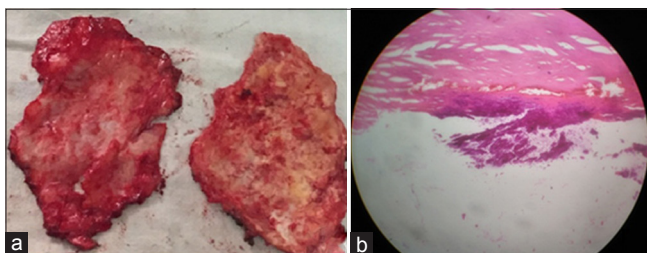


Figure 3: Excised calcified fibrous layers (a) with their histopathological image (b)

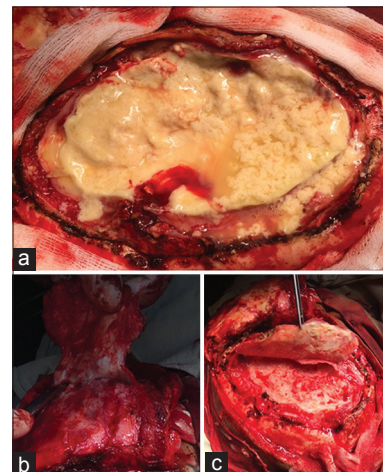


Figure 2: Intraoperative pictures showing epidural empyema simulating shape of oyster over dura (a) and calcified fibrous layers underneath subcutaneous tissue (b) and dura (c)

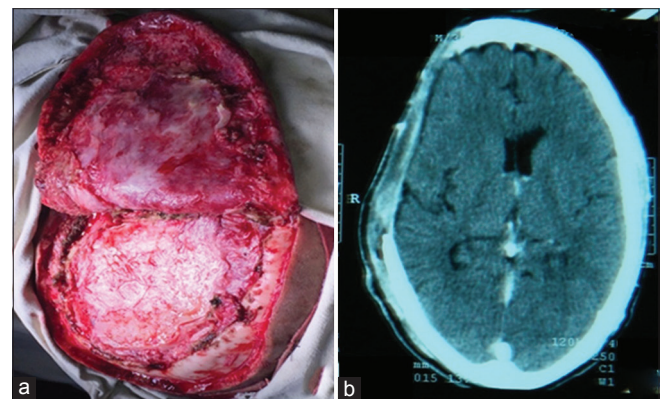


Figure 4: Intraoperative picture after removal of calcified fibrous layers (a) and postoperative computed tomography head with craniectomy defect in right fronto-temporo-parietal region (b)

### Financial support and sponsorship

Nil.

### Conflicts of interest

There are no conflicts of interest.

### References

1. Aarabi B, Hesdorffer DC, Ahn ES, Aresco C, Scalea TM, Eisenberg HM. Outcome following decompressive craniectomy for malignant swelling due to severe head injury. *J Neurosurg* 2006;104:469-79.
2. Gooch MR, Gin GE, Kenning TJ, German JW. Complications of cranioplasty following decompressive craniectomy: Analysis of 62 cases. *Neurosurg Focus* 2009;26:E9.
3. Stephens FL, Mossop CM, Bell RS, Tigno T Jr., Rosner MK, Kumar A, *et al.* Cranioplasty complications following wartime decompressive craniectomy. *Neurosurg Focus* 2010;28:E3.
4. Rish BL, Dillon JD, Meirowsky AM, Caveness WF, Mohr JP, Kistler JP, *et al.* Cranioplasty: A review of 1030 cases of penetrating head injury. *Neurosurgery* 1979;4:381-5.
5. Mollman HD, Haines SJ. Risk factors for postoperative neurosurgical wound infection. A case-control study. *J Neurosurg* 1986;64:902-6.
6. Afra D. Ossification of subdural hematoma. Report of two cases. *J Neurosurg* 1961;18:393-7.
7. Hlavin ML, Ratcheson RA. Intracranial epidural abscess. In: Kaye AH, Black PM, editors. *Operative Neurosurgery*. 2<sup>nd</sup> ed. London: Churchill Livingstone; 2000. p. 1679-85.