

Clinical Improvement of Patients with Endovascular Treatment in the Traumatic Carotid-Cavernous Fistula

Abstract

A carotid-cavernous sinus fistula (CCF) is a clinical condition when there is an abnormal communication between the internal carotid artery, external carotid artery (ECA), or any of their branches to the cavernous sinus. Traumatic CCF (TCCF) is the most common type of all CCFs. This study aims to find clinical improvement of traumatic carotid-cavernous fistulas (TCCF) after endovascular treatment. We predict the degree of clinical recovery in an attempt to make the treatment of TCCF safe and effective. This study reported a series of 28 patients with TCCFs undergoing coiling and ballooning in a period of 3 years, i.e., from December 2014 to December 2017. This is a novel case report about CCF in our country, Indonesia, especially in Surabaya. We performed clinical, angiographical, and radiological assessments before and at regular time periods after the procedure until 6 months. All patients had a partial and complete occlusion of the fistula. Angiographic occlusion of fistula, visualization of the ophthalmic artery, and disappearance of bruit predicted a good clinical outcome. All patients made a recovery at different times, depending on the degree of fistulas and treatment. Improvement in clinical symptoms had a direct correlation with the degree of occlusion. Treatment was divided into coiling and ballooning depending on patient's condition and angiographic examination. Trans femoral cerebral angiography is still very important diagnostic tool in the diagnosis and treatment of TCCFs.

Keywords: Cavernous sinus, endovascular embolization, traumatic carotid-cavernous fistulas, trans femoral cerebral angiography

Introduction

Carotid cavernous fistula (CCF) is a clinical ensemble consisting of an abnormal communication between the internal carotid artery (ICA), external carotid artery, or any of their branches to the cavernous sinus.^[1] Traumatic CCFs (TCCFs) are the most common type, reaching up to 75% of all CCFs, while spontaneous CCFs were up to 25% of all CCFs.^[2] TCCFs have been reported to occur in 0.2% of patients with craniocerebral trauma and in up to 4% of patients who sustain a basilar skull fracture.^[3] TCCFs have similar demographics associated with traumatic injuries, and TCCFs are mostly seen in young male patients.^[4]

The classic presentation of direct CCFs is the sudden development of a triad of exophthalmos, cephalic bruit, and conjunctival congestion, which is called as "Dandy Triad."^[1] The most common presenting signs and symptoms include

proptosis in 72%–98%, chemosis in 55%–100%, orbital bruits in 71%–80%, and headache in 25%–84%. In addition, most of patients complain about visual disturbances, including diplopia reported in 88% of patients, blurry vision, and orbital pain.^[5]

The treatment of CCF depends on the severity of the clinical symptoms, its angiographic properties, and the risk it presents for intracranial hemorrhage.^[6] In most instances, endovascular treatment is preferred. Endovascular embolization can be done using coils, detachable balloons, stents, or liquid embolic agents.^[7] The procedure can be done from either an arterial or venous approach. A combination of the above agents can also be used in order to achieve complete obliteration of the fistula. Surgical treatment (ICA ligation or cavernous sinus packing) is rarely used and is done only in cases where endovascular embolization has failed.^[8]

This is an open access journal, and articles are distributed under the terms of the Creative Commons Attribution-NonCommercial-ShareAlike 4.0 License, which allows others to remix, tweak, and build upon the work non-commercially, as long as appropriate credit is given and the new creations are licensed under the identical terms.

For reprints contact: WKHLRPMedknow_reprints@wolterskluwer.com

**Galih Indra Permana,
Nur Setiawan Suroto,
Asra Al Fauzi**

*Department of Neurosurgery,
Dr. Soetomo General Academic
Hospital, Airlangga University,
Surabaya, Indonesia*

Address for correspondence:
Galih Indra Permana, M.D,
Department of Neurosurgery,
Dr. Soetomo General Academic
Hospital, Airlangga University,
Surabaya, Indonesia.
E-mail: md.galih@gmail.com

Access this article online

Website: www.asianjns.org

DOI: 10.4103/ajns.AJNS_246_20

Quick Response Code:



How to cite this article: Permana GI, Suroto NS, Al Fauzi A. Clinical improvement of patients with endovascular treatment in the traumatic carotid-cavernous fistula. *Asian J Neurosurg* 2021;16:376-80.

Submitted: 22-May-2020

Revised: 04-Aug-2020

Accepted: 24-Sep-2020

Published: 28-May-2021

Case Report

This study was a retrospective study involving all cases of direct CCF with neurological manifestations, as diagnosed by the Neurosurgery Department, Dr Soetomo General Academic Hospital – Airlangga University. Patient clinical data were retrieved from the medical record in 3 years from December 2014 to December 2017. Inclusion criteria were all patients with traumatic direct CCFs of any age group and treated with interventional endovascular neurosurgery in the hospital.

This study reported clinical presentation and radiology examination before and after the treatments. Diagnosis of TCCF was performed with clinical, radiology, and trans femoral cerebral angiography (TFCA) evaluations.^[9] Radiological evaluation was done with TFCA to look after a venous drainage pattern before and after the treatments.^[10] The venous drainage pattern of the fistula was noted before patients treated. It was found that all patients had anterior drainage into either superior ophthalmic veins (SOV) or inferior ophthalmic vein, petrosal veins, superficial middle cerebral vein, and intercavernous communication.^[11]

Clinical and radiology evaluations were done in the immediate postprocedure period, at 6 weeks and 6 months. Relief of symptoms was noted individually at the immediate postprocedure period, at 6 weeks, and after 6 months. Patients were categorized into three groups based on whether they had immediate, delayed, or no obliteration of the fistula. Patients who had reduction in symptoms within 1 week after the procedure were categorized into the immediate group. Patients who had relief more than 1 week to 6 months were categorized delayed group. Meanwhile, patients who did not have any relief even after 6 months were classified as “no recovery.”

A detailed clinical examination was done to look for proptosis, chemosis, cephalic bruit, diplopia, tinnitus, N. III paresis, and N. VI paresis after the interventional endovascular procedure. All patients were divided based on the number of procedures that were taken by individuals. There were 2 endovascular procedures to treat TCCF in our hospital, i.e., Ballooning and Coiling. Every patient only got one endovascular procedure referring to the evaluation of clinical and radiology examination.

From 28 patients who have got endovascular treatment, there were 15 female patients (54%) and 13 male patients (46%) [Figure 1]. Aged distribution ranged from 14 years and 63-year-old with a mean age was 45.5-year-old. In this study, there were no spontaneous CCFs. All patients ($n = 28$) were classified as traumatic CCFs. Twenty-eight patients (100%) had proptosis. Twenty-seven patients (96%) had chemosis. Eight patients (28%) had cephalic bruit. Three patients (11%) had diplopia. Five patients (19%) had tinnitus. Two patients (7%) had N. II paresis. Two patients (7%) had N. VI paresis. One patient (3%) had a visual loss [Figure 2].

The venous drainage pattern of the fistulas was noted by TFCA. It was found that all patients had anterior

drainage (100%) into either SOV or inferior ophthalmic vein, 20 patients (71%) had drainage into the petrosal vein, and five patients (17%) had drainage into the superficial middle cerebral vein [Figure 3].

Endovascular ballooning was performed to 23 patients (82%) and coiling was performed to five patients (18%). Detailed clinical and radiological evaluations were done to all patients after the procedure. Coiling was performed with helix diameter 1.5 mm, 2 mm, and 2.5 mm, depending on the size of the fistulas. Endovascular balloon occlusion used a Gold valve balloon. In this study, the successful rate of endovascular embolization was proptosis (89%), chemosis (92%), cephalic bruit (87.5%), tinnitus (100%), diplopia (66.6%), N. III paresis (50%), N. VI paresis (50%), and visual loss (100%) with 100% ICA patency rate [Table 1 and Figure 4].

Discussion

From all the cases in our hospital, Dr. Soetomo General Academic Hospital, CCFs occurred more commonly in young adult female with a female-to-male ratio 1:0.8. The mean age of presentation in the prospective group was 45.5-year-old. In our series, all patients had a history of traumatic incident. There is no previous study discussing CCF cases in our country. This is a novel case report about CCF in our country, Indonesia, especially in Surabaya. It is interesting because most of them who came to our hospital with the obvious sign and symptom needed to perform the intervention. All of them were classified as traumatic CCFs.

The most common presenting signs and symptoms in the literature search include proptosis (100%), chemosis (96%), cephalic bruit (28%). Three of the most common clinical presentations were classic direct CCFs symptoms, “Dandy’s triad.”^[12] Most of the signs and symptoms as well as possible sequelae of CCF, are the result of shunting of blood between a high-flow and low-flow system.^[13] The venous congestion occurring within and around the cavernous sinuses causes a state of hypertension in the surrounding vascular tree. The orbits, whose venous drainage travels to the cavernous sinuses through the superior and inferior ophthalmic veins, are the first structures to manifest the symptoms of this reversed blood flow. Proptosis and chemosis happened because of this condition.^[14-16] Cavernous sinus had many important surrounding structures, i.e., N. III, N. IV, N. VI, ophthalmic nerve, and maxillary nerve. Suppression of cavernous sinus is affected in these structures. N. III and N. VI paresis are the symptoms of this compression, and then patients will suffer diplopia because of eye movement disturbance.^[17]

TFCA was one of the gold standards of this examination.^[18] TFCA can be done as a diagnostic and therapy for CCFs. The venous drainage pattern of the fistula was noted on TFCA.^[19] It was found that all patients had anterior drainage into either SOV or inferior ophthalmic vein. This condition explained about the symptoms of proptosis and chemosis in TCCFs patients.^[20] The other patients also had drainage into the petrosal vein and superficial middle cerebral vein.

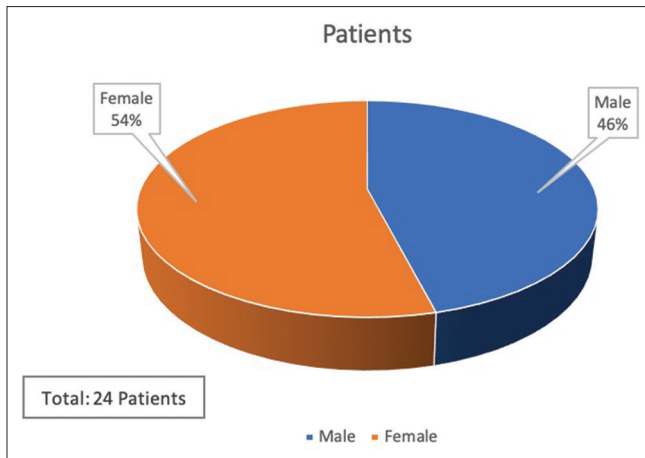


Figure 1: Distribution of gender in traumatic carotid cavernous fistulas patients of Dr. Soetomo General Hospital in July 2014-July 2017

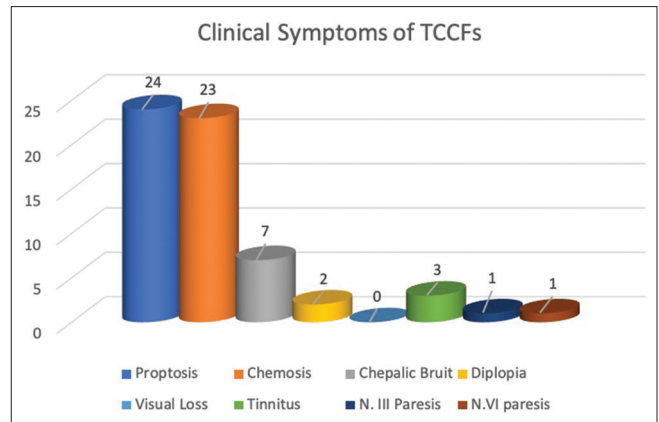


Figure 2: Graph showing the distribution of traumatic carotid cavernous fistulas clinical symptoms

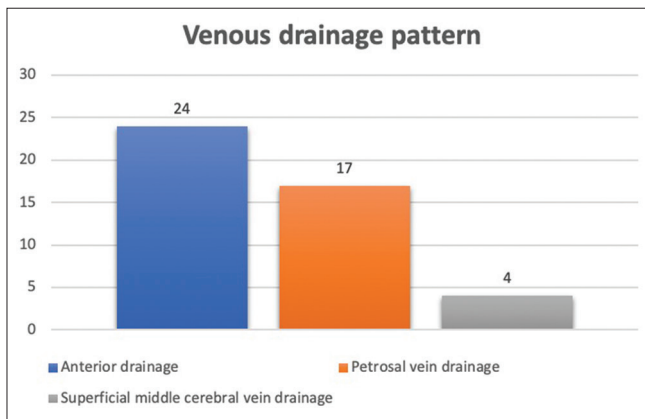


Figure 3: Graph showing the distribution of various venous drainage patterns in patients with traumatic carotid cavernous fistula

Endovascular embolization procedure has different outcomes depending on the severity of the clinical symptoms and radiological findings. Successful rate of this procedure can be described as proptosis (89%), chemosis (92%), cephalic bruit (87.5%), tinnitus (100%), and diplopia (66.6%), N. III paresis (50%), N. VI paresis (50%), and visual loss (100%). Dramatic clinical results with immediate relief of orbital symptoms and bruit are obtained if treatment is adequately performed. Proptosis and chemosis usually disappear in a few days. One can confirm the occlusion of the fistula either by the disappearance of the bruit or angiographic disappearance of the fistula during the treatment. It has been said that the fistulas can be cured in about 90% of all CCFs using the detachable balloon technique. The poor result cases are caused by span between the onset of trauma accidents and endovascular treatment. The interval of time from accident to endovascular treatment between 2 days and 3 months. Patients seek for medical treatment after having severe clinical signs and symptoms. The degree of occlusion also played an important thing after the procedure. Patients with 100% successful rate had a complete occlusion of the fistula than the other. Partial occlusion of the fistulas can be

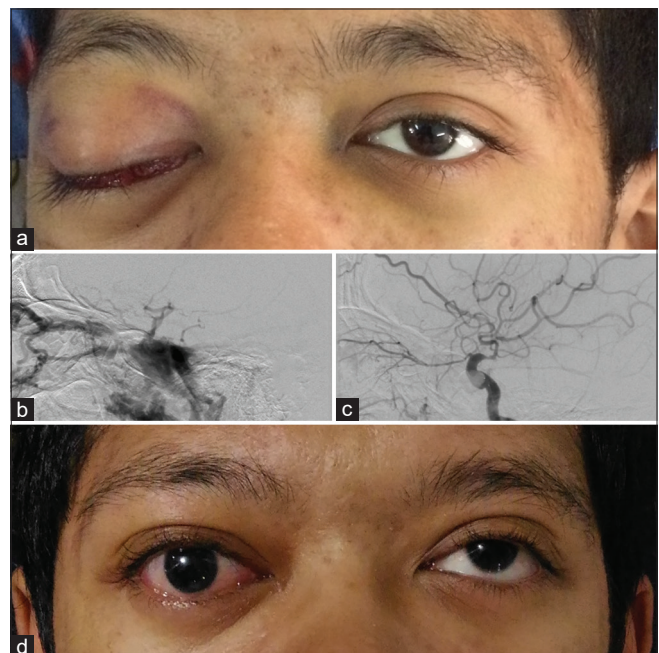


Figure 4: Illustrative case. 20-year-old male with the history of motorbike accident presented with progressive proptosis and chemosis of the right eye; (a) Preprocedural image showing proptosis and chemosis of right eye; (b) Preballooning angiography showing the dilated superior ophthalmic vein and middle cerebral veins; (c) Postballooning image showing complete obliteration of fistula, reversal of steal and demonstration of ophthalmic artery; (d) Postprocedural clinical image showing immediate resolution of proptosis and chemosis

showed by no clinical improvement of the patient's sign and symptoms.

Neurological clinical improvement happens at different times after performed endovascular treatment. In our case report, we divided it into immediate, 6 weeks, and 6 months. In this case, most of them showed clinical improvement in the immediate time after the procedure. The degree of recovery was largely dependent on the pathogenesis, severity, and duration of the preintervention deficit. There were some factors that affected these results, such as span time between the accident and endovascular treatment, severity of the

Table 1: Distribution of relief in various symptoms after interventional endovascular

Symptoms	Relief of symptoms after treatment				
	Preoperative (%)	Postoperative recovery			
		Immediate	6 weeks	6 months	Not improved
Proptosis	24 (100)	17	4	-	3
Chemosis	23 (96)	14	6	-	4
Cephalic bruit	7 (29)	5	1	-	1
Diplopia	2 (8)	-	1	-	1
Visual loss	0 (0)	-	-	-	-
Tinnitus	3 (12)	2	1	-	-
N. III paresis	1 (4)	-	-	1	-
N. VI paresis	1 (4)	-	-	-	1

symptoms, the size of the fistulas, and technical problems in performing the endovascular treatment.^[21]

The goal of CCF treatment is to completely occlude the fistula while preserving the normal flow of blood through the ICA. The main principle treatment of TCCFs is to decrease the flow of the arterial system into the cavernous sinus.^[21] Disappearance of venous congestion in the cavernous sinus relieves the symptoms of these patients^[22] especially proptosis and chemosis.

We performed TFCA in 6 vessels of angiography (bilateral internal and external carotid with bilateral vertebral arteries) to all patients ($n = 28$). Apart from the studying the anatomy of the fistula, type of fistula, and degree of closure, we also made observations regarding the ICA patency rate in our procedures. Lewis *et al.*,^[16] reported 88% cure with only 75% ICA preservation in a series of 100 direct CCFs treated with detachable balloons. In our series, endovascular ballooning was performed to 23 patients (82%), and coiling was performed to 5 patients (18%) with 100% ICA patency rate. Vascular anatomy, underlying disease, and size of the fistulas affect the difficulties of the endovascular procedures, embolization, coiling, and ballooning.^[23] The advantage of balloon occlusion of a CCF is the ability to occlude the fistula rapidly with the preservation of the ICA. However, technical difficulties can be encountered. The size of the cavernous sinus and the fistula may affect the success rate of detachable-balloon embolization of a CCF. The cavernous sinus must be large enough to accommodate the detachable balloon/balloons for embolization. The size of the fistula must be smaller than the inflated balloon, but large enough to allow access for a deflated or partly inflated balloon.^[24]

However, the size of the fistula should not be too large, because the embolization balloon may retract to the ICA on inflation in the cavernous sinus. It is also to provide easier navigation of the balloon into the cavernous sinus and prevent protrusion of the inflated balloon through the fistula site to narrow the adjacent ICA lumen. Inadequate embolization may be seen due to early balloon detachment, deflation, or rupture by contact with a bony fragment. As a rare complication, the balloon can migrate to the venous side of the treated fistula resulting in ophthalmoplegic signs due to mechanical compression of cranial nerves close to the cavernous sinus.^[24]

The advantages of coil occlusion of CCFs, when compared with balloon embolization, include ease of access and availability of a variety of sizes of the embolic device. Potential disadvantages include slower gradual occlusion of the fistula, which increases procedure time, and the risk of incomplete fistula occlusion with the loss of transarterial access; a loss which would then require a second transvenous approach. Complications of transarterial coil embolization include thromboembolic, ICA compromise by protruding coil mass, and ICA dissection.^[25] To prevent the retrograde herniation of the embolic material into the parent artery and distal intracranial circulation, the assistance of a nondetachable balloon (balloon-assist technique) or a porous stent may be preferred, especially in the setting of a large tear in the ICA. Stents also allow initial reconstruction of the damaged segment of the ICA and increase the ability to successfully treat fistulas without parent artery sacrifice.^[26]

Treatment of CCF is directed to relieve the symptoms of and to eliminate the fistula.^[27] The most satisfactory and well-established treatment modality is the placement of a detachable balloon across the fistula. The balloon is then inflated within the cavernous sinus so that it can create a tamponade of the fistula, eliminating flow across the fistula and permitting healing of the orifice of the fistula. In some cases, with a small fistulous opening, low-flow fistula, or difficult direction of the fistula, it may be technically impossible to pass a detachable balloon through the fistula. The fistulas can be directly selected with wire-guided microcatheters, and the fistulas can be occluded with various micro-coils.

Clinical and radiological evaluation was performed in 6 weeks and 6 months. A side effects that can happen, especially in the endovascular ballooning procedure that deflates the balloon and in coiling some of them, is a failure in covering fistulas. In our 6-month evaluation, we did not find any of this side effect that happened in our study with no recurrent of CCF after endovascular intervention reported. Recurrence of CCFs due to recanalization post ballooning or coiling can be treated by repeating the procedure.^[28]

Conclusion

Improvement in clinical symptoms had a direct correlation with the degree of occlusion. Treatment was divided into coiling and

ballooning depending on patient's condition and angiographic examination. TFCA is still a very important diagnostic tool in the diagnosis and treatment of TCCFs. The endovascular approach should be tailored to individual cases according to the type, exact anatomy, and extent of each fistula. With increasing knowledge about novitious endovascular techniques, such as placement of covered stent-grafts, higher success rates can be achieved with the preservation of the ICA.

Declaration of patient consent

The authors certify that they have obtained all appropriate patient consent forms. In the form, the legal guardian has given his consent for images and other clinical information to be reported in the journal. The guardian understands that names and initials will not be published and due efforts will be made to conceal identity, but anonymity cannot be guaranteed.

Acknowledgments

This work is supported by the Endovascular Division, Department of Neurosurgery, Dr. Soetomo General Academic Hospital, Surabaya, Indonesia.

Financial support and sponsorship

Nil.

Conflicts of interest

There are no conflicts of interest.

References

- Joshi DK, Singh DD, Garg DD, Singh DH, Tandon DM. Assessment of clinical improvement in patients undergoing endovascular coiling in traumatic carotid cavernous fistulas. *Clin Neurol Neurosurg* 2016;149:46-54.
- Tan AC, Farooqui S, Li X, Tan YL, Cullen J, Lim W, *et al.* Ocular manifestations and the clinical course of carotid cavernous sinus fistulas in Asian patients. *Orbit* 2014;33:45-51.
- Ellis JA, Goldstein H, Connolly ES Jr., Meyers PM. Carotid-cavernous fistulas. *Neurosurg Focus* 2012;32:E9.
- van Rooij WJ, Sluzewski M, Beute GN. Ruptured cavernous sinus aneurysms causing carotid cavernous fistula: Incidence, clinical presentation, treatment, and outcome. *AJNR Am J Neuroradiol* 2006;27:185-9.
- Gonzalez LF, Chalouhi N, Tjounmakaris S, Jabbour P, Dumont AS, Rosenwasser RH. Treatment of carotid-cavernous fistulas using intraarterial balloon assistance: Case series and technical note. *Neurosurg Focus* 2012;32:E14.
- Fattahi TT, Brandt MT, Jenkins WS, Steinberg B. Traumatic carotid-cavernous fistula: Pathophysiology and treatment. *J Craniofac Surg* 2003;14:240-6.
- Tytle TL, Pudukollu PK. Carotid cavernous fistula. *Semi Cerebrovasc Dis Stroke* 2001;1:83-111.
- Helmke K, Krüger O, Laas R. The direct carotid cavernous fistula: A clinical, pathoanatomical, and physical study. *Acta Neurochir (Wien)* 1994;127:1-5.
- Barrow DL, Spector RH, Braun IF, Landman JA, Tindall SC, Tindall GT. Classification and treatment of spontaneous carotid-cavernous sinus fistulas. *J Neurosurg* 1985;62:248-56.
- Serbinenko FA. Balloon catheterization and occlusion of major cerebral vessels. *J Neurosurg* 1974;41:125-145.
- Miller NR. Dural carotid-cavernous fistulas: Epidemiology, clinical presentation, and management. *Neurosurg Clin N Am* 2012;23:179-92.
- de Keizer R. Carotid-cavernous and orbital arteriovenous fistulas: Ocular features, diagnostic and hemodynamic considerations in relation to visual impairment and morbidity. *Orbit* 2003;22:121-42.
- Meyers PM, Halbach VV, Dowd CF, Lempert TE, Malek AM, Phatouros CC, *et al.* Dural carotid cavernous fistula: Definitive endovascular management and long-term follow-up. *Am J Ophthalmol* 2002;134:85-92.
- Travers B. A case of aneurism by anastomosis in the orbit, cured by the ligation of the common carotid artery. *Med Chir Trans* 1811;2:1-420.1.
- Kirsch M, Henkes H, Liebig T, Weber W, Esser J, Golik S, Kuhne D. Endovascular management of dural carotid cavernous sinus fistula in 141 patients. *Neuroradiology* 2006;48:486-90.
- Lewis A, Tomsick TA, Tew JM. Management of 100 consecutive direct carotid cavernous fistula: Result of treatment with detachable balloons. *Neurosurgery* 1995;36:239-45.
- Luo CB, Teng MM, Yen DH, Chang F, Lirng JF, Chang CY. Endovascular embolization of recurrent traumatic carotid cavernous fistulas managed previously with detachable balloons. *J Trauma* 2004;56:1214-20.
- Wang W, Li YD, Li MH, Tan HQ, Gu BX, Wang J, *et al.* Endovascular treatment of post-traumatic direct carotid-cavernous fistulas: A single-center experience. *J Clin Neurosci* 2011;18:24-8.
- Gupta AK, Purkayastha S, Krishnamoorthy T, Bodhey NK, Kapilamoorthy TR, Kesavadas C, *et al.* Endovascular treatment of direct carotid cavernous fistulae: A pictorial review. *Neuroradiology* 2006;48:831-9.
- Morón FE, Klucznik PR, Mawad ME, Strother CM. Endovascular treatment of high-flow carotid cavernous fistulas by stent-assisted coil placement. *Am J Neuroradiol* 2005;26:399-1404.
- Higashida RT, Halbach VV, Tsai FY, Norman D, Pribram HF, Mehlinger CM, *et al.* Interventional neurovascular treatment of traumatic carotid and vertebral artery lesions: Results in 234 cases. *AJR Am J Roentgenol* 1989;153:577-82.
- Joshi KC, Singh D, Tandon MS. Intrafistula pressure measurement in traumatic carotid cavernous fistulas – key to increasing safety and effectiveness of endovascular coiling. *Acta Neurochir* 2014;156:1695-700.
- Pierot L, Moret J, Boulin A, Castaings L. Endovascular treatment of post-traumatic complex carotid-cavernous fistulas, using the arterial approach. *J Neuroradiol* 1992;19:79-87.
- Teng MM, Chang CY, Chiang JH, Lirng JF, Luo CB, Chen SS, *et al.* Double-balloon technique for embolization of carotid cavernous fistulas. *AJNR Am J Neuroradiol* 2000;21:1753-6.
- Ringer AJ, Salud L, Tomsick TA. Carotid cavernous fistulas: Anatomy, classification, and treatment. *Neurosurg Clin N Am* 2005;16:279-95, viii.
- Morón FE, Klucznik RP, Mawad ME, Strother CM. Endovascular treatment of high-flow carotid cavernous fistulas by stent-assisted coil placement. *AJNR Am J Neuroradiol* 2005;26:1399-404.
- Zanaty M, Chalouhi N, Tjounmakaris SI, Hasan D, Rosenwasser RH, Jabbour P. Endovascular treatment of carotid-cavernous fistulas. *Neurosurg Clin N Am* 2014;25:551-63. [Doi: 10.1016/j.nec.2014.04.011].
- Korkmazer B, Kocak B, Tureci E, Islak C, Kocer N, Kizilkilic O. Endovascular treatment of carotid cavernous sinus fistula: A systematic review. *World J Radiol* 2013;5:143-55.