

## Cavernous Malformation of a Thoracic Spinal Nerve Root: Case Report and Review of Literature

### Abstract

Intradural extramedullary spinal cavernous malformations (CMs) remain the least common variant of these lesions and can originate from the inner surface of the dura mater, the pial surface of the spinal cord, and the blood vessels in the spinal nerves. Root-based-only extramedullary CMs are very rare in the thoracic region with only four cases reported. We present a case of 56-year-old male with 1-year progression of lower extremities weakness. Magnetic resonance imaging demonstrated a hyperintense lesion in the upper thoracic region. Surgical exploration revealed a CM with origin in the second thoracic nerve root with gross total resection. Histopathological examination confirmed a CM. The patient had complete recovery of neurological function at 3 months interval. Intradural extramedullary CM is extremely rare entity that must be considered in the differential diagnosis of intradural extramedullary lesions. Surgical resection is the treatment of choice to prevent further neurological damage.

**Keywords:** Cavernous malformation, extramedullary, intradural, vascular

### Introduction

Cavernous malformations (CMs) are common benign vascular lesions composed of endothelium-lined vascular channels without intervening normal parenchyma, neural, or glial elements.<sup>[1,2]</sup> These lesions belong to a group of vascular malformations that are developmental anomalies of the vascular bed.<sup>[3]</sup> Spinal CMs account for 5%–12% of spinal vascular malformations with only 3% located intradurally.<sup>[4,5]</sup> Intradural extramedullary spinal CMs remain the least common variant of these lesions. Specifically, thoracic root-based-only extramedullary CMs are very rare with only four cases reported. We describe the case of a patient with a CM arising from a thoracic nerve root in which surgery was performed.

### Case Report

A 56-year-old man with a history of diabetes mellitus type II presented with 1 year progression of lower extremity numbness and weakness that was initially attributed to diabetic peripheral neuropathy. However, progression of symptoms was rapid, with patient being nonambulatory within 6 months. The deterioration prompted a full spine magnetic resonance imaging (MRI), which revealed an enhancing mass with

suspected extramedullary location [Figure 1]. Neurological examination demonstrated bilateral grade 3 force in all muscle groups in the lower extremities, lower extremity hyperreflexia, bilateral ankle clonus, altered proprioception, temperature, and paresthesias from the second thoracic dermatome and bilateral-positive Babinski reflexes. Surgical intervention was recommended to the patient.

At the operating theater, baseline somatosensory evoked potentials (SSEPs), transcranial motor evoked potentials (TcMEPs), and electromyography were obtained and revealed decreased values in lower extremities. The patient underwent a T1–T3 laminoplasty, durotomy, and microsurgical *en bloc* resection of the lesion. On dural opening, a large extramedullary lesion was evident with a mulberry-like appearance displacing the spinal cord toward the left and causing severe compression [Figure 2]; it was noted that the lesion was very adherent to the second thoracic spinal root with a distinguishable border between the lesion and the spinal cord [Figure 2]. The lesion was carefully dissected and removed *en bloc*, along with part of the nerve root from which it was originating [Figure 2]. After the lesion was removed, TcMEPs and SSEPs demonstrated significant intraoperative improvement. Postoperative MRI demonstrated successful gross total resection with spinal cord decompression [Figure 3]. Microscopic

**Juan C. Vicenty,  
Ricardo J.  
Fernandez-de  
Thomas,  
Samuel Estronza,  
Miguel A.  
Mayol-Del Valle,  
Emil A. Pastrana**

*Department of Surgery,  
Neurosurgery Section,  
University of Puerto Rico,  
Medical Science Campus,  
San Juan, Puerto Rico*

### Address for correspondence:

*Dr. Emil A. Pastrana,  
Department of Surgery,  
Neurosurgery Section,  
University of Puerto Rico,  
Medical Science Campus,  
P.O. Box 365067, San Juan,  
00936 Puerto Rico.  
E-mail: emil.pastrana@upr.edu*

### Access this article online

Website: [www.asianjns.org](http://www.asianjns.org)

DOI: 10.4103/ajns.AJNS\_249\_18

### Quick Response Code:



**How to cite this article:** Vicenty JC, Fernandez-de Thomas RJ, Estronza S, Mayol-Del Valle MA, Pastrana EA. Cavernous malformation of a thoracic spinal nerve root: Case report and review of literature. *Asian J Neurosurg* 2019;14:1033-6.

This is an open access journal, and articles are distributed under the terms of the Creative Commons Attribution-NonCommercial-ShareAlike 4.0 License, which allows others to remix, tweak, and build upon the work non-commercially, as long as appropriate credit is given and the new creations are licensed under the identical terms.

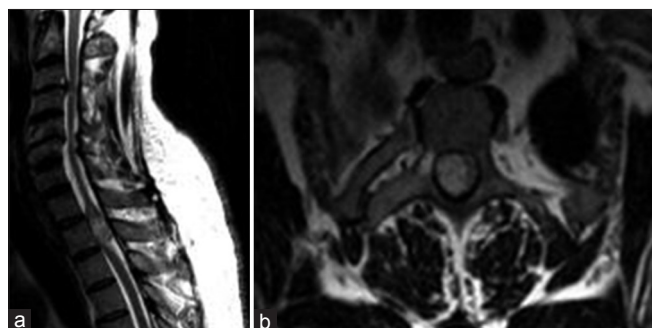For reprints contact: [reprints@medknow.com](mailto:reprints@medknow.com)

examination revealed an encapsulated tissue with a lumen filled with hemorrhage, large thin-walled dilated vessels lined by flattened endothelium with no elastic lamina, consistent with a CM [Figure 4]. Postoperative course was uneventful with near-complete recovery of motor and sensory deficits. Follow-up evaluation at 3 months demonstrated complete recovery of preoperative deficits.

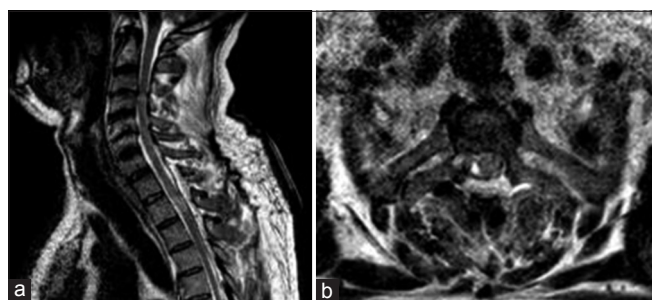**Review of Literature**

Table 1 illustrates the ten cases that have been reported in the literature of intradural extramedullary CMs in the thoracic spine. The presenting age of the patients are

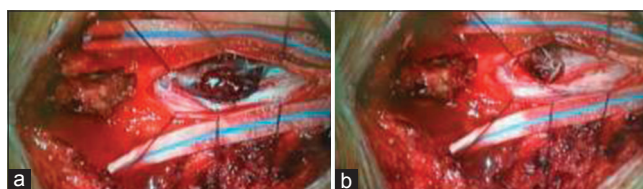
between 22 and 67 years, with a mean of 47 years. The majority of patients were male, representing a 70% of cases. In the same manner, the majority of cases (70%) were located in the mid-thoracic and lower-thoracic region. The presenting symptoms consisted of subarachnoid hemorrhage in three patients, sensorimotor disturbances in six patients, and one patient presenting with isolated back pain. Urinary disturbances consisting of sphincter dysfunction and urinary retention were also present in two patients in addition to sensorimotor disturbances. Gross total resection was achieved in nine patients, with only one case of subtotal resection due to significant adherence to the spinal cord. Excellent outcomes were obtained in six patients, no improvement was seen in two patients, and



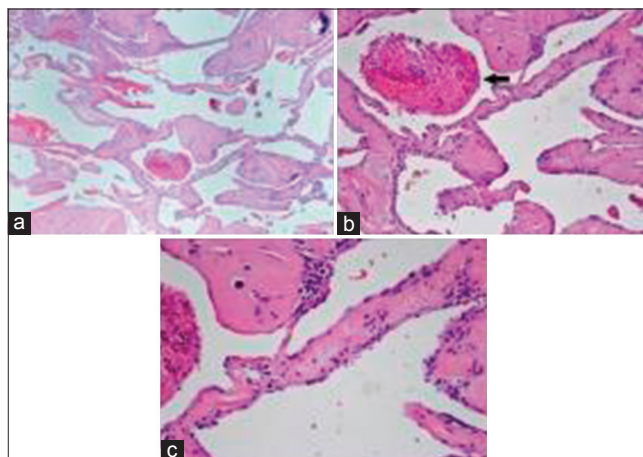
**Figure 1: Preoperative magnetic resonance imaging.** T2 Hyperintense Well-circumscribed mass within the spinal canal centered at the T2 level. The mass is intradural and compressing/displacing the cord laterally. Although it shows distinct hyperintense signal, a definitive determination of intra versus extramedullary could not be made due to close apposition. The mass shows internal T2 hypointense foci and rim representing hemosiderin depositions; a finding suggestive of cavernous malformation. (a) Sagittal view, (b) axial view



**Figure 3: Postoperative magnetic resonance imaging.** Gross total resection of previously identified hyperintense mass. (a) Sagittal view, (b) axial view



**Figure 2: (a) Cavernous malformation with attachment in the thoracic nerve root. (b) Disconnection from nerve root**



**Figure 4: Hematoxylin-eosin stain cavernous malformation. (a) Large dilated vessels lined by flattened endothelium. (b) Organizing thrombus. (c) Flattened endothelium lining vessel walls**

**Table 1: Cases of thoracic intra-dural extra-medullary cavernous malformations**

Author and Year	Age/ Sex	Sex	Location	Presenting Symptoms	Origin	Surgery extent	Outcome
Roger <i>et al.</i> <sup>[8]</sup> 1951	22,	F	T11	Sciatica/back pain/Motor deficit	ND	Total	Whorse
Worse Floris, <sup>[9]</sup> 1958	57	M	T12	Motor deficit	ND	Total	ND
Heimberger <i>et al.</i> <sup>[10]</sup> 1982	24,	M	T2-3	SAH	Root	Total	Excellent
Pagni <i>et al.</i> <sup>[11]</sup> 1990	46,	M	T12	Back Pain	Root	Total	Excellent
Mastronardi <i>et al.</i> <sup>[12]</sup> 1991	49,	F	T4	Sensorimotor deficit	Root	Total	Excellent
Mori <i>et al.</i> <sup>[13]</sup> 1991	65	M	T1	SAH	Cord	Total	Excellent
Sharma <i>et al.</i> <sup>[14]</sup> 1992	63,	M	T12	Back pain/Sensorimotor deficit/Urinary rentention	Root/Cord	Total	No improvement
Sharma <i>et al.</i> <sup>[14]</sup> 1992	43,	M	T5	SAH	Root/Cord	Total	Excellent
Rao <i>et al.</i> <sup>[15]</sup> 1997	35,	F	T12	Sensorimotor deficit	Cord	Subtotal	No improvement
Er <i>et al.</i> <sup>[2]</sup> 2006	67,	M	T11	Back pain Sensorimotor deficit Sphincter dysfunction	Root	Total	Excellent

worsening of neurological deficits was observed in one patient; one case had no report of postoperative outcome.

## Discussion

CMs are benign vascular lesions of the neural axis: an intradural extramedullary location is the rarest.<sup>[6-9]</sup> MRI is the study of choice for these lesions.<sup>[10,11]</sup> Intradural extramedullary CMs can be homogeneously or heterogeneous hyperintense in T1-weighted images. They can be hyperintense in T2-weighted images, and gadolinium enhancement is frequent but not necessary.<sup>[12]</sup> MRI findings of hemorrhage are variable, depending on severity and stage.<sup>[13]</sup> Microscopic examination consists of irregular sinusoidal vascular spaces lacking intervening neural or glial tissue lined by a single layer of endothelium.<sup>[14-16]</sup> Recurrent hemorrhages in CMs lead to enlargement and further compression of adjacent structures; it also causes thrombosis of vascular channels that can necrotize and perpetuate further hemorrhages.<sup>[16,17]</sup> Patients with intradural extramedullary CMs develop symptoms secondary to a space-occupying lesion, either due to hemorrhage, cord edema, or cord impingement.<sup>[13,18-20]</sup> Surgical removal remains the standard of care in the treatment of these lesions in symptomatic patients and should be done in an expedited manner to prevent further neurological deterioration as conservative management offers no chance for improvement in symptoms.<sup>[20-23]</sup> There is no role for endovascular treatment of CMs as these vascular lesions are not amenable to embolization due to their cytoarchitecture.<sup>[23]</sup> CMs in the spinal cord are usually well-demarcated lesions with well-defined planes, permitting a safe resection with excellent outcomes.<sup>[16]</sup> Intraoperatively, intradural extramedullary CMs tend to be intrinsically adherent to the nerve roots and/or spinal cord, which favors an origin in the blood vessels on the surface of nerve roots and spinal cord.<sup>[16]</sup> Surgical procedures may be technically difficult, due to the formation of dense adhesions between the CM and the nerve roots/spinal cord.<sup>[16]</sup> In some cases, dissection of the involved nerve root becomes challenging, and a decision must be taken if sacrificing the involved root is acceptable.<sup>[16]</sup> In our case, the gradual worsening of symptoms correlates with suspected microhemorrhage causing increase in size and subsequent cord compression. Preoperative MRI in our patient was not pathognomonic of a CM; thus, our differential diagnosis included ependymoma, schwannoma, and neurofibroma. Surgical exploration in our patient revealed a densely adherent CM to the second thoracic nerve root; it was decided to sacrifice the root to prevent further manipulation that could result in a spinal cord injury. In our patient, full neurological recovery was seen at 3 months.

## Conclusion

Although extremely rare, intradural extramedullary CMs must be considered in the differential diagnosis of

intradural extramedullary lesions. Neurological recovery is dependent on the severity of preoperative symptoms. The optimal treatment remains surgical *en bloc* resection to prevent further neurological damage.

## Declaration of patient consent

The authors certify that they have obtained all appropriate patient consent forms. In the form the patient(s) has/have given his/her/their consent for his/her/their images and other clinical information to be reported in the journal. The patients understand that their names and initials will not be published and due efforts will be made to conceal their identity, but anonymity cannot be guaranteed.

## Financial support and sponsorship

Nil.

## Conflicts of interest

There are no conflicts of interest.

## References

1. Lanotte M, Massaro F, Faccani G, Forni M, Valentini MC. Dumbbell-shaped spinal epidural cavernous angioma. Case report. *Ital J Neurol Sci* 1994;15:429-32.
2. Er U, Yigitkanli K, Simsek S, Adabag A, Bavbek M. Spinal intradural extramedullary cavernous angioma: Case report and review of the literature. *Spinal Cord* 2007;45:632-6.
3. Fahlbusch R, Strauss C, Huk W, Röckelein G, Kömpf D, Ruprecht KW, *et al.* Surgical removal of pontomesencephalic cavernous hemangiomas. *Neurosurgery* 1990;26:449-56.
4. Padovani R, Acciarri N, Giulioni M, Pantieri R, Foschini MP. Cavernous angiomas of the spinal district: Surgical treatment of 11 patients. *Eur Spine J* 1997;6:298-303.
5. Mastronardi L, Ferrante L, Scarpinati M, Gagliardi FM, Celli P, Fortuna A, *et al.* Intradural extramedullary cavernous angioma: Case report. *Neurosurgery* 1991;29:924-6.
6. Abul-Kasim K, Thurnher MM, McKeever P, Sundgren PC. Intradural spinal tumors: Current classification and MRI features. *Neuroradiology* 2008;50:301-14.
7. Caroli E, Acqui M, Trasimeni G, Di Stefano D, Ferrante L. A case of intraroot cauda equina cavernous angioma: Clinical considerations. *Spinal Cord* 2007;45:318-21.
8. Roger H, Paillas JE, Bonnal J, Vigorous M. Angiomes de la moelle et des racines. *Acta Neurol Psych Belgium* 1951;7:491-5.
9. Floris V. Angiome angiomatosi del sistema nervoso. *Lav Neuropsich* 1958;27:159-79.
10. Heimberger K, Schnaberth G, Koos W, Pendl G, Auff E. Spinal cavernous haemangioma (intradural-extramedullary) underlying repeated subarachnoid haemorrhage. *J Neurol* 1982;226:289-93.
11. Pagni CA, Canavero S, Forni M. Report of a cavernoma of the cauda equina and review of the literature. *Surg Neurol* 1990;33:124-31.
12. Mastronardi L, Ferrante L, Scarpinati M, Gagliardi FM, Celli P, Fortuna A. Intradural extramedullary cavernous angioma: Case report. *Neurosurgery* 1991;29:924-6.
13. Mori K, Ishii H, Tomita Y, Nakajima K, Morimoto K, Maeda M. Intradural-extramedullary spinal cavernous angioma – Case report. *Neurol Med Chir (Tokyo)* 1991;31:593-6.
14. Sharma R, Rout D, Radhakrishnan VV. Intradural spinal

- cavernomas. *Br J Neurosurg* 1992;6:351-6.
15. Rao GP, Bhaskar G, Hemaratnan A, Srinivas TV. Spinal intradural extramedullary cavernous angiomas: Report of four cases and review of the literature. *Br J Neurosurg* 1997;11:228-32.
  16. Rachinger J, Buslei R, Engelhorn T, Doerfler A, Strauss C. Intradural-extramedullary cavernous hemangioma of the left motor root C7 – Case report and update of the literature. *Zentralbl Neurochir* 2006;67:144-8.
  17. Cansever T, Civelek E, Sencer A, Karasu A, Kiriş T, Hepgül K, *et al.* Spinal cavernous malformations: A report of 5 cases. *Surg Neurol* 2008;69:602-7.
  18. Bruni P, Massari A, Greco R, Hernandez R, Oddi G, Chiappetta F, *et al.* Subarachnoid hemorrhage from cavernous angioma of the cauda equina: Case report. *Surg Neurol* 1994;41:226-9.
  19. Mataliotakis G, Perera S, Nagaraju S, Marchionni M, Tzerakis N. Intradural extramedullary cavernoma of a lumbar nerve root mimicking neurofibroma. A report of a rare case and the differential diagnosis. *Spine J* 2014;14:e1-7.
  20. Nie QB, Chen Z, Jian FZ, Wu H, Ling F. Cavernous angioma of the cauda equina: A case report and systematic review of the literature. *J Int Med Res* 2012;40:2001-8.
  21. Duke BJ, Levy AS, Lillehei KO. Cavernous angiomas of the cauda equina: Case report and review of the literature. *Surg Neurol* 1998;50:442-5.
  22. Acciarri N, Padovani R, Pozzati E, Gaist G, Manetto V. Spinal cavernous angioma: A rare cause of subarachnoid hemorrhage. *Surg Neurol* 1992;37:453-6.
  23. Spetzler RF, Detwiler PW, Riina HA, Porter RW. Modified classification of spinal cord vascular lesions. *J Neurosurg* 2002;96:145-56.