

Case Report

Intraoperative Transcranial Embolization following Decompressive Craniectomy for a Dural Arteriovenous Fistula Presenting with Acutely Raised Intracranial Pressure

Abstract

We report the clinical details, imaging findings, and management of a 58-year-old female who presented with rapidly deteriorating neurological function and acute raise in intracranial pressure secondary to posterior fossa dural arteriovenous fistula (DAVF). In this report, we present the emergency management of the DAVF with single-stage combined surgical decompressive craniotomy and direct transcranial embolization.

Keywords: Dural arteriovenous fistula, surgical approach, transcranial embolization

Introduction

Dural arteriovenous fistula (DAVF) is an acquired vascular malformation of dural venous sinuses. DAVFs are associated with features of cerebral venous congestion, raised intracranial pressure (ICP), and increased risk of intracerebral hemorrhage.^[1] Acute raise in ICP secondary to DAVF has been rarely described in the literature.^[2] Treatment of DAVF by direct transcranial embolization of the fistula through craniotomy has been described uncommonly in the literature.^[3-8] We describe the clinical features and management of a patient who presented with acute raise in ICP secondary to transverse sinus DAVF.

Case Report

A 58-year-old female presented with sudden onset of giddiness and multiple episodes of vomiting. On presentation, she was conscious, obeying commands, and had a Glasgow Coma Scale (GCS) of 15. Computed tomography (CT) of the brain revealed hemorrhages in the left posterior temporal lobe and left cerebellar hemisphere with mildly dilated bilateral lateral ventricles. In view of atypical pattern of hemorrhage, a CT cerebral angiography was performed, which showed multiple subarachnoid curvilinear vascular channels over the bilateral cerebellar hemispheres

and left temporal lobe [Figure 1]. A digital subtraction angiography (DSA) was done, which revealed a DAVF in relation to isolated left transverse sinus with extensive cortical venous reflux suggesting Cognard Type IIa + b fistula. It was showing meningeal arterial feeders from temporal squamous branch of the left middle meningeal artery, left posterior auricular artery and left occipital artery, and cortical venous reflux. The DSA venographic phase image showed that the left transverse sinus was isolated from the venous circulation, and it was not used by the brain for normal drainage [Figure 2]. The imaging features suggested extensive venous congestion in the posterior fossa due to arterialized flow in the cortical veins secondary to DAVF. The patient was planned for definitive treatment of the DAVF by endovascular embolization through transarterial (femoral) approach. However, on day 2 of admission, her neurological condition deteriorated and her GCS became 8. After the protection of the airway, a repeat CT scan of the brain was performed, which showed interval increase in hydrocephalus and effacement of perimesencephalic and prepontine cisterns suggesting raised ICP [Figure 3]. After informed consent, the patient was taken up for emergency occipital decompressive

**Suresh Giragani,
Ashok Reddy
Kasireddy,
Anandh
Balasubramaniam¹,
Vikas Agrawal²,
Swathi Muthyala**

*Departments of Neuroradiology
and Interventional Radiology,
¹Neurosurgery and ²Neurology,
Yashoda Hospitals,
Secunderabad, Telangana, India*

Address for correspondence:

*Dr. Suresh Giragani,
Department of Neuroradiology
and Interventional Radiology,
Yashoda Hospitals, Alexander
Road, Secunderabad,
Telangana, India.
E-mail: suresh8g@yahoo.com*

This is an open access journal, and articles are distributed under the terms of the Creative Commons Attribution-NonCommercial-ShareAlike 4.0 License, which allows others to remix, tweak, and build upon the work non-commercially, as long as appropriate credit is given and the new creations are licensed under the identical terms.

For reprints contact: WKHLRPMedknow_reprints@wolterskluwer.com

How to cite this article: Giragani S, Kasireddy AR, Balasubramaniam A, Agrawal V, Muthyala S. Intraoperative transcranial embolization following decompressive craniectomy for a dural arteriovenous fistula presenting with acutely raised intracranial pressure. Asian J Neurosurg 2020;15:1006-10.

Submitted: 23-May-2020 **Revised:** 24-Jun-2020

Accepted: 18-Aug-2020 **Published:** 21-Dec-2020

Access this article online

Website: www.asianjns.org

DOI: 10.4103/ajns.AJNS_250_20

Quick Response Code:



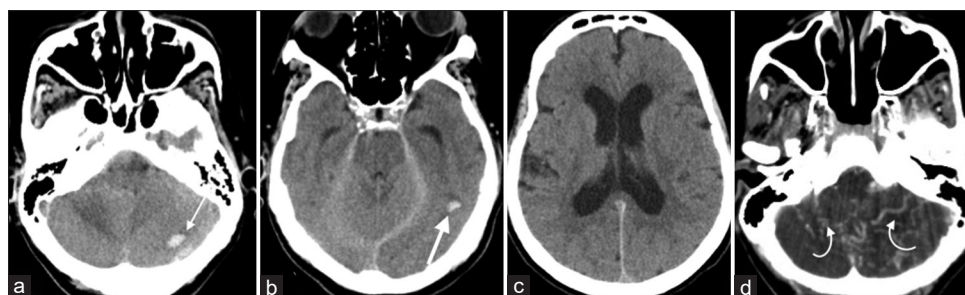


Figure 1: (a-c) Axial sections of computed tomography of the brain at the time of presentation demonstrating hemorrhage in the left temporal lobe (thick arrow) and cerebellum (thin arrow). (d) Axial maximum intensity projection image of computed tomography angiogram demonstrating multiple curvilinear tortuous channels (thin curved arrows) in the cerebellum

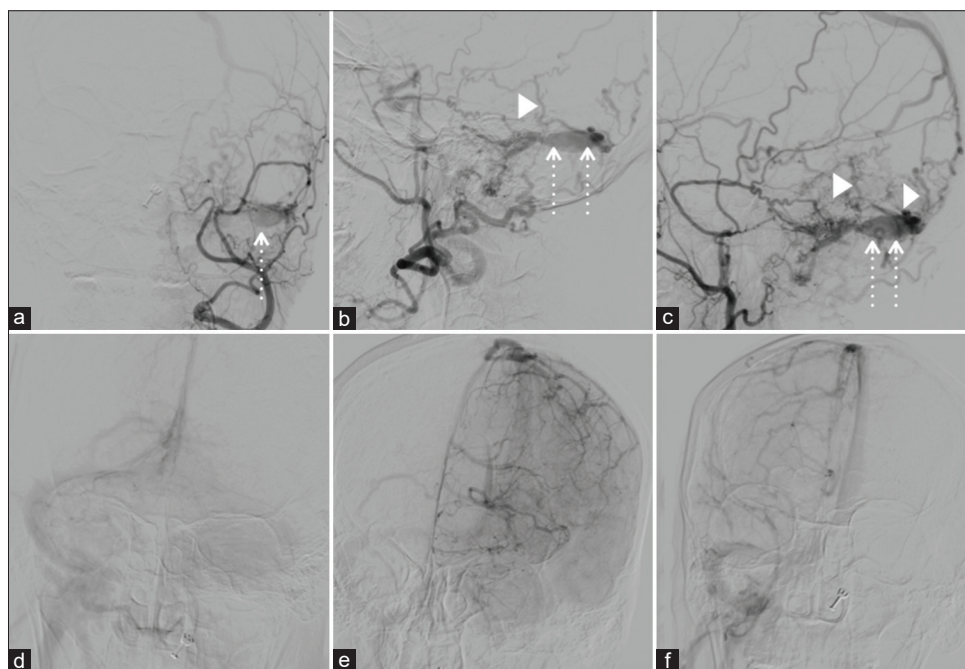


Figure 2: (a-c) Digital subtraction angiography images of selective left external carotid injections showed early opacification of the left transverse sinus (dotted arrows), which is isolated and having cortical venous reflux (arrowheads). (d-f) Delayed venous phase images of selective left vertebral, left internal carotid artery, and right internal carotid artery injections, respectively, showing no drainage into the left transverse sinus

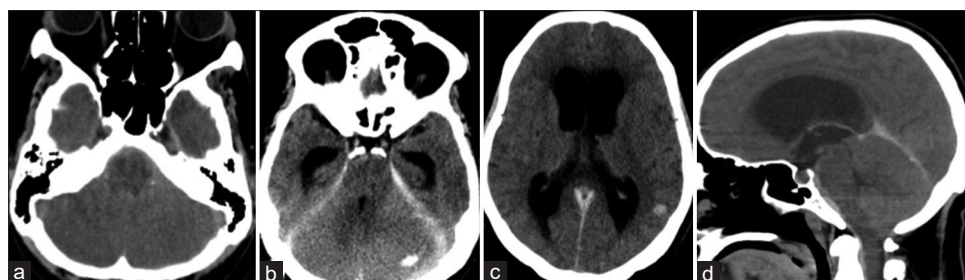


Figure 3: (a-c) Axial sections of computed tomography of brain on day 2 of admission showing effaced basal cisterns with dilated lateral ventricles. (d) Sagittal section of computed tomography of the brain showing crowded posterior fossa components

craniectomy, and simultaneous intraoperative direct embolization of DAVF of the left transverse sinus was planned.

Operative technique

The patient was placed in a prone position. A 6 cm posterior midline incision was made and deepened till the bone.

The underlying bleeding vessels were cauterized, and self-retracting clips were applied. Suboccipital craniotomy was done, and bone was nibbled up to C1 vertebra. The foramen magnum was decompressed. The dura covering the cerebellum was opened. After the decompressive craniectomy, the upper margin of craniotomy was drilled to expose the posterior aspect of the left transverse sinus.

It was punctured directly using a 21-G micropuncture needle (Cook, Bloomington, Indiana, USA). Once backflow of blood is confirmed through the needle, a 0.018" wire was then advanced through the needle into the isolated segment of the left transverse sinus under C-arm fluoroscopic guidance. The needle was exchanged for a micropuncture sheath (4F radial sheath) (Avanti+, Cordis, Santa Clara, USA). An Echelon-10 (ev3, Toledo Way, Irvine, USA) and Synchro 0.014 (Stryker neurovascular) guidewire assembly was introduced through the micropuncture sheath into the left transverse sinus. The microcatheter was primed with dimethyl sulfoxide. Under fluoroscopic guidance, embolization of isolated left transverse sinus was done using graded injections of liquid embolic agent ethyl vinyl alcohol polymer Onyx-18 (ev3, Toledo Way, Irvine, USA). The injection of Onyx-18 was done till complete cast is formed in the isolated sinus, and reflux was allowed into foothills of feeding arteries and draining veins [Figure 4]. The micropuncture sheath was removed from the transverse sinus, and bleeding was controlled by electrocautery. After the completion of the operative procedure, the patient was shifted to neuroangiography suite for a DSA. Selective injection of the carotid arteries and vertebral arteries revealed no residual AVF or cortical venous reflux [Figures 5 and 6]. CT scan of the brain done on postoperative day 4 revealed spacious basal cisterns and decreased dilatation of lateral ventricles as compared to preoperative CT scan [Figure 6]. Postprocedure, the patient was monitored in neurointensive care. The patient gradually improved and was extubated on postoperative day 3. The patient was discharged in a neurologically stable condition on day 9. At 1-year follow-up, her neurological condition was stable with no recurrence of symptoms.

Discussion

DAVFs comprise about 10%–15% of intracranial vascular malformations.^[9] Transverse-sigmoid sinus DAVF is one of

the most common types of DAVFs.^[10] DAVFs signify an abnormal connection between dural or meningeal arteries and venous system of the brain, with arterialization of veins and resulting in venous hypertension. Demonstration of surplus of leptomeningeal vessels on cross-sectional imaging is an imaging marker of venous congestion in DAVFs.^[11]

The raise in ICP in the index case can be attributed to hydrocephalus, cerebellar venous congestion, and edema. Any pathophysiological process impeding cerebrospinal fluid (CSF) or venous outflow would result in hydrocephalus. Nonobstructive hydrocephalus in DAVF is explained by venous hypertension causing increased dural sinus pressure, which results in decreased CSF absorption as higher CSF pressure is necessary to drive bulk flow of CSF across the meninges.^[2,12] The drainage of CSF to mitigate the raised ICP is contraindicated in such cases and in fact may exacerbate the clinical worsening, as it may increase the venous sinus and CSF pressure gradient further. The other important cause of cerebellar edema and hemorrhages in posterior fossa is arterialization of cerebellar cortical veins causing significant impediment of blood flow from capillaries to the venous circulation, resulting in significant interstitial edema and cerebellar hemorrhage.^[12] In DAVF with venous hypertension, the raise in ICP is usually insidious in onset; however, an acute raise in ICP as in the index case is very unusual. It can be probably explained by breakthrough of venous hypertension contributed by extensive arterialized cerebellar cortical veins in the posterior fossa that is too much to compensate for the volume of CSF and brain.^[2]

The clinical signs, symptoms, and imaging features of DAVF are reversible if recognized and treated early. Treatment of DAVFs is aimed at obliterating the arteriovenous shunting that is leading to venous hypertension.

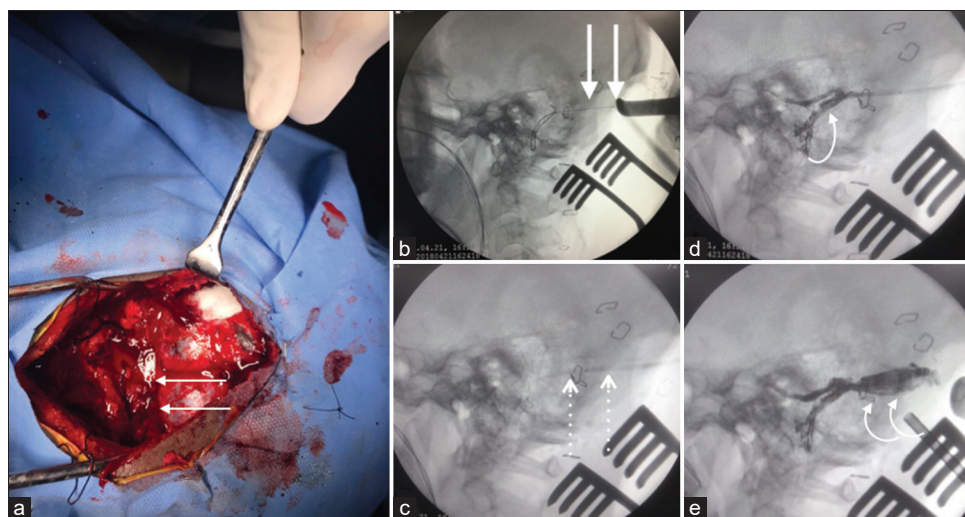


Figure 4: (a) Intraoperative photograph showing suboccipital craniotomy and exposed left transverse sinus (thin arrows) (b-e). Intraoperative fluoroscopic image demonstrating micropuncture needle and guidewire placement (thick arrows), microcatheter positioning (dotted arrows), and Onyx cast in the isolated left transverse sinus (curved arrows)

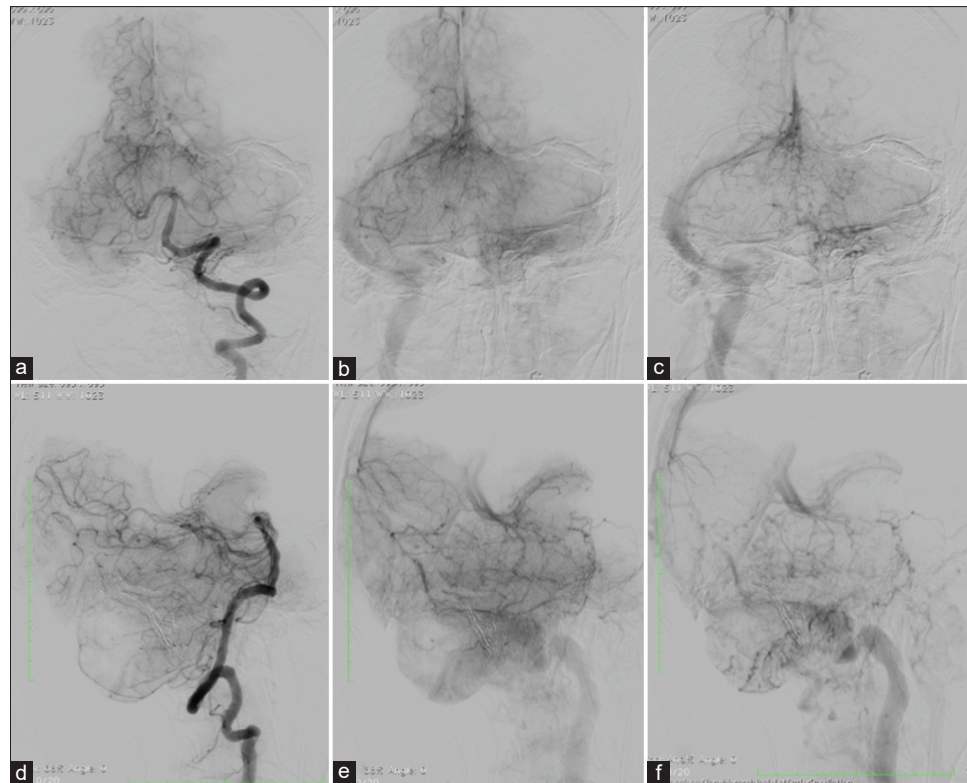


Figure 5: (a-f) Postoperative digital subtraction angiography of left VA injection demonstrating no residual dural arteriovenous fistula with no significant stasis in the posterior fossa venous circulation

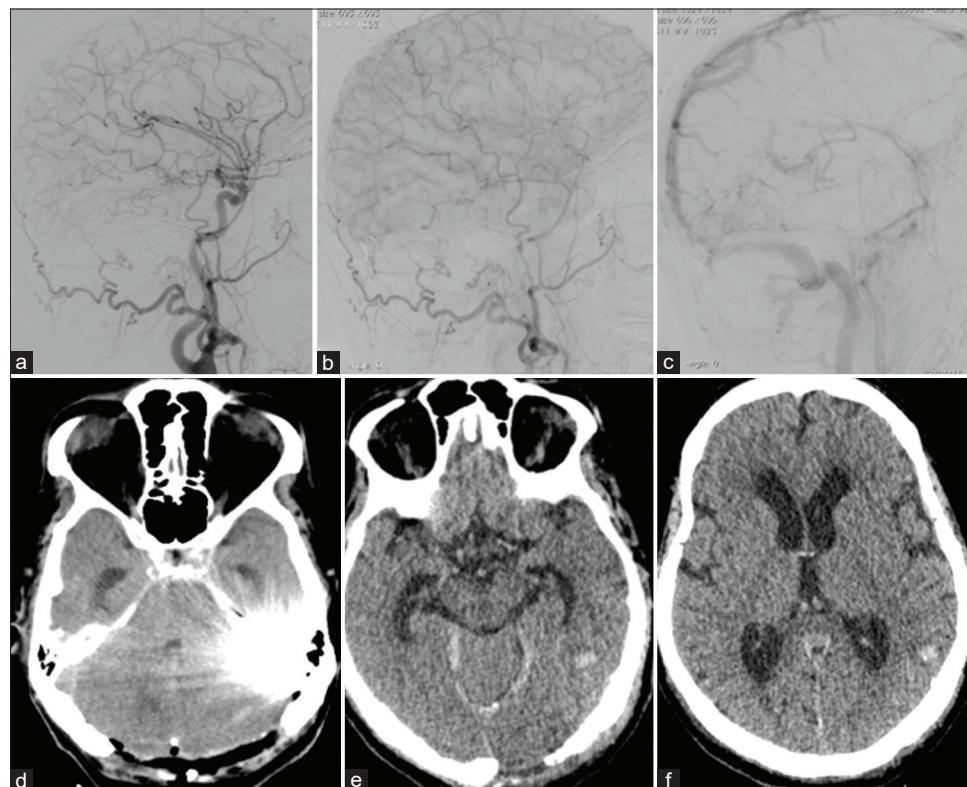


Figure 6: (a-c) Postoperative digital subtraction angiography of left internal carotid artery injection demonstrating no residual dural arteriovenous fistula. (d-f) Axial sections of computed tomography of brain demonstrating occipital craniotomy postoperative changes with Onyx cast artifacts and decreased lateral ventricular dilatation

Treatment options in the index case include endovascular embolization (transarterial/venous) and microsurgery. For the treatment of DAVF, endovascular transarterial or transvenous embolization is usually the first-line option.^[9] In the index case, the endovascular option was chosen over microsurgical excision, as microsurgery option would have required more extensive exposure and ligation of multiple arterialized cortical veins. Several reports have been published previously using the transcranial route for venous access.^[3-9] In the index case, transarterial approach using Onyx Liquid Embolic System was considered initially; however, due to acute neurological deterioration, the patient was taken up for emergency decompressive craniectomy, and in the same sitting, intraoperative transcranial embolization of DAVF was performed. Single-stage craniectomy and embolization in the setting of acutely raised ICP in DAVF have not been described before. As a rule, DAVF embolization with liquid embolics such as Onyx is done under roadmap guidance. Transcranial venous embolization under C-arm guidance in the usual neurosurgical operating room should be done with caution, as nontarget embolization of the liquid embolic agent may not be detected on simple fluoroscopy without a roadmap. In the index case, percolation of Onyx into isolated transverse sinus, draining cortical venous foothills, and arterial feeders was considered to be a finishing point. The targeted venous pouch was isolated, and it was in communication with only the cortical veins, and it was angiographically demonstrated to be isolated from the rest of the dural venous sinuses, so the chance of nontarget embolization to normal venous circulation was very minimal. Percolation of Onyx into the foothills of draining cortical veins was acceptable as they had flow reversal secondary to arterialization, and they had no contribution to normal brain venous drainage.

Conclusion

DAVF presenting as acute raise in ICP is very rare. Emergency management by transcranial embolization in the same stage after the decompressive craniectomy may be safe and effective in this specific clinical setting.

Declaration of patient consent

The authors certify that they have obtained all appropriate patient consent forms. In the form, the legal guardian has given his consent for images and other clinical information to be reported in the journal. The guardian understands that names and initials will not be published and due efforts will be made to conceal identity, but anonymity cannot be guaranteed.

Financial support and sponsorship

Nil.

Conflicts of interest

There are no conflicts of interest.

References

1. Cognard C, Gobin YP, Pierot L, Bailly AL, Houdart E, Casasco A, *et al.* Cerebral dural arteriovenous fistulas: Clinical and angiographic correlation with a revised classification of venous drainage. *Radiology* 1995;194:671-80.
2. Cognard C, Casasco A, Toevi M, Houdart E, Chiras J, Merland JJ. Dural arteriovenous fistulas as a cause of intracranial hypertension due to impairment of cranial venous outflow. *J Neurol Neurosurg Psychiatry* 1998;65:308-16.
3. Endo S, Kuwayama N, Takaku A, Nishijima M. Direct packing of the isolated sinus in patients with dural arteriovenous fistulas of the transverse-sigmoid sinus. *J Neurosurg* 1998;88:449-56.
4. Kuwayama N, Endo S, Kitabayashi M, Nishijima M, Takaku A. Surgical transvenous embolization of a cortically draining carotid cavernous fistula via a vein of the Sylvian fissure. *AJNR Am J Neuroradiol* 1998;19:1329-32.
5. Bruneau M, Lubicz B, Pirotte B, Taib NO, Wikler D, Brotchi J, *et al.* Selective image-guided venous sinus exposure for direct embolization of dural arteriovenous fistula: Technical case report. *Surg Neurol* 2008;69:192-6.
6. Houdart E, Saint-Maurice JP, Chapot R, Ditchfield A, Blanquet A, Lot G, *et al.* Transcranial approach for venous embolization of dural arteriovenous fistulas. *J Neurosurg* 2002;97:280-6.
7. Liu JK, Choudhry OJ, Barnwell SL, Delashaw JB Jr, Dogan A. Single stage transcranial exposure of large dural venous sinuses for surgically-assisted direct transvenous embolization of high-grade dural arteriovenous fistulas: Technical note. *Acta Neurochir (Wien)* 2012;154:1855-9.
8. Zink WE, Meyers PM, Connolly ES, Lavine SD. Combined surgical and endovascular management of a complex posttraumatic dural arteriovenous fistula of the tentorium and straight sinus. *J Neuroimaging* 2004;14:273-6.
9. Chaichana KL, Coon AL, Tamargo RJ, Huang J. Dural arteriovenous fistulas: Epidemiology and clinical presentation. *Neurosurg Clin N Am* 2012;23:7-13.
10. Gandhi D, Chen J, Pearl M, Huang J, Gemmete JJ, Kathuria S. Intracranial dural arteriovenous fistulas: Classification, imaging findings, and treatment. *AJNR Am J Neuroradiol* 2012;33:1007-13.
11. Willinsky R, Terbrugge K, Montanera W, Mikulis D, Wallace MC. Venous congestion: An MR finding in dural arteriovenous malformations with cortical venous drainage. *AJNR Am J Neuroradiol* 1994;15:1501-7.
12. Lee SK, Willinsky RA, Montanera W, terBrugge KG. MR imaging of dural arteriovenous fistulas draining into cerebellar cortical veins. *AJNR Am J Neuroradiol* 2003;24:1602-6.