

Spontaneous Transformation of Vestibular Schwannoma into Malignant Peripheral Nerve Sheath Tumor

Abstract

Although radiosurgery-induced transformation of vestibular schwannoma (VS) into malignant peripheral nerve sheath tumor (MPNST) is being widely discussed, little attention is paid to the spontaneous transition of these tumors. Although the pathogenesis of this phenomenon remains uncertain, growing number of reported cases might call to notice them. We present a case of a 29-year-old woman who suffered right-sided hearing loss which remained untreated for 4.5 years. Magnetic resonance imaging revealed a right cerebellopontine tumor and the patient underwent tumor removal through retrosigmoid approach. Pathologically, the tumor was benign acoustic schwannoma with increased Ki-67 8%–10%. The tumor relapsed only 6 months later and was removed again—this time it was malignant peripheral nerve sheath tumor MPNST. The patient was treated with stereotactic radiotherapy, but despite that tumor growth was observed again and she underwent the third operation. Later on, tumor progression was noted with multiple intraaxial metastases and patient died 17 months after the diagnosis of MPNST had been confirmed. This is a seventh documented case of spontaneous transformation of VS into MPNST, which is clinically important for recording.

Keywords: Malignant peripheral nerve sheath tumor, malignant transformation, vestibular schwannoma

Introduction

Intracranial malignant peripheral nerve sheath tumor (MPNST) is a very rare entity and most often arise from the fifth cranial nerve, followed by the seventh and eighth nerves.^[1,2] Spontaneous malignant transformation of a previously diagnosed benign vestibular schwannoma (VS) is an even more scarce situation with only five cases described up to date.^[3-7] We report a patient with benign acoustic neurinoma which underwent a spontaneous malignant transformation, as confirmed by pathological studies, and then demonstrated rapid growth and secondary generalization.

Case Report

History and examination

The 29-year-old woman with no signs of von Recklinghausen disease presented in August 2012 with a 5-year history of right-sided hearing loss, which initially originated during her first pregnancy and had remained untreated for more than

4.5 years. During the second pregnancy, hearing loss on the right continued to decline, meanwhile, the patient noticed a headache, handwriting changes, and gait disturbances. Neurological examination revealed right-sided hearing loss and diminished sensation in the distribution of the right fifth cranial nerve and facial nerve palsy (House and Brackmann II); the remaining cranial nerves were intact. She also demonstrated right-sided cerebellar signs (adiadochokinesis, gait instability). There were no stigmata of neurofibromatosis. Magnetic resonance imaging (MRI) revealed a mass in the right cerebellopontine angle with clear boundaries and a high-intensity signal on T1-weighted images. This tumor was widening auditory canal and compressing the right cerebellar hemisphere, pons, and fourth ventricle [Figure 1].

The patient admitted to our clinic. She signed written consent form and agreed to have her data published. Institutional approval for clinical data collection and further publishing was also obtained.

**Artem Belyaev,
Dmitry Usachev,
Vadim Shimansky,
Dzhemil Odamanov,
Lyudmila Shishkina¹,
Marina Ryzhova¹,
Andrey Golanov²**

*Departments of Neurooncology,
¹Neuropathology and
²Radiotherapy and Radiosurgery,
Burdenko Neurosurgery Center,
Moscow, Russia*

Address for correspondence:

Artem Belyaev,
Burdenko Neurosurgery Institute,
4th Tverskaya-Yamskaya str., 16,
Office 1241, Moscow, Russian
Federation.
E-mail: belyaev@nsi.ru

Access this article online

Website: www.asianjns.org

DOI: 10.4103/ajns.AJNS_251_16

Quick Response Code:



How to cite this article: Belyaev A, Usachev D, Shimansky V, Odamanov D, Shishkina L, Ryzhova M, *et al.* Spontaneous transformation of vestibular schwannoma into malignant peripheral nerve sheath tumor. *Asian J Neurosurg* 2018;13:810-3.

This is an open access journal, and articles are distributed under the terms of the Creative Commons Attribution-NonCommercial-ShareAlike 4.0 License, which allows others to remix, tweak, and build upon the work non-commercially, as long as appropriate credit is given and the new creations are licensed under the identical terms.

For reprints contact: reprints@medknow.com

First operation

In August 2012, the tumor was removed through retrosigmoid approach with no remnants left (as confirmed by helical computed tomography scan) [Figure 2].

Facial paresis on the right deteriorated (H and B IV), and the patient was fully ambulant by discharge 8 days after surgery. Pathological investigation showed a tumor predominantly composed of spindle cells arranged in fasciculi with nuclear palisades mixed with more loosely arranged cells consistent with Antony A and B areas. Immunoperoxidase staining for S-100 and actin was strong in all sections. Staining for epithelial membrane antigen and desmin was negative. Therefore, the tumor was labeled as a typical neurinoma with increased Ki-67 index up to 8%–10% [Figure 3].

Six months later, the patient admitted to our clinic again with complaints of headache, nausea, vomiting, and severe gait disturbance. MRI revealed a large contrast-enhancing mass in the right cerebellopontine angle partly destructing petrous temporal bone. The fourth ventricle was compressed and the brainstem displaced to the left [Figure 4].

Second operation

A right-sided suboccipital reexploration revealed a relatively firm tumor, adjacent to the V-XI cranial nerves, intimately attached to the brainstem, therefore, the tumor was removed subtotally with a strip left on the brainstem structures. The patient was discharged 9 days later at the same neurological condition as on admission.

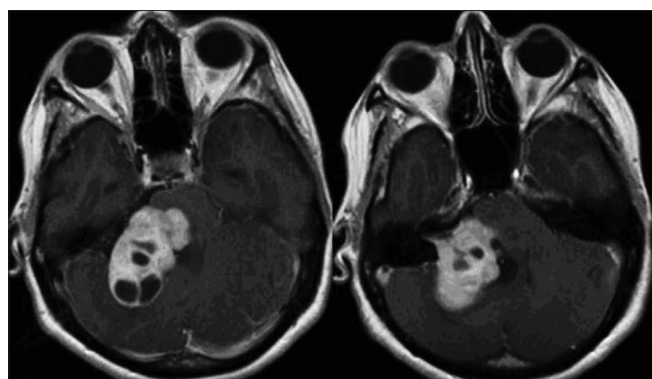


Figure 1: Preoperative magnetic resonance imaging scan

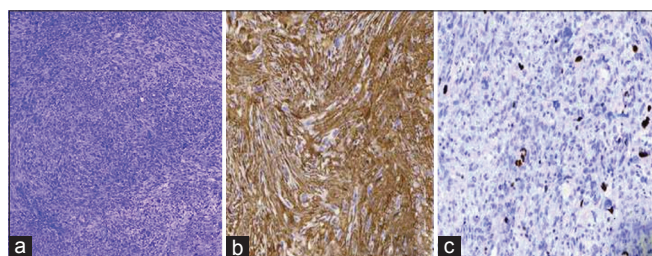


Figure 3: Histological examination of the tumor: (a) hematoxylin and eosin staining; (b) S-100 staining; (c) increased Ki-67 index up to 8%–10%

Histological examination of the tumor recurrence showed interlacing fasciculi of moderately pleomorphic spindle cells with hyperchromatic nuclei and frequent mitotic figures, indistinct cytoplasmic borders, and several areas of necrosis. In other areas, cells were more loosely arranged with some hyalinized blood vessels cuffed by proliferating tumor cells. Immunoperoxidase staining for S-100 showed it is scattered positivity. Staining for actin was positive in the vessels' wall. Staining for epithelial membrane antigen and desmin was negative. The tumor was labeled as MPNST [Figures 5 and 6].

In the postoperative period, tumor progression was noted and the patient underwent stereotactic radiotherapy (SRS) (“Novalis,” lesion volume 20.6 cm³, maximal tumor dose 62.97 Gy, mean dose 59.5 Gy).

She also had plastic surgery-trigeminal-facial nerve anastomosis for facial nerve palsy.

Ten months later, this patient admitted for the third time. She was in poor condition, unable to walk independently, and suffering severe headache and nausea. MRI revealed tumor progression both intra- and extracranially [Figure 7].

The third operation was performed through the same approach. Initially, large extracranial part of the tumor was removed; the tumor displaced brainstem medially, IX–XII nerves downward and V nerve anteriorly. This time, the tumor was well-perfused and more firm, but despite that, it was totally removed.

Histological examination was identical to the one on the second surgery.

The patient discharged 10 days later with no headache and/or nausea.

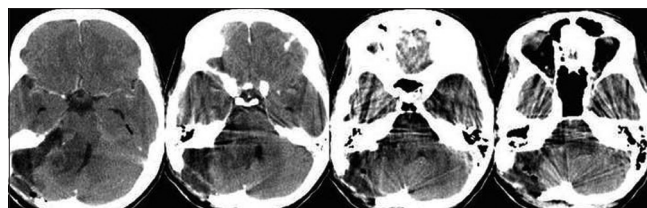


Figure 2: Postoperative computed tomography scan (radical removal of the tumor)

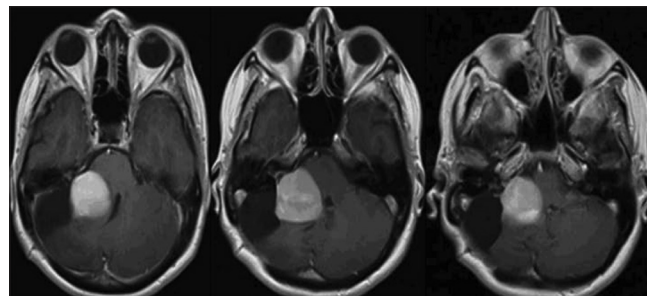


Figure 4: Tumor relapse

Two months later, the patient underwent ventricular-atrial shunt placement due to hydrocephalus.

Postoperative MRI revealed tumor progression; supratentorial metastasis cuffing left middle cerebral artery and multiple lesions affecting spinal dura [Figure 8].

The patient was referred for Gamma-Knife surgery. She died 1 month later.

Discussion

MPNST are relatively often observed in conjunction with von Recklinghausen disease, meanwhile cranial nerve tumors are generally benign and extremely rare undergo malignant transformation. Of these, MPNSTs of the eight nerves are the third most common; nevertheless, there are only six cases of spontaneous malignant transformation of VS described so far. The first clinical case of malignant schwannoma was reported by Kudo *et al.*^[5] more than 30 years ago. Technically, tumor transformation in that case has not been confirmed by dual pathological studies, but the 5-year-long history of hearing loss on the tumor side was in a great favor of initially benign neoplasm.

Gonzalez *et al.*^[3] reported a unique case of a “true” malignant schwannoma that was discovered within benign tumor during a debulking process. This was, probably, the most conclusive evidence of spontaneous malignant transformation of benign schwannomas.

The most recent description of the spontaneous transformation of VS into MPNST presented by Bashir *et al.*^[8] a relapse of the tumor (malignant this time) was documented 42 months after the initial surgery. The patient

had been monitored for 9 months, by the time, the case report was submitted with no signs of tumor recurrence after irradiation.

The median length of survival for MPNST in surgical series was 61 months.^[9] Intracranial MPNSTs possess substantially worse prognosis – for four out of five patients with the spontaneous transformation of VS into MPNST the mean survival time was 12 weeks; the fifth patient underwent three surgical tumor removals and was stable by the time case report was submitted (3 months after the first surgery).^[7] In our patient, all efforts were made to prolong survival, and the patient died 17 months after diagnosis of MPNST has been confirmed by pathological studies.

In the group of patients with initially malignant schwannomas ($n = 11$, including 1 pediatric patient)^[10-16] data on survival was available for 8 patients and comprised 11 months. Interestingly, the overall mean delay from radiation treatment of VS to its malignant expression comprised 85 months.^[17] Hanabusa *et al.*^[2] also state that the most malignant transformations of VS are caused by *de novo* transformations and not radiation induced. These facts leave in doubt the role of SRS in malignant transformation of VS and place emphasis on the natural course of the disease.

Malignant schwannomas are totally different from benign acoustic neurinomas. These tumors are extremely rare with only a few case reports available. Prognosis for MPNST is poor regardless all the treatment options (surgery, radiotherapy/radiosurgery, chemotherapy). Nevertheless, treatment guideline is needed to attempt more thorough tumor control and improve survival.

Conclusion

Malignant schwannomas occurring in patients with or without neurofibromatosis and/or previous irradiation are

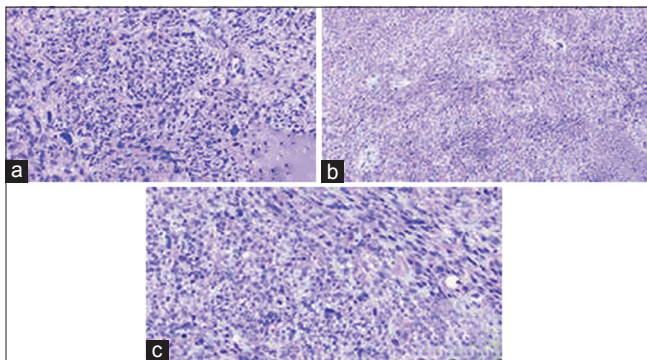


Figure 5: Relapsed tumor. Histological examination of the tumor recurrence showed interlacing fasciculi (a) of moderately pleomorphic spindle cells with hyperchromatic nuclei (b), and frequent mitotic figures (c), indistinct cytoplasmic borders, and several areas of necrosis

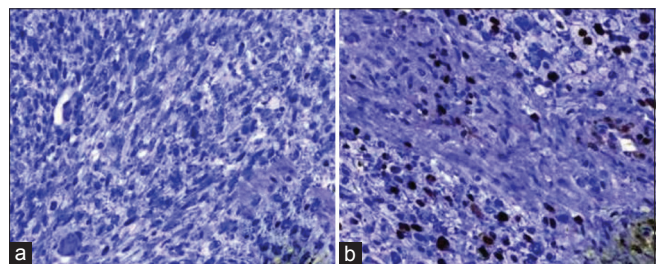


Figure 6: Relapsed tumor: (a) S-100 negative staining; (b) increased Ki-67 index up to 10%–15%

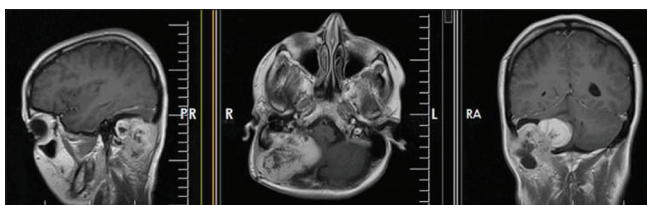


Figure 7: Second tumor relapse

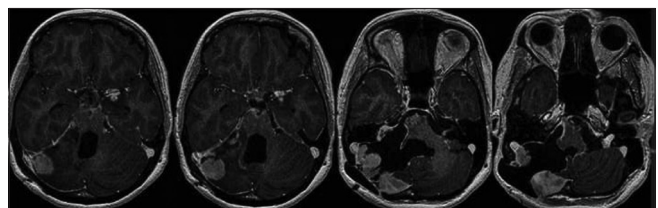


Figure 8: Tumor progression and supratentorial metastasis cuffing left middle cerebral artery

very rare. Invariably, they exhibit poor local control and rapid relapse. Despite the malignant transformation of VS after radiosurgery is discussed more frequently, this case raising the question of some malignant changes could have been a natural course of the disease.

Financial support and sponsorship

Nil.

Conflicts of interest

There are no conflicts of interest.

References

- Brooks JS, Freeman M, Enterline HT. Malignant "Triton" tumors. Natural history and immunohistochemistry of nine new cases with literature review. *Cancer* 1985;55:2543-9.
- Hanabusa K, Morikawa A, Murata T, Taki W. Acoustic neuroma with malignant transformation. Case report. *J Neurosurg* 2001;95:518-21.
- Gonzalez LF, Lekovic GP, Eschbacher J, Coons S, Spetzler RF. A true malignant schwannoma of the eighth cranial nerve: Case report. *Neurosurgery* 2007;61:E421-2.
- Han DH, Kim DG, Chi JG, Park SH, Jung HW, Kim YG. Malignant triton tumor of the acoustic nerve. Case report. *J Neurosurg* 1992;76:874-7.
- Kudo M, Matsumoto M, Terao H. Malignant nerve sheath tumor of acoustic nerve. *Arch Pathol Lab Med* 1983;107:293-7.
- McLean CA, Laidlaw JD, Brownbill DS, Gonzales MF. Recurrence of acoustic neurilemoma as a malignant spindle-cell neoplasm. Case report. *J Neurosurg* 1990;73:946-50.
- Son EI, Kim IM, Kim SP. Vestibular schwannoma with malignant transformation: A case report. *J Korean Med Sci* 2001;16:817-21.
- Bashir A, Poulsgaard L, Broholm H, Fugleholm K. Late malignant transformation of vestibular schwannoma in the absence of irradiation: Case report. *J Neurosurg* 2016;125:372-7.
- Wong WW, Hirose T, Scheithauer BW, Schild SE, Gunderson LL. Malignant peripheral nerve sheath tumor: Analysis of treatment outcome. *Int J Radiat Oncol Biol Phys* 1998;42:351-60.
- Best PV. Malignant triton tumour in the cerebellopontine angle. Report of a case. *Acta Neuropathol* 1987;74:92-6.
- Chen L, Mao Y, Chen H, Zhou LF. Diagnosis and management of intracranial malignant peripheral nerve sheath tumors. *Neurosurgery* 2008;62:825-32.
- Hernanz-Schulman M, Welch K, Strand R, Ordia JI. Acoustic neuromas in children. *AJNR Am J Neuroradiol* 1986;7:519-21.
- Maeda M, Jozaki T, Baba S, Muro H, Shirasawa H, Ichihashi T. Malignant nerve sheath tumor with rhabdomyoblastic differentiation arising from the acoustic nerve. *Acta Pathol Jpn* 1993;43:198-203.
- Mrak RE, Flanigan S, Collins CL. Malignant acoustic schwannoma. *Arch Pathol Lab Med* 1994;118:557-61.
- Saito T, Oki S, Mikami T, Kawamoto Y, Yamaguchi S, Kuwamoto K, *et al.* Malignant peripheral nerve sheath tumor with divergent cartilage differentiation from the acoustic nerve: Case report. *No To Shinkei* 2000;52:734-9.
- Scheithauer BW, Erdogan S, Rodriguez FJ, Burger PC, Woodruff JM, Kros JM, *et al.* Malignant peripheral nerve sheath tumors of cranial nerves and intracranial contents: A clinicopathologic study of 17 cases. *Am J Surg Pathol* 2009;33:325-38.
- Seferis C, Torrens M, Paraskevopoulou C, Psychidis G. Malignant transformation in vestibular schwannoma: Report of a single case, literature search, and debate. *J Neurosurg* 2014;121 Suppl 2:160-6.