

Spontaneous Carotid Cavernous Fistula in Young Female with Anti-thrombin III Deficiency

Abstract

A 27-year-old female patient presented with headache, vomiting, and visual disturbances who was evaluated and detected to have a direct carotid cavernous fistula (CCF). Secondary causes were ruled out, and she was treated with coil occlusion and glue injection. A month after almost complete clinical recovery, she developed deep vein thrombosis of left thigh. Subsequent work-up revealed antithrombin III (ATIII) deficiency in her. To the best of our knowledge, this is the first reported case of ATIII deficiency associated with CCF. This case shows the importance of working up for a primary etiology if any, to prevent further complications after surgery.

Keywords: Antithrombin III deficiency, carotid cavernous fistula, deep vein thrombosis, sinus thrombosis

**Ram Narayan,
Mansoor
Cherumkuzhiyil
Abdulla**

*Department of General
Medicine, MES Medical
College, Malappuram, Kerala,
India*

Introduction

Carotid cavernous fistula (CCF) is a fatal abnormal communication between internal or external carotid artery and cavernous sinus. The lesion is classified as traumatic or spontaneous (based on etiology), high or low (based on the velocity of flow) and direct or dural (based on anatomy). CCF is almost always traumatic and 70%–90% are direct. Here, we discuss a young female who presented with spontaneous direct CCF with a rare association.

Case Report

A 27-year-old female with no premorbidities or trauma presented with right hemicranial headache, projectile vomiting, redness, pain, blurring of vision right eye for 21 days. A week ago, she had developed diplopia on looking to the right. She had bilateral proptosis, chemosis, periorbital edema, and drooping of the right eyelid. Nervous system examination revealed visual acuity of 6/18 both eyes with the normal visual field by confrontation, lateral rectus palsy on the right and minimal paresis of the third, fourth, and sixth cranial nerves on the left. Bilateral orbital bruit was present. Corneal reflexes were absent bilaterally, and sensation in the region of the right ophthalmic division of trigeminal nerve was decreased.

Her complete blood count, blood sugar, renal, liver thyroid functions, electrolytes, prothrombin time, and activated partial thromboplastin time were normal. Magnetic resonance imaging of the brain showed mildly prominent right superior ophthalmic vein and bilaterally enlarged cavernous sinuses with multiple flow voids adjacent to internal carotid arteries (ICAs) and flow-related enhancement in time-of-flight magnetic resonance angiography suggestive of carotid-cavernous fistula (CCF) [Figure 1a]. Digital subtraction angiography showed right CCF with multiple rents in laceral and cavernous segments of right ICA [Figure 1b]. A diagnosis of spontaneous CCF was made after ruling out all secondary causes, including connective tissue diseases. 6F Neuron 070 was navigated over the guide wire and tip parked in the right proximal petrous ICA. Two Echelon microcatheters were passed one after the other, and the distal end was parked in horizontal segment of right cavernous. The cavernous and proximal petrous ICA in right was occluded from distal to proximal aspect starting from anterior genu with eleven coils (Axium 3D 5 × 10, 4 × 8, 3 × 8, two 2 × 4, 3 × 6, 4 × 10, 6 × 20, GDC 6 × 15, 6 × 20, 7 × 30) and two coils were deployed through the rent into the cavernous sac followed by injection of 0.35 ml of Squid18 into the coil mass [Figure 1c]. Subsequent check

Address for correspondence:

*Dr. Ram Narayan,
Department of General
Medicine, MES Medical
College, Perinthalmanna,
Malappuram - 679 338,
Kerala, India.
E-mail: drramnarayan1283@
gmail.com*

Access this article online

Website: www.asianjns.org

DOI: 10.4103/ajns.AJNS_252_17

Quick Response Code:



How to cite this article: Narayan R, Abdulla MC. Spontaneous carotid cavernous fistula in young female with anti-thrombin III deficiency. Asian J Neurosurg 2019;14:266-8.

This is an open access journal, and articles are distributed under the terms of the Creative Commons Attribution-NonCommercial-ShareAlike 4.0 License, which allows others to remix, tweak, and build upon the work non-commercially, as long as appropriate credit is given and the new creations are licensed under the identical terms.

For reprints contact: reprints@medknow.com

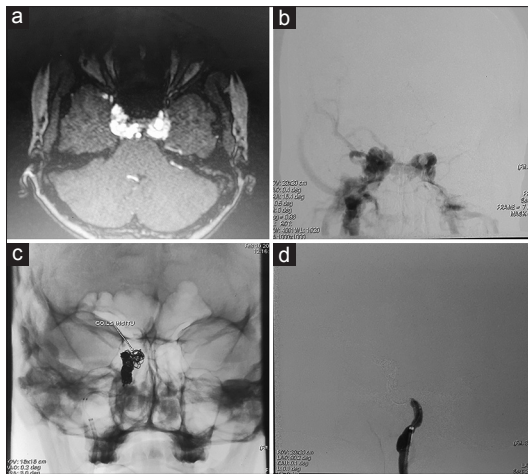


Figure 1: (a) Prominent right superior ophthalmic vein and bilateral enlarged cavernous sinuses with multiple flow voids adjacent to internal carotid arteries with flow related enhancement in time-of-flight magnetic resonance angiography. (b) - Digital subtraction angiography showed right cavernous fistula with multiple rents in laceral and cavernous segments of right internal carotid artery. (c) - Coil mass inside right cavernous and proximal petrous internal carotid artery. (d) - complete obliteration of fistula and flow beyond right petrous internal carotid artery in subsequent check angiogram

angiogram revealed complete obliteration of fistula and flow beyond right petrous ICA [Figure 1d]. She improved clinically and after 2 weeks only had mild diplopia looking to the right.

She was discharged from hospital 1 week after the procedure. She returned to her normal daily routine activities. However for mild diplopia while looking to the right, she was perfectly normal in her first follow-up visit 1 week after discharge. She was planned for an angiogram after 3 months to assess collateral formation if any and was sent home. One month after procedure, she presented with pain and swelling left thigh and was detected to have a deep vein thrombosis (DVT) of the left femoral vein. In view of young nonsituational DVT a prothrombotic workup was done which revealed very low antithrombin III (ATIII) level of 21.7% (normal 80%–120%). Homocysteine, factor V leiden mutation, protein S and protein C activities, antiphospholipid antibodies were normal. She was started on warfarin after bridging with heparin. She improved symptomatically and had no further thrombotic episodes for the past 12 months.

Discussion

CCF is commonly produced by trauma, atherosclerosis, systemic hypertension, collagen vascular diseases, pregnancy, and childbirth. None of the above-mentioned conditions were present in our patient. A less noticed cause of CCF is cerebral sinus thrombosis.^[1] Cerebral sinus thrombosis predisposes to CCF in two ways. It may be due to opening up of spontaneous channels between carotids and sinus due to the increased intracranial pressure produced by thrombosis in venous channels. The second possibility is thrombosis producing ischemia leading to

neovascularization.^[2] The absence of sinus thrombosis during presentation does not rule out this possibility as they are not always simultaneously seen. There are reports of CCF developing even 1 year after sinus thrombosis.^[3]

Thrombogenic conditions like ATIII deficiency are known to induce spontaneous thrombosis, including cerebral sinus thrombosis. A study conducted in Germany detected the higher prevalence of G20210A mutation in patients with CCF.^[4] A similar study in Japan found 22.2% of the study population with spontaneous CCF had protein S deficiency.^[5] However, the study was not statistically significant as the study population was small and prevalence of protein S deficiency was very high in the Japanese population. To the best of our knowledge, no case of CCF has been reported previously showing concurrent ATIII deficiency though similar mechanisms are plausible with all procoagulant conditions. Dural venous thrombosis was not thought of initially in our patient and later as the patient was already on warfarin; we did not do a computed tomographic venogram to look for the same. It is debatable whether to start anticoagulant therapy in a patient with spontaneous CCF and incidentally detected concurrent ATIII deficiency without any other thrombotic manifestations. However, a search into probable underlying causes may be beneficial for better outcomes after surgery. This patient had a DVT later which led to her pro-coagulant workup and subsequent starting of warfarin. Since anticoagulation, she never had any further morbidities.

Conclusion

CCF is a potentially fatal illness. Underlying pro-coagulant conditions and sinus thrombosis may be checked for, especially in a young spontaneous CCF patient as anticoagulant therapy following corrective procedure may significantly improve long-term outcome and reduces recurrences.

Declaration of patient consent

The authors certify that they have obtained all appropriate patient consent forms. In the form the patient(s) has/have given his/her/their consent for his/her/their images and other clinical information to be reported in the journal. The patients understand that their names and initials will not be published and due efforts will be made to conceal their identity, but anonymity cannot be guaranteed.

Financial support and sponsorship

Nil.

Conflicts of interest

There are no conflicts of interest.

References

1. Kim CK, Shin JY, Chang JY, Lee SH. Spontaneous carotid

- cavernous fistula in a case with Protein S deficiency that newly developed ophthalmoplegia after embolization. *J Clin Neurol* 2011;7:164-7.
2. Kojima T, Miyachi S, Sahara Y, Nakai K, Okamoto T, Hattori K, *et al.* The relationship between venous hypertension and expression of vascular endothelial growth factor: Hemodynamic and immunohistochemical examinations in a rat venous hypertension model. *Surg Neurol* 2007;68:277-84.
 3. Preter M, Tzourio C, Ameri A, Bousser MG. Long-term prognosis in cerebral venous thrombosis. Follow-up of 77 patients. *Stroke* 1996;27:243-6.
 4. Gerlach R, Boehm-Weigert M, Berkefeld J, Duis J, Raabe A, Seifert V, *et al.* Thrombophilic risk factors in patients with cranial and spinal dural arteriovenous fistulae. *Neurosurgery* 2008;63:693-98.
 5. Izumi T, Miyachi S, Hattori K, Iizuka H, Nakane Y, Yoshida J, *et al.* Thrombophilic abnormalities among patients with cranial dural arteriovenous fistulas. *Neurosurgery* 2007;61:262-8.