

Idiopathic Epidural Lipomatosis Associated with Degenerative Discopathy: Grand Round Presentation of Unusual Lumbar Canal Stenosis Resolved by Weight Loss

Abstract

Here, we report a case of idiopathic epidural lipomatosis presented with a clinical picture of lumbar canal stenosis with neurogenic claudication which resolved completely only by weight loss. A 53-year-old obese male with a body mass index of 36 without significant past medical history presented to the outpatient clinic with neurogenic claudication and bilateral sciatic radiculopathy. Initially, magnetic resonance imaging (MRI) showed epidural lipomatosis at the level of L5 vertebral body and L5–S1 intervertebral disc. A conservative treatment was decided with dietary regime program. After 6 months of follow-up, his bilateral sciatic radiculopathy disappeared, and updated MRI showed complete disappearance of epidural lipomatosis. Based on the Grand Round case and relevant literature, we present a case of an unusual epidural lipomatosis with mixed clinical picture of degenerative lumbar disease. This case report set out the importance of Borré classification for differentiating the mixed clinical complaint of degenerative discopathy and epidural lipomatosis.

Keywords: Degenerative discopathy, epidural lipomatosis, weight losses

Introduction

Spinal epidural lipomatosis (SEL) is traditionally a rare disorder defined as hypertrophy or abnormal augmentation of the adipose tissue in the epidural space. Mechanical compression by this abnormal accumulation can cause spinal stenosis and radiculopathy, neurogenic intermittent claudication, or cauda equina syndrome. Clinical pictures of this disorder are indistinguishable to that of the degenerative process of facets joint hypertrophy, ligamentum flavum hypertrophy, and discopathy.^[1]

Case Report

A 53-year-old obese male patient presented to our outpatient department with chronic back pain and neurogenic claudication with bilateral sciatic radiculopathy predominantly the right side for 9 months. Sciatic pain was aggravated with standing and walking distance of <500 m. He was treated medically in another institution with anti-inflammatory medications, analgesic and physical therapy without any improvement. Hence, the patient was referred by his family physician to our center

for surgical intervention. He was morbidly obese (Class II) with a body mass index of 36, and no focal motor or sensory deficits were recognized. In addition, he had 5/5 strength of both lower limb extremities distal and proximal. Deep reflexes were 2+ at patellar and Achilles tendons bilaterally. Visual Analog Scale (VAS) of radicular pain was 5/10.

Magnetic resonance imaging (MRI) was performed on March 23, 2018, and demonstrated multilevel degenerative disc disease of the lumbar region, notably at the level L5–S1 [Figures 1 and 2]. T2-weighted views show Grade III of epidural lipomatosis according to the Borré classification with DuS/epidural fat (EF) ratio 0.29 [Tables 1 and 2], reaching posteriorly from L5 vertebral body downward to L5–S1 intervertebral disc.

Despite the patient preference of surgical intervention, conservative therapy was considered first as recommended by the literature^[2] with classic analgesic treatment and dietary regime program for 6 months.

Over a period of 6 months, his bilateral sciatic radiculopathy disappeared with VAS

Mohammad A. Alsofyani^{1,2}, Vincent Haignere¹, Sultan Alsalmi^{3,4}, Olivier Gille¹, Jean-Marc Vital¹, Vincent Pointillart¹, Louis Boissière¹, Ibrahim Obeid¹

¹Department of Spinal Surgery Unit, Bordeaux University Hospital, Bordeaux University, C.H.U Tripode Pellegrin, Place Amélie Raba Léon, 33076 Bordeaux, ²Department of Neurosurgery, Amiens University Medical Center, Amiens University, Amiens, France, ³Department of Orthopedics, College of Medicine and University Hospital, University of Hail, Hail City, ⁴Department of Neurosurgery, Imam Abdulrahman Bin Faisal University, Dammam City, Kingdom of Saudi Arabia

Address for correspondence:
Dr. Mohammad A. Alsofyani,
Department of Spinal Surgery
Unit, Bordeaux University
Hospital, Bordeaux University,
C.H.U Tripode Pellegrin,
Place Amélie Raba Léon,
33076 Bordeaux, France.
E-mail: mohd.alsfyani@gmail.
com

Access this article online

Website: www.asianjns.org

DOI: 10.4103/ajns.AJNS_255_19

Quick Response Code:



This is an open access journal, and articles are distributed under the terms of the Creative Commons Attribution-NonCommercial-ShareAlike 4.0 License, which allows others to remix, tweak, and build upon the work non-commercially, as long as appropriate credit is given and the new creations are licensed under the identical terms.

For reprints contact: reprints@medknow.com

How to cite this article: Alsofyani MA, Haignere V, Alsalmi S, Gille O, Vital JM, Pointillart V, et al. Idiopathic epidural lipomatosis associated with degenerative discopathy: Grand round presentation of unusual lumbar canal stenosis resolved by weight loss. Asian J Neurosurg 2020;15:180-3.

Submission: 14-08-2019 **Accepted:** 13-11-2019
Published: 25-02-2020

of radicular pain 0/10 after he was able to lose 16 kg; he had an updated MRI on December 10, 2018, which showed complete disappearance of epidural lipomatosis [Figures 1 and 2]. Despite his back pain did not improve due to degenerative lumbar stenosis, rehabilitation was established to improve his back pain.

Discussion

SEL can be classified into idiopathic and secondary causes.^[3] Therefore, according to the literature, SEL is frequently secondary to the local^[4] or systemic^[3,5] use of steroid and endocrine diseases with increased serum endogenous corticosteroid as seen in Cushing's syndrome.^[6] However, the absence of history of steroid intake or endocrine disorders does not exclude SEL diagnosis, studies have shown obesity as a factor associated with SEL pathogenesis.^[2,7-12] Idiopathic SEL was first reported in a woman with morbid obesity in 1982 by Badami and Hinck,^[12] and in 1991, the term idiopathic SEL was defined by Haddad *et al.*^[13]

Al-Khawaja *et al.*^[2] reported the segment involved by idiopathic epidural lipomatosis and showed that 65% of lumbar segments and 35% of thoracic segments. Yildirim *et al.*^[7] published in 2016, one of the largest retrospective case-control database studies including 199 patients diagnosed with SEL, 90.1% presented with

back pain, whereas 76.3% complained of radicular pain, and 28.7% reported neurological deficit. MRI is still the gold standard for diagnosis and evaluating SEL.^[14,15] In 2003, the classification of SEL was first described by Borré *et al.*^[16] based on the following measurements seeing in axial plane of MRI [Figure 3]: anteroposterior diameter of the dural sac (A-Pd DuS), anteroposterior width of the EF located anteriorly to the dural sac (Segment A), anteroposterior width of the EF located posteriorly to the dural sac (Segment B), and anteroposterior diameter of the spinal canal (A-Pd Spi C), which defined as the sum of the A-Pd DuS + Segments A and B.

They developed an MRI grading system for assessing the relation between EF and DuS [Table 1]. This grading system is used only for the lumbosacral region. Our patient was classified as having idiopathic SEL grade III according to the Borré classification, after dietary planning for 7 months, he was classified as grade I [Table 2].

Kuhn *et al.*^[17] proposed the “Y sign” found in the axial plane resulting from compression of epidural space into the shape of “Y” letter, and this sign is seen only with relatively severe SEL.

Treatment of SEL varies from conservative to surgical decompression.^[7] Conservation treatment includes management of underlying cause as in endocrine disorders, weight loss, and reduction of steroid intake if possible. Surgical treatment is indicated when conservative management is not effective. To our knowledge, eight cases^[8-10,13,18-21] were reported of idiopathic SEL treated conservatively with the disappearance of neurological symptoms [Table 3]. In five cases, MRI is documented before and after the conservative treatment,^[8,18-21] unlike the other three cases, where there is no documented MRI at all.^[9,10,13] In this case, we reported the sixth case report of SEL associated with degenerative disc disease presenting with chronic back pain and bilateral sciatic radiculopathy secondary to moderate obesity, with improvement after daily diet meal plan and documented

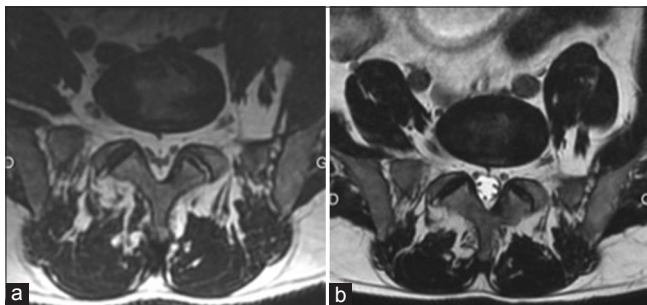


Figure 1: Before (a) and after (b) axial T2 images on magnetic resonance imaging demonstrating epidural lipomatosis after a 16 kg weight loss from March 2018 to December 2018

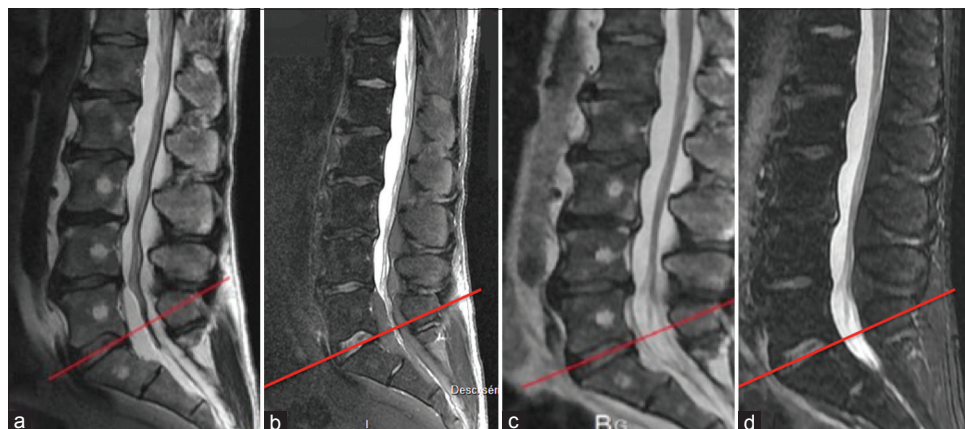


Figure 2: (a and b) Before and (c and d) after sagittal T2 and Stir sequence magnetic resonance imaging demonstrating less epidural lipomatosis after 7 months of dietary planning

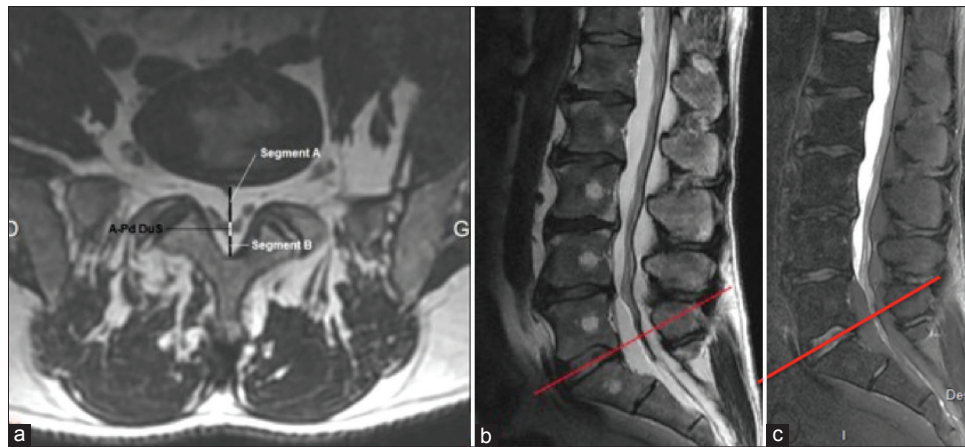


Figure 3: (a) Axial T2-weighted magnetic resonance imaging. A-Pd DuS anteroposterior width of the dural sac; Segment A: anteroposterior width of the epidural fat at the ventral epidural space; Segment B: anteroposterior width of the epidural fat at the dorsal epidural space. (b) sagittal T2-weighted magnetic resonance imaging. The red line shows the selected level. (c) Stir sequence magnetic resonance imaging

Table 1: The classification of spinal epidural lipomatosis based on magnetic resonance imaging measurements according to Borré *et al.*^[16]

MRI grade	DuS/EF ratio	EF/Spi C ratio (%)	Interpretation
0	≥1.5	≤40	Normal amount of EF
I	1.49-1	41-50	Mild overgrowth of EF
II	0.99-0.34	51-74	Moderate overgrowth of EF
III	≤0.33	≥75	Severe overgrowth of EF

MRI – Magnetic resonance imaging; EF – Epidural fat

Table 2: Before and after magnetic resonance imaging grading measurements of our case report according to the Borré classification

	Segment A (mm)	Segment B (mm)	A-Pd DuS (mm)	EF (mm)	A-Pd Spi C (mm)	DuS/EF ratio	EF/Spi C index (%)
Before	10.2	5.9	4.8	16.1	20.9	0.29	77
After	4.2	5.5	11.8	9.7	21.5	1.21	45

EF – Epidural fat

Table 3: The list of the reported cases of “Idiopathic SEL treated conservatively” in the literature

Author	Year
Haddad <i>et al.</i>	1991
Rooij <i>et al.</i>	1994
Beges <i>et al.</i>	1994
Pouchot <i>et al.</i>	1995
Borstlap <i>et al.</i>	1995
Qasho <i>et al.</i>	1997
Maillot <i>et al.</i>	2006
Patel <i>et al.</i>	2013

SEL – Spinal epidural lipomatosis

by MRI before and after the disappearance of epidural lipomatosis.

Concerning the management of SEL, Al-Khawaja *et al.*^[2] carried out the first review that investigated the characteristics and management for 111 cases of SEL (idiopathic vs. secondary) from January 1966 to July 2006 using electronic databases such as

Medline, Embase, and PubMed. Overall, this review highlights the results of surgical management were 60% with complete disappearance of symptoms when the lesion involves the lumbar segments in both idiopathic and secondary SEL. In view of all that has been mentioned so far, one may suppose that the role of conservative treatment in SEL when it involves the lumbar segments.

Collectively, our case report with the literature^[8-10,13,18-21] outlines an important role for conservative treatment including dietary planning in the management of idiopathic SEL. Our patient presented as Grade III epidural lipomatosis with discopathy multilevel and has shown that the importance of Borré classification for knowing the severity of this lesion, especially when the patient complains with mixed clinical picture between epidural lipomatosis and degenerative discopathy.

Declaration of patient consent

The authors certify that they have obtained all appropriate patient consent forms. In the form the patient(s) has/have

given his/her/their consent for his/her/their images and other clinical information to be reported in the journal. The patients understand that their names and initials will not be published and due efforts will be made to conceal their identity, but anonymity cannot be guaranteed.

Financial support and sponsorship

Nil.

Conflicts of interest

There are no conflicts of interest.

References

- Kirkaldy-Willis WH, Wedge JH, Yong-Hing K, Reilly J. Pathology and pathogenesis of lumbar spondylosis and stenosis. *Spine (Phila Pa 1976)* 1978;3:319-28.
- Al-Khawaja D, Seex K, Eslick GD. Spinal epidural lipomatosis – A brief review. *J Clin Neurosci* 2008;15:1323-6.
- George WE Jr, Wilmot M, Greenhouse A, Hammeke M. Medical management of steroid-induced epidural lipomatosis. *N Engl J Med* 1983;308:316-9.
- McCullen GM, Spurling GR, Webster JS. Epidural lipomatosis complicating lumbar steroid injections. *J Spinal Disord* 1999;12:526-9.
- Fessler RG, Johnson DL, Brown FD, Erickson RK, Reid SA, Kranzler L. Epidural lipomatosis in steroid-treated patients. *Spine (Phila Pa 1976)* 1992;17:183-8.
- Noël P, Peppersack T, Vanbinst A, Allé JL. Spinal epidural lipomatosis in Cushing's syndrome secondary to an adrenal tumor. *Neurology* 1992;42:1250-1.
- Yildirim B, Puvanesarajah V, An HS, Novicoff WM, Jain A, Shen FH, *et al.* Lumbosacral epidural lipomatosis: A retrospective matched case-control database study. *World Neurosurg* 2016;96:209-14.
- Borstlap AC, van Rooij WJ, Sluzewski M, Leyten AC, Beute G. Reversibility of lumbar epidural lipomatosis in obese patients after weight-reduction diet. *Neuroradiology* 1995;37:670-3.
- Pouchot J, Si-Hassen C, Damade R, Bayeux MC, Mathieu A, Vinceneux P. Cauda equina compression by epidural lipomatosis in obesity. Effectiveness of weight reduction. *J Rheumatol* 1995;22:1771-5.
- Qasho R, Ramundo OE, Maraglino C, Lunardi P, Ricci G. Epidural lipomatosis with lumbar radiculopathy in one obese patient. Case report and review of the literature. *Neurosurg Rev* 1997;20:206-9.
- Kumar K, Nath RK, Nair CP, Tchang SP. Symptomatic epidural lipomatosis secondary to obesity. Case report. *J Neurosurg* 1996;85:348-50.
- Badami JP, Hinck VC. Symptomatic deposition of epidural fat in a morbidly obese woman. *AJNR Am J Neuroradiol* 1982;3:664-5.
- Haddad SF, Hitchon PW, Godersky JC. Idiopathic and glucocorticoid-induced spinal epidural lipomatosis. *J Neurosurg* 1991;74:38-42.
- Quint DJ, Boulos RS, Sanders WP, Mehta BA, Patel SC, Tiel RL. Epidural lipomatosis. *Radiology* 1988;169:485-90.
- Hierholzer J, Vogl T, Hosten N, Lanksch W, Felix R. Imaging in epidural lipomatosis. *Crit Rev Neurosurg* 1998;8:279-81.
- Borré DG, Borré GE, Aude F, Palmieri GN. Lumbosacral epidural lipomatosis: MRI grading. *Eur Radiol* 2003;13:1709-21.
- Kuhn MJ, Youssef HT, Swan TL, Swenson LC. Lumbar epidural lipomatosis: The "Y" sign of thecal sac compression. *Comput Med Imaging Graph* 1994;18:367-72.
- Patel AJ, Sellin J, Ehni BL, Tatsui CE. Spontaneous resolution of spinal epidural lipomatosis. *J Clin Neurosci* 2013;20:1595-7.
- van Rooij WJ, Borstlap AC, Canta LR, Tijssen CC. Lumbar epidural lipomatosis causing neurogenic claudication in two obese patients. *Clin Neurol Neurosurg* 1994;96:181-4.
- Beges C, Rousselin B, Chevrot A, Godefroy D, Vallee C, Berenbaum F, *et al.* Epidural lipomatosis. Interest of magnetic resonance imaging in a weight-reduction treated case. *Spine (Phila Pa 1976)* 1994;19:251-4.
- Maillot F, Mulleman D, Mammou S, Goupille P, Valat JP. Is epidural lipomatosis associated with abnormality of body fat distribution? A case report. *Eur Spine J* 2006;15:105-8.