

# Ruptured Distal Anterior Choroidal Artery Aneurysm Presenting as Isolated Intraventricular Hemorrhage: Case Report and Comprehensive Review of the Literature

## Abstract

Distal anterior choroidal artery (AChA) aneurysms are infrequent. We discuss the case of a 59-year-old patient who presented with an isolated intraventricular hemorrhage (IVH) secondary to a ruptured distal AChA aneurysm. Initial noninvasive cerebral computed tomography angiography revealed no evidence of an underlying vascular pathology. The patient underwent further digital subtraction cerebral angiography, which revealed an aneurysm arising from the distal AChA segment. The aneurysm was successfully treated with surgical clip ligation. The current study highlights the importance of considering a ruptured distal AChA aneurysm as a potential source of isolated IVH.

**Keywords:** Distal anterior choroidal artery aneurysm, intraventricular aneurysm, intraventricular hemorrhage

## Introduction

Intraventricular hemorrhage (IVH) in adults often presents as an extension of aneurysmal subarachnoid hemorrhage or hypertensive intracerebral hemorrhage. In cases of isolated IVH, consideration needs to be given to intraventricular pathologies such as tumors or vascular malformations. An aneurysm arising from the distal anterior choroidal artery (AChA) can be a potential source of spontaneous IVH, even with negative initial noninvasive angiography.

We report a case of isolated IVH secondary to a ruptured true distal AChA aneurysm of idiopathic origin that was successfully treated with surgical clip repair. A comprehensive literature review was performed to underscore the importance of considering distal AChA aneurysm as a potential underlying cause of isolated IVH.

## Case Report

A 59-year-old female presented with severe occipital headache, vomiting, and confusion over 3 days. Clinical examination did not demonstrate any focal neurological deficit. Cerebral computed tomography (CT) revealed isolated IVH [Figure 1] and subsequent CT angiography and magnetic resonance angiography (MRA) did not

reveal a potential source of hemorrhage. Selective right internal carotid artery (ICA) digital subtraction angiography (DSA) demonstrated a 4 mm aneurysm arising from the intraventricular segment of the distal right AChA [Figure 2a], adjacent to the known intraventricular hematoma.

The patient underwent a right temporal craniotomy and clipping of the aneurysm. A right middle temporal gyrus approach was performed to gain access into the temporal horn of the lateral ventricle. The intraventricular hematoma was carefully evacuated. Under stereotactic image guidance, the aneurysm was localized and then obliterated with a 5 mm angled Sugita aneurysm clip. Patency of the proximal and distal segment of the AChA was confirmed with intraoperative micro-Doppler ultrasound, and the aneurysm was resected. The patient recovered well following the surgery without neurological deficit. Postoperative DSA had demonstrated no evidence of residual aneurysm [Figure 2b]. Histopathological evaluation confirmed a true saccular intracranial aneurysm [Figure 3]. She remained well at 12-month follow-up.

## Discussion

AChA aneurysms are uncommon and account for 2%–5% of all intracranial

Chi Hau Tan<sup>1</sup>,  
Leon T. Lai<sup>1,2,3</sup>,  
Ronil V. Chandra<sup>2,3,4</sup>

<sup>1</sup>Department of Neurosurgery,  
<sup>2</sup>Department of Surgery,  
Monash University, <sup>3</sup>Monash  
Neurovascular Institute Clinic,  
<sup>4</sup>Interventional Neuroradiology  
Unit, Monash Health,  
Melbourne, Australia

### Address for correspondence:

Dr. Chi Hau Tan,  
Department of Neurosurgery,  
Monash Health, 246 Clayton  
Road, Clayton Victoria 3168,  
Australia.  
E-mail: chihautan@yahoo.com

### Access this article online

Website: [www.asianjns.org](http://www.asianjns.org)

DOI: 10.4103/ajns.AJNS\_256\_16

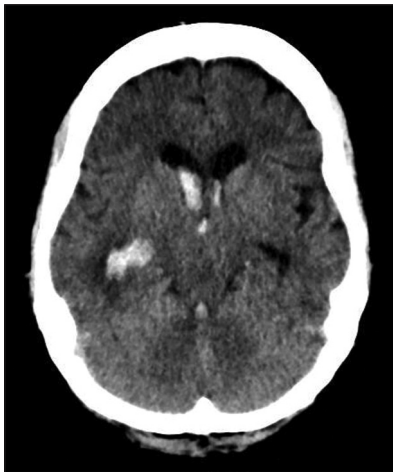
### Quick Response Code:



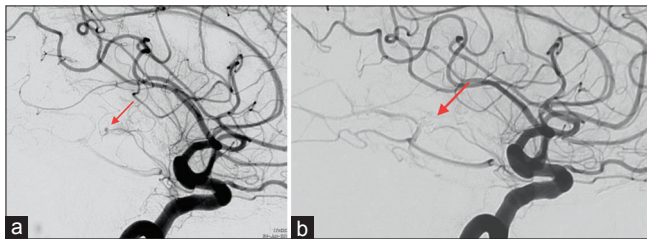
**How to cite this article:** Tan CH, Lai LT, Chandra RV. Ruptured distal anterior choroidal artery aneurysm presenting as isolated intraventricular hemorrhage: case report and comprehensive review of the literature. *Asian J Neurosurg* 2018;13:487-91.

This is an open access journal, and articles are distributed under the terms of the Creative Commons Attribution-NonCommercial-ShareAlike 4.0 License, which allows others to remix, tweak, and build upon the work non-commercially, as long as appropriate credit is given and the new creations are licensed under the identical terms.

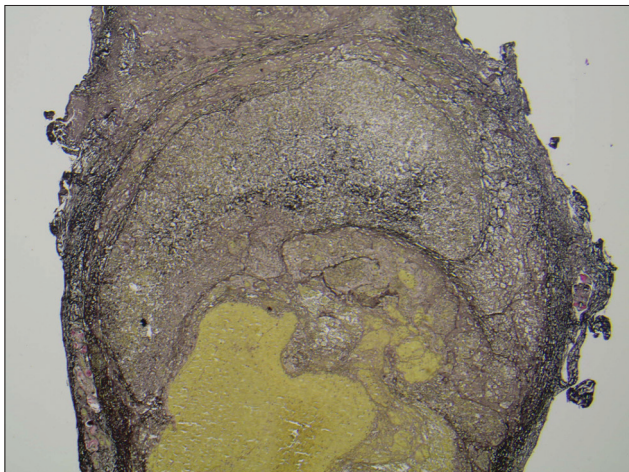
For reprints contact: [reprints@medknow.com](mailto:reprints@medknow.com)



**Figure 1:** Axial computed tomography brain showed acute intraventricular hematoma in all ventricles, greater on the right side



**Figure 2:** (a) Lateral oblique right internal carotid digital subtraction angiography revealed an aneurysm arising from distal anterior choroidal artery (arrow) beyond the plexal point. (b) Lateral oblique right internal carotid digital subtraction angiography posttreatment. The microsurgical clip (arrow) has completely obliterated the aneurysm. The anterior choroidal artery opacifies normally



**Figure 3:** Specimen with Verhoeff–Van Gieson elastic stain and magnification,  $\times 40$ . The aneurysm wall is clearly identified with rupture of the aneurysm at the superior aspect, compatible with a true aneurysm

aneurysms.<sup>[1]</sup> They commonly originate along the proximal segment of AChA, near its junction with the supraclinoid ICA. Distal AChA aneurysms are rare and originate from the intraventricular portion of AChA. To date, only thirty cases of ruptured intraventricular distal AChA aneurysms have been reported in the English literature. Previously

published articles have reported a high incidence of negative initial angiography.<sup>[2]</sup> This may be explained by the small size rendering visualization on conventional imaging difficult due to overlapping adjacent vessels. The aneurysm, in this case, was not detected on initial CT and MRA but was subsequently identified on conventional DSA due to strong clinical suspicion.

Our literature analysis highlighted that ruptured distal AChA aneurysm affects patients across a wide age group that ranges from 8 to 84 years old [Table 1]. Peak age of incidence was noted between 30 and 70 years (mean 45 years). Females were more commonly affected (female: male = 2.4:1). The size at which the aneurysms had ruptured was small (mean 4 mm; range 2–7 mm). The aneurysms were associated with various clinical conditions including Moyamoya disease (15 cases), idiopathic (ten cases), atherosclerosis (three cases), cerebral arteriovenous malformation (one case), trauma (one case), and iatrogenic (one case). Ruptured aneurysms arising from the intraventricular segment of AChA frequently result in extension of hematoma into the subarachnoid space (35%) and adjacent parenchyma (23%). However, isolated IVH has been reported in 15 cases previously.

The treatment of AChA aneurysms is not without significant morbidity. Injury to AChA can lead to severe neurological deficits including contralateral hemiplegia, hemianesthesia, and homonymous hemianopsia.<sup>[26]</sup> Before the 1990s, many cases of ruptured distal AChA aneurysms were treated conservatively. Of these, 60% resulted in death due to progressive clinical deterioration or rebleeds. Since then, many distal AChA aneurysms have been actively managed by a variety of therapeutic modalities. Out of thirty cases reported in the literature, 13 were treated with open microsurgery,<sup>[2,4,5,9,11,12,14-19]</sup> five through endovascular procedure,<sup>[1,20-22,24]</sup> and one through an endoscopic approach.<sup>[23]</sup> With the establishment of microsurgical techniques, surgical clip ligation has been utilized with good outcomes. In recent years, a number of ruptured distal AChA aneurysm cases have been successfully treated with endovascular techniques.

## Conclusion

The current study reports a case of ruptured distal AChA aneurysm presenting as isolated IVH and emphasizes the need for further invasive cerebral DSA when initial noninvasive vascular imaging modalities are negative. This study underscores the importance of clinical suspicion and early surgical or endovascular repair of these aneurysms to optimize clinical outcome.

## Acknowledgment

We would like to thank Dr. Ian Simpson at the Monash Health Pathology Department for his input to the histopathological findings.

Table 1: Overview of included studies on ruptured distal anterior choroidal artery aneurysms

Case	Author/year	Age	Gender	Presentations	Diagnosis	Etiology	Side	Size (mm)	Treatment	Histology	Outcome
1	Cressman and Hayes 1966 <sup>[3]</sup>	34	Male	ICH, SAH, IVH	DSA	Traumatic	Left	-	Conservative	-	Death from ruptured aneurysm
2	Butler et al., 1972 <sup>[4]</sup>	15	Female	ICH, SAH, IVH	DSA	Idiopathic	Left	-	Clipping	Cluster of abnormal blood vessels	Initial dysphasia and right hemiparesis, no deficit at 14 months
3	Papo et al., 1973 <sup>[5]</sup>	57	Female	SAH, IVH	DSA	Atherosclerosis	Right	-	Excision	False aneurysm	Persistent left hemiplegia/poor cognition
4	Takahashi 1980 <sup>[6]</sup>	59	Male	SAH	DSA	Moyamoya	Left	3.5	Unknown	-	Death from ruptured aneurysm
5	Tanaka et al., 1980 <sup>[7]</sup>	57	Female	SAH, IVH	DSA	Moyamoya	Right	-	Conservative	-	Left hemiplegia improved
6	Konishi et al., 1985 <sup>[8]</sup>	18	Female	SAH	DSA	Moyamoya	Right	6	Conservative	-	No deficit
7	Konishi et al.	13	Male	IVH	DSA	Moyamoya	Right	3	Conservative	-	Death from ruptured aneurysm
8	-	57	Female	IVH	DSA	Moyamoya	Right	2	Conservative	-	Death from ruptured aneurysm
9	-	34	Female	IVH	DSA	Moyamoya	Right	3	Conservative	-	Death from ruptured aneurysm
10	Knuckey et al., 1988 <sup>[9]</sup>	46	Female	SAH, IVH	DSA	Atherosclerosis	Left	-	Excision	Degenerative arterial wall with intramural thrombus	Persistent memory impairment
11	Inagawa et al., 1990 <sup>[10]</sup>	75	Female	IVH, SAH	DSA	Idiopathic	Right	5	Conservative	True aneurysm	Death from pulmonary artery thrombosis
12	Nishihara et al., 1993 <sup>[11]</sup>	34	Female	IVH, SAH	DSA	Idiopathic	Right	4	Clipping	True aneurysm	No deficit
13	Hamada et al., 1994 <sup>[12]</sup>	48	Female	IVH	DSA	Moyamoya	Left	-	Clipping of parent artery	-	Initial transient right hemiparesis, no deficit at discharge
14	Kawai et al., 1997 <sup>[13]</sup>	19	Male	IVH	DSA	Moyamoya	Right	-	Conservative	-	Persistent left-hand clumsiness
15	Yoneoka et al., 1998 <sup>[14]</sup>	69	Male	IVH	DSA	Idiopathic	Right	5	Clipping	True aneurysm	Bedridden
16	Yanaka et al., 2000 <sup>[15]</sup>	8	Female	IVH	DSA	AVM	Right	4	Excision	True aneurysm	No deficit
17	Lee et al., 2001 <sup>[16]</sup>	48	Male	ICH, IVH	DSA	Moyamoya	Right	-	Trapping and resection	True aneurysm	No deficit
18	Wong et al., 2003 <sup>[17]</sup>	62	Female	ICH, IVH	DSA	Moyamoya	Right	-	Clipping	-	Persistent left hemiparesis
19	Inci et al., 2007 <sup>[2]</sup>	19	Female	ICH, IVH	CTA	Idiopathic	Right	4	Trapping and resection	True aneurysm	No deficit

Contd...

Table 1: Contd...

Case	Author/year	Age	Gender	Presentations	Diagnosis	Etiology	Side	Size (mm)	Treatment	Histology	Outcome
20	-	37	Female	ICH, IVH, SAH	DSA	Idiopathic	Left	-	Aneurysm accidentally aspirated during open surgery	-	Death from diffuse vasospasm
21	Pavesi <i>et al.</i> , 2008 <sup>[18]</sup>	54	Female	IVH	DSA	Idiopathic	Left	-	Trapping and resection	True aneurysm	Glasgow Outcome Scale 4
22	Yurt <i>et al.</i> , 2009 <sup>[19]</sup>	70	Male	ICH, IVH	MRA	Idiopathic	Right	-	Clipping	-	No deficit
23	Kim <i>et al.</i> , 2009 <sup>[20]</sup>	43	Female	IVH	DSA	Moyamoya	Left	-	Endovascular embolization with nBCA/lipiodol	-	Partial recovery from initial neurological deficit
24	Choulakian <i>et al.</i> , 2010 <sup>[21]</sup>	35	Female	SAH, IVH	CTA	Moyamoya	Left	4.5	Endovascular embolization with nBCA/ethiodol	-	No deficit
25	Yang <i>et al.</i> , 2010 <sup>[22]</sup>	38	Female	IVH	DSA	Moyamoya	Left	5	Endovascular embolization with Glubran 2/lipiodol	-	No deficit
26	Lévêque <i>et al.</i> , 2011 <sup>[23]</sup>	50	Female	IVH	MRA	Moyamoya	Left	7	Endoscopic excision	True aneurysm	No deficit
27	Nishida <i>et al.</i> , 2011 <sup>[24]</sup>	84	Female	IVH	DSA	Atherosclerosis	Left	6	Endovascular embolization with platinum coils	-	Slight sensory aphasia from left parieto-occipital infarction, no new deficit
28	Dolati <i>et al.</i> , 2012 <sup>[1]</sup>	55	Male	IVH	DSA	PCA occlusion	Right	2.5	Endovascular embolization with glue	-	Persistent left hemiparesis
29	Yuan <i>et al.</i> , 2013 <sup>[25]</sup>	46	Male	IVH	CTA	Idiopathic	Left	3	Conservative	-	Death from rebleeding 9 months later
30	-	45	Female	IVH	CTA	Moyamoya	Right	4	Conservative	-	No deficit
31	Present case, 2016	59	Female	IVH	DSA	Idiopathic	Right	4	Clipping	True aneurysm	No deficit

ICH – Intracerebral hemorrhage; IVH – Intraventricular hemorrhage; SAH – Subarachnoid hemorrhage; AVM – Arteriovenous malformation; PCA – Posterior cerebral artery; nBCA – n-butyl cyanoacrylic acid; DSA – Diagnostic cerebral angiography; CTA – Computed tomography angiography; MRA – Magnetic resonance angiography

## Financial support and sponsorship

Nil.

## Conflicts of interest

There are no conflicts of interest.

## References

- Dolati P, Sutherland G, Wong J, Hudon M, Goyal M. Distal anterior choroidal artery aneurysm following iatrogenic posterior cerebral artery occlusion: A case report and review of literature. *Acta Neurochir (Wien)* 2012;154:53-7.
- Inci S, Arat A, Ozgen T. Distal anterior choroidal artery aneurysms. *Surg Neurol* 2007;67:46-52.
- Cressman MR, Hayes GJ. Traumatic aneurysm of the anterior choroidal artery. Case report. *J Neurosurg* 1966;24:102-4.
- Butler AB, Partain RA, Netsky MG. Primary intraventricular hemorrhage. A mild and remediable form. *Neurology* 1972;22:675-87.
- Papo I, Salvolini U, Caruselli G. Aneurysm of the anterior choroidal artery with intraventricular hematoma and hydrocephalus. Case report. *J Neurosurg* 1973;39:255-60.
- Takahashi M. Magnification angiography of cerebral aneurysms associated with Moyamoya disease. *AJNR* 1980;1:547-50.
- Tanaka Y, Takeuchi K, Akai K. Intracranial ruptured aneurysm accompanying Moyamoya phenomenon. *Acta Neurochir (Wien)* 1980;52:35-43.
- Konishi Y, Kadowaki C, Hara M, Takeuchi K. Aneurysms associated with Moyamoya disease. *Neurosurgery* 1985;16:484-91.
- Knuckey NW, Epstein MH, Haas R, Sparadeo F. Distal anterior choroidal artery aneurysm: Intraoperative localization and treatment. *Neurosurgery* 1988;22(6 Pt 1):1084-7.
- Inagawa T, Matsuda Y, Kamiya K, Aoyama H, Nagasako R, Yamamoto M. Saccular aneurysm of the distal anterior choroidal artery – Case report. *Neurol Med Chir (Tokyo)* 1990;30:498-502.
- Nishihara J, Kumon Y, Matsuo Y, Sakaki S. A case of distal anterior choroidal artery aneurysm: Case report and review of the literature. *Neurosurgery* 1993;32:834-7.
- Hamada J, Hashimoto N, Tsukahara T. Moyamoya disease with repeated intraventricular hemorrhage due to aneurysm rupture. Report of two cases. *J Neurosurg* 1994;80:328-31.
- Kawai K, Narita K, Nakayama H, Tamura A. Ventricular hemorrhage at an early stage of Moyamoya disease – Case report. *Neurol Med Chir (Tokyo)* 1997;37:184-7.
- Yoneoka Y, Ezuka I, Takai N, Oda T, Tamura T, Yamashita S. Ruptured distal anterior choroidal artery aneurysm presenting with casting intraventricular haemorrhage. *Acta Neurochir (Wien)* 1998;140:185-9.
- Yanaka K, Tsuboi K, Fujita K, Aoki K, Takeuchi S, Anno I, *et al.* Distal anterior choroidal artery aneurysm associated with an arteriovenous malformation. Intraoperative localization and treatment. *Surg Neurol* 2000;53:546-51.
- Lee JK, Lee JH, Kim SH, Lee MC. Distal anterior choroidal artery aneurysm in a patient with moyamoya disease: Case report. *Neurosurgery* 2001;48:222-5.
- Wong GK, Boet R, Poon WS. Ruptured distal anterior choroidal artery aneurysm presenting with right intracerebral haematoma: Clipping aided by subpial uncal resection. *J Clin Neurosci* 2003;10:689-91.
- Pavesi G, Amistà P, Munari M, Gardiman MP. Intraventricular hemorrhage caused by peripheral anterior choroidal artery aneurysm rupture. A case report. *Neuroradiol J* 2008;21:717-20.
- Yurt A, Turan Y, Uçar K, Camlar M, Oran I. Ruptured distal anterior choroidal artery aneurysm. *J Clin Neurosci* 2009;16:132-4.
- Kim SH, Kwon OK, Jung CK, Kang HS, Oh CW, Han MH, *et al.* Endovascular treatment of ruptured aneurysms or pseudoaneurysms on the collateral vessels in patients with Moyamoya disease. *Neurosurgery* 2009;65:1000-4.
- Choulakian A, Drazin D, Alexander MJ. NBCA embolization of a ruptured intraventricular distal anterior choroidal artery aneurysm in a patient with Moyamoya disease. *J Neurointerv Surg* 2010;2:368-70.
- Yang S, Yu JL, Wang HL, Wang B, Luo Q. Endovascular embolization of distal anterior choroidal artery aneurysms associated with Moyamoya disease. A report of two cases and a literature review. *Interv Neuroradiol* 2010;16:433-41.
- Lévêque M, McLaughlin N, Laroche M, Bojanowski MW. Endoscopic treatment of distal choroidal artery aneurysm. *J Neurosurg* 2011;114:116-9.
- Nishida A, Tokunaga K, Hishikawa T, Sugiu K, Date I. Endovascular coil embolization of a ruptured distal anterior choroidal artery aneurysm associated with ipsilateral middle cerebral artery occlusion – Case report. *Neurol Med Chir (Tokyo)* 2011;51:716-9.
- Yuan Z, Woha Z, Weiming X. Intraventricular aneurysms: Case reports and review of the literature. *Clin Neurol Neurosurg* 2013;115:57-64.
- Lee YS, Park J. Anterior choroidal artery aneurysm surgery: Ischemic complications and clinical outcomes revisited. *J Korean Neurosurg Soc* 2013;54:86-92.