

# Medullary Hemorrhage Caused by Foramen Magnum Dural Arteriovenous Fistula Successfully Obliterated using Combination of Endovascular and Surgical Treatments: A Case Report and Literature Review

## Abstract

The authors describe an extremely rare case of foramen magnum dural arteriovenous fistula (DAVF), Cognard type V, presented with medullary hemorrhage caused by venous varix on the lateral medullary draining vein embedded into the medulla oblongata. Following mild myelopathy for 3 days, a 20-year-old male developed dyspnea, generalized seizures, loss of consciousness, and finally cardiac arrest. After successful resuscitation, computed tomography scan (CT) of the brain was obtained and showed acute medullary hemorrhage. Subsequent magnetic resonance imaging of the brain revealed diffuse venous congestion or edema of the medulla with multiple dilated flow voids surrounding the medulla, more prominent on the left side, with venous varix embedded into the left-sided of the lower medulla. He was sent to the emergency department of the local hospital and intubated promptly. A few minutes later, the patient had a cardiac arrest. Digital subtraction angiography (DSA) demonstrated DAVF of the foramen magnum supplied mainly by dural branches of bilateral hypertrophic posterior inferior cerebellar arteries (PICAs), slightly by the posterior meningeal branch of the left vertebral artery, and the jugular branch of the left ascending pharyngeal artery (APA) originating from the occipital artery. Transarterial embolization through the bilateral dural branches of the PICAs was successfully performed using N-butyl-2-cyanoacrylate (NBCA), resulting in complete obliteration. The patient had excellent recovery and lost to annual follow-up. Seven years later, he had a recurrent of the fistula presented with occipital headache. DSA with angiographic CT in three-dimensional reconstruction and maximum intensity projection reformatted images clearly demonstrated the exact location of the DAVFs at the posterior rim of the foramen magnum, mainly recruited by the hypertrophic jugular branch of the APA originating from the occipital artery. The fistula was successfully treated surgically following transarterial embolization through the jugular branch of the APA using NBCA. Follow-up DSA confirmed complete obliteration of the DAVF. The patient has remained clinically asymptomatic 2 years after the operation.

**Keywords:** Brainstem congestion, dural arteriovenous fistula, foramen magnum, medullary hemorrhage, pial supply, venous varix

## Introduction

Intracranial dural arteriovenous fistulas (DAVFs) are abnormal arteriovenous connections located within the leaflets of the dura matter, commonly near the venous sinuses. Arterial supply usually arises from dural or meningeal arteries. Dural branches from the pial arteries are rare. Venous drainage may occur into the dural sinuses, dural, osteodural, and/or leptomeningeal veins.<sup>[1,2]</sup> Symptoms of the patients usually relate to the location of the fistulas and venous drainage patterns.<sup>[3]</sup> Based on the pattern of venous drainage by Cognard *et al.*,<sup>[4]</sup> intracranial DAVFs were classified

into five types, including Type I: Fistulas drain into the main sinus with antegrade flow; Type IIa: Retrograde flow into the sinus (es) only; Type IIb: Retrograde flow to cortical vein (s) only; Type III: Direct cortical venous drainage without venous ectasia; Type IV: direct cortical venous drainage with venous ectasia; and Type V: Into the spinal perimedullary veins. Patients harboring DAVFs manifest with intracranial hemorrhage at initial diagnosis in approximately 18%–24% of all intracranial DAVFs.<sup>[5,6]</sup> Foramen magnum DAVFs are rare and account for 1.5%–2.3% of all location of intracranial DAVFs.<sup>[4,6-8]</sup> DAVFs of this location usually occur in a middle-aged patient with a

**Prasert  
Iampreechakul,  
Anusak Liengudom,  
Punjama  
Lertbutsayanukul<sup>1</sup>,  
Yodkhwan  
Wattanasen<sup>1</sup>,  
Somkiet  
Siriwimonmas<sup>2</sup>**

*Departments of Neurosurgery and <sup>1</sup>Neuroradiology, Prasat Neurological Institute, <sup>2</sup>Department of Radiology, Bumrungrad International Hospital, Bangkok, Thailand*

**Address for correspondence:**  
Dr. Prasert Iampreechakul,  
312 Rachawithi Road,  
Khwaeng Thung Phaya Thai,  
Bangkok 10400, Thailand.  
E-mail: bangruad@hotmail.com

### Access this article online

**Website:** www.asianjns.org

**DOI:** 10.4103/ajns.AJNS\_259\_19

### Quick Response Code:



**How to cite this article:** Iampreechakul P, Liengudom A, Lertbutsayanukul P, Wattanasen Y, Siriwimonmas S. Medullary hemorrhage caused by foramen magnum dural arteriovenous fistula successfully obliterated using combination of endovascular and surgical treatments: A case report and literature review. *Asian J Neurosurg* 2019;14:1256-67.

This is an open access journal, and articles are distributed under the terms of the Creative Commons Attribution-NonCommercial-ShareAlike 4.0 License, which allows others to remix, tweak, and build upon the work non-commercially, as long as appropriate credit is given and the new creations are licensed under the identical terms.

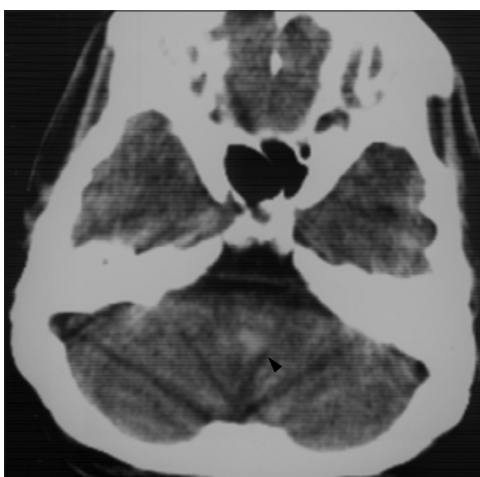**For reprints contact:** reprints@medknow.com

strong male predominance. They commonly manifest with progressive myelopathy and posterior fossa intracranial hemorrhage (i.e., subarachnoid hemorrhage [SAH]).<sup>[9]</sup>

We describe a patient with foramen magnum DAVF, Cognard type V, presenting with respiratory insufficiency following by seizures, unconsciousness, and developing of cardiac arrest caused by medullary hemorrhage from ruptured venous varix on the draining vein invaginated into the medulla oblongata. We also review the literature of patients having foramen magnum DAVFs.

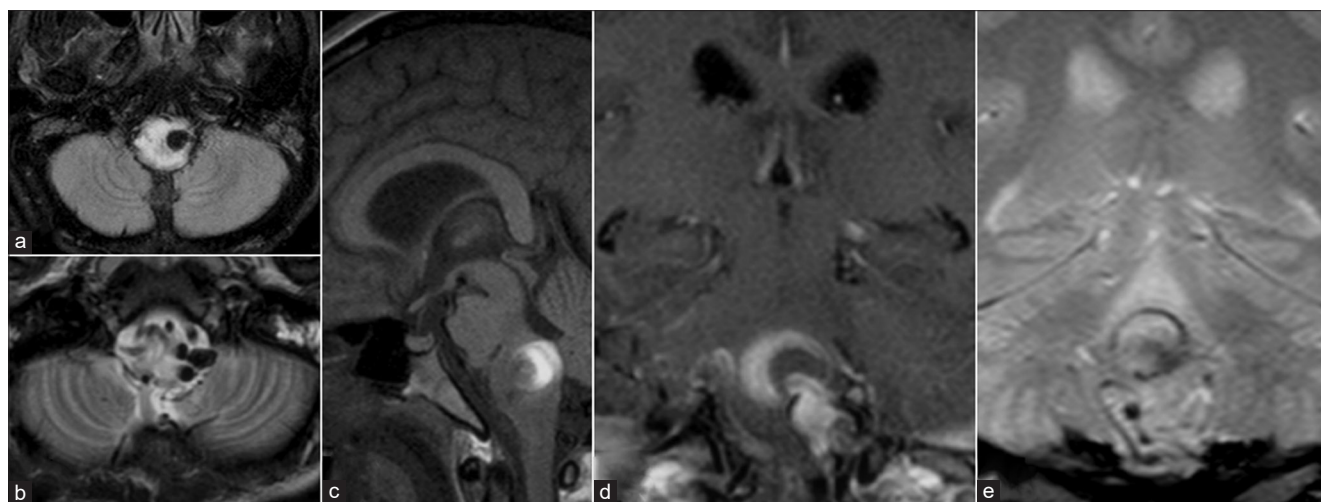
## Case Report

A 20-year-old smoker male experienced mild weakness and paresthesia of lower extremities for 3 days. There

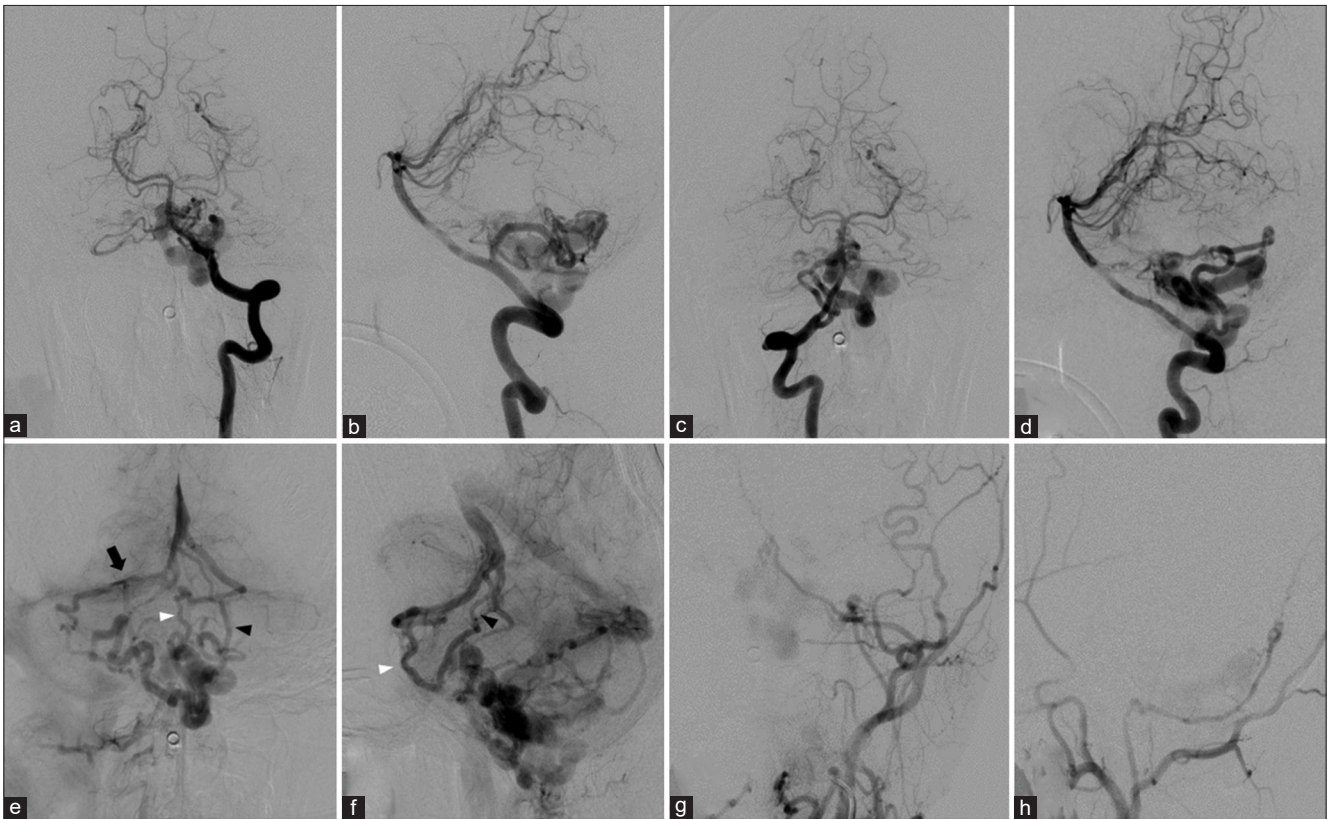


**Figure 1:** Computed tomography scan of the brain, obtained after initial aggressive symptoms, shows a hyperdense lesion in the dorsal region of the left-sided of the medulla oblongata (arrowhead), corresponding to acute medullary hemorrhage

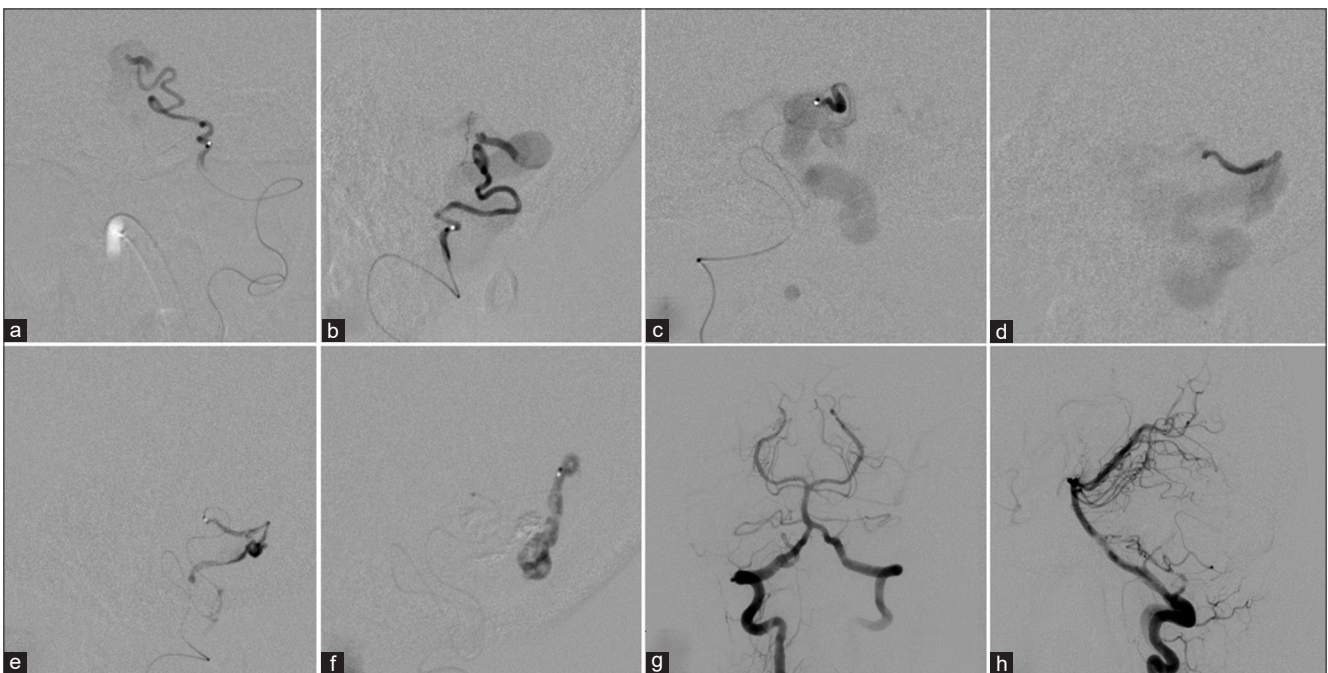
was no underlying diseases or history of trauma. He went to the clinic and took home some medicine. Three days later, the patient developed dyspnea, generalized seizures, and subsequent loss of consciousness. He was sent to the emergency department of the local hospital and intubated promptly. A few minutes later, the patient had a cardiac arrest. Immediate cardiopulmonary resuscitation was performed nine times until the presence of vital signs. Computed tomography (CT) scan of the brain was obtained and showed a hyperdense lesion in the dorsal region of the left-sided of the medulla oblongata, corresponding to medullary hemorrhage [Figure 1]. The patient was sent to the intensive care unit for close observation until clinical stable. Ten days later, the patient was sent to another larger local hospital. Following day, magnetic resonance imaging (MRI) of the brain revealed diffuse hyperintensity of the medulla oblongata on fluid-attenuated inversion recovery and T2-weighted sequences, corresponding to venous congestion or edema of the medulla. There were multiple dilated flow voids surrounding the medulla, more prominent on the left side, with venous varix embedded into the left-sided of the lower medulla. T1-weighted images demonstrate a round mixed iso and crescent hyperintense lesion in the dorsal region of the enlarged upper medulla, representing acute to subacute hematoma. The trajectory of hemorrhage projected superiorly from the left-sided of the lower medulla into the mid-dorsal region of the upper medulla [Figure 2]. Tracheostomy was performed due to prolonged intubation and recurrent pneumonia. The disabled patient gradually improved and could follow command in the next 2 weeks with quadriparesis status (power Grade 1–2/5). Two weeks later, the patient was transferred to Prasat Neurological Institute (PNI) for further investigation and proper



**Figure 2:** Magnetic resonance imaging of the brain obtained 11 days after initial aggressive symptoms. (a) Axial fluid-attenuated inversion recovery image shows diffuse edema of the medulla with a venous varix embedded into the left-sided of the medulla. (b) Axial T2-weighted image also reveals diffuse edema with prominent dilated flow-voids surrounding the lower medulla. (c) Sagittal T1-weighted image demonstrates a round mixed iso and crescent hyperintense lesion in the dorsal region of the enlarged upper medulla, representing acute to subacute hematoma. (d) Coronal gadolinium-enhanced T1-weighted image discloses the trajectory of hemorrhage from the left-sided of the lower medulla into the mid-dorsal region of the upper medulla. (e) Coronal T2\*-weighted gradient-echo (GRE) image shows thin hypointense rim of hemosiderin



**Figure 3:** Cerebral angiography of the brain obtained 1 month after initial symptoms. Anteroposterior (a and c) and lateral views (b and d) of bilateral vertebral arteries injections show dural arteriovenous fistulas of the foramen magnum mainly supplied by bilateral hypertrophic posterior inferior cerebellar arteries. The posterior meningeal branch of the left VA also feed the fistulas. Anteroposterior (e) and lateral (f) views of late venous phase of the right vertebral artery injection demonstrate deep venous drainage to both sides of the brainstem along cerebellomedullary and cerebellopontine cisterns. On the left side, the left basal vein of Rosenthal receives venous blood from the anterior pontomesencephalic vein (white arrowhead) and the left lateral mesencephalic vein (black arrowhead) with subsequent drainage into the great vein of Galen. On the right side, the right dilated superior hemispheric vein connects from the dilated right transverse pontine vein with further drainage into the right proximal transverse sinus via the tentorial vein (black arrow). In addition, anteroposterior (g) and lateral (h) views of the left external carotid artery injection reveal the minimal supply from the neuromeningeal trunk of the left ascending pharyngeal artery originating from the occipital artery



**Figure 4:** Anteroposterior (a and c) and lateral (b and d) views of superselective catheterization of bilateral posterior inferior cerebellar arteries injections clearly reveal dural branches of both posterior inferior cerebellar arteries supplying the fistulas. During embolization with two injections via the right posterior inferior cerebellar artery, lateral views (e and f) demonstrate glue cast penetrating into the proximal draining vein. Postembolization, anteroposterior (g) and lateral (h) views of the right vertebral artery confirm complete obliteration of the fistulas

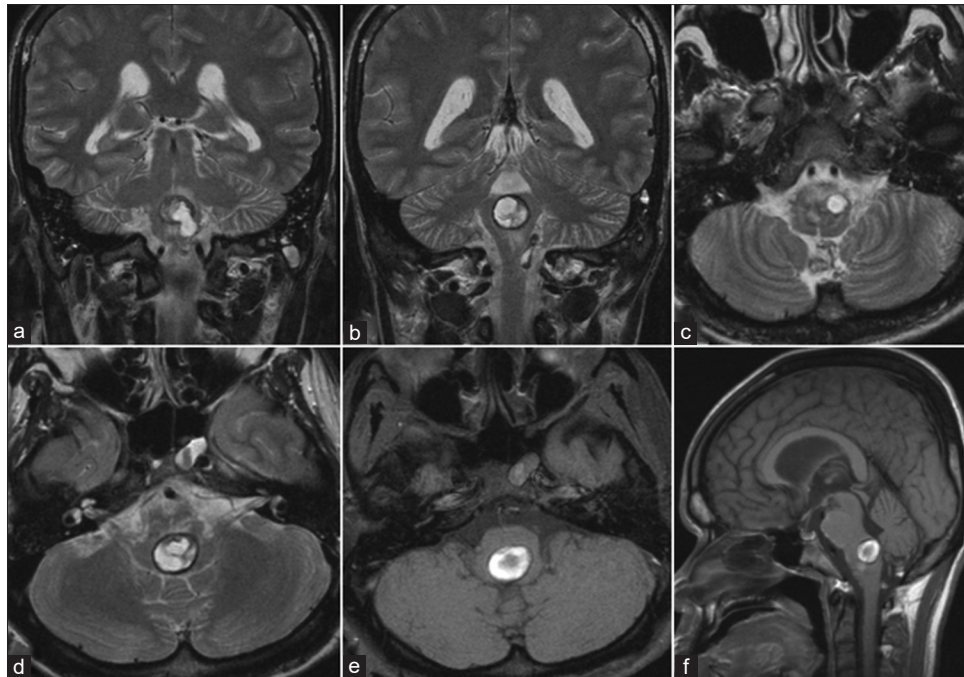


Figure 5: Magnetic resonance imaging of the brain obtained 1 week after endovascular treatment. Coronal (a and b), axial (c and d) T2-weighted, axial (e), and sagittal (f) T1-weighted magnetic resonance imaging reveal a large round mixed central isointense and peripheral hypointense mass with hyperintensity in a venous aneurysm, probably representing a thrombosed venous aneurysm with resolving hematoma. There was disappearance of previously seen venous congestion of the medulla and multiple dilated flow-voids surrounding the medulla

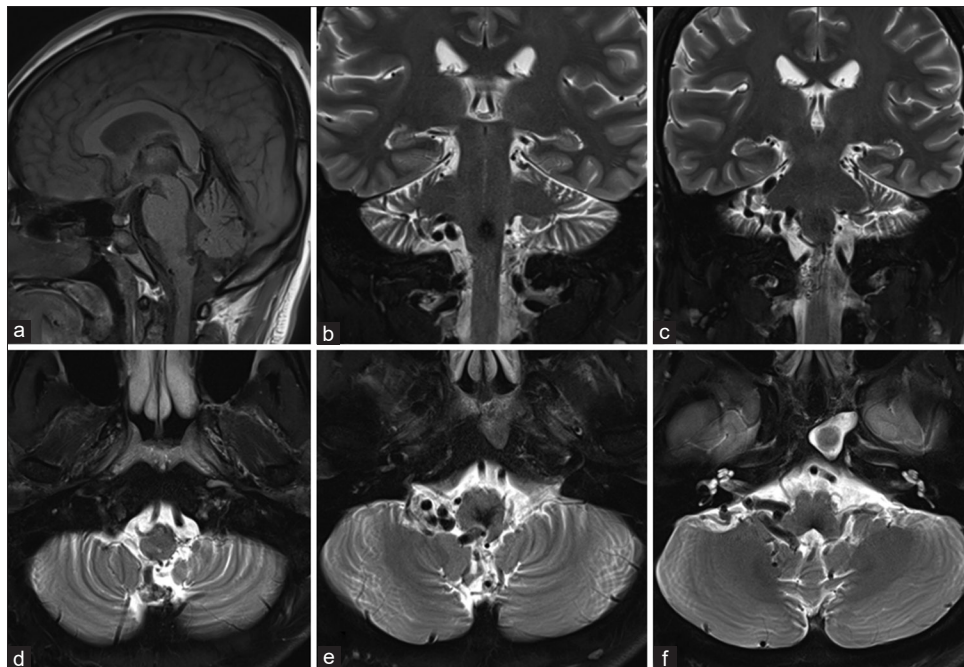
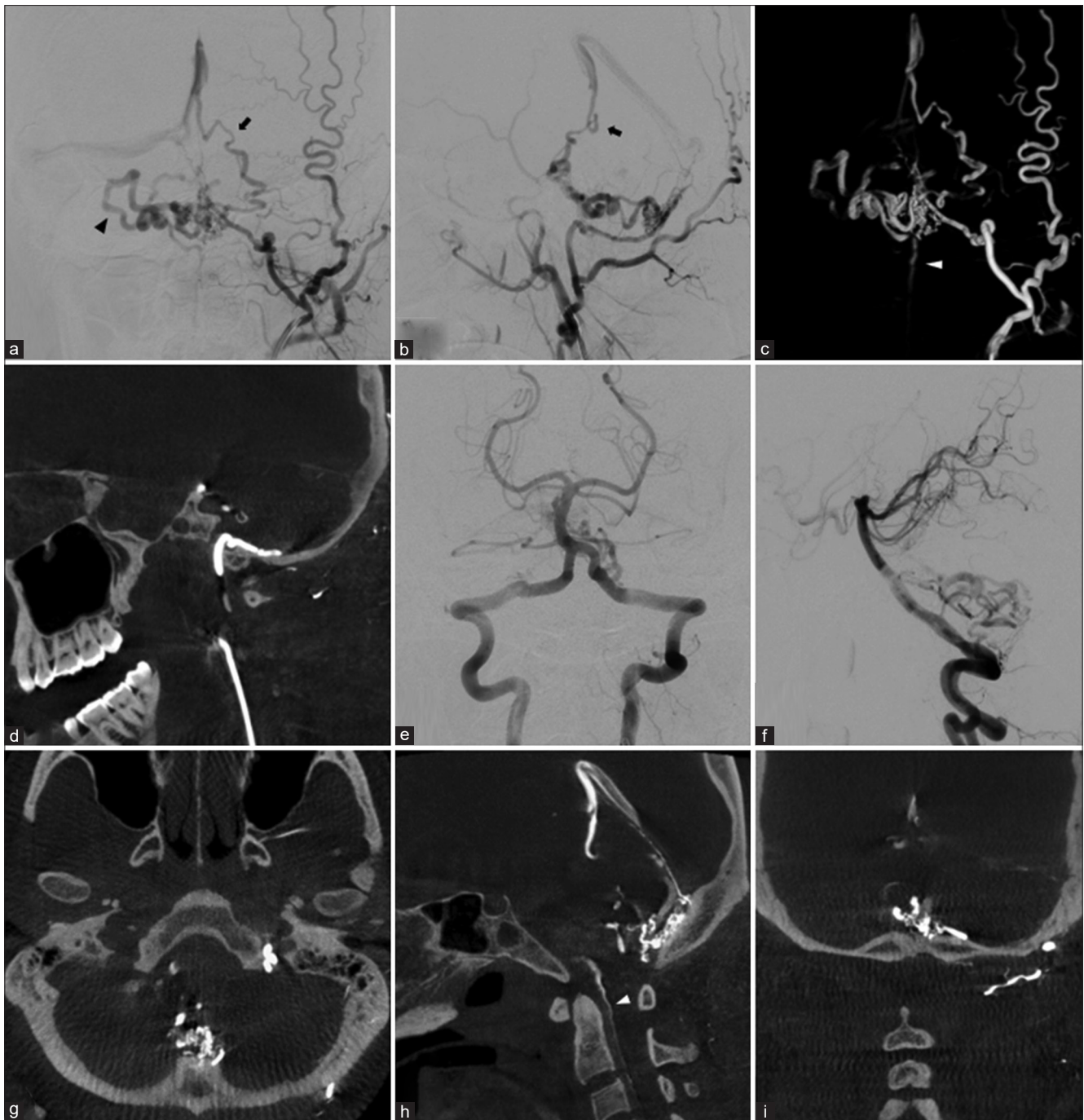


Figure 6: Magnetic resonance imaging (MRI) of the brain obtained 7 years after endovascular treatment and the patient presented with occipital headache. Sagittal T1-weighted (a), sequential coronal (b and c), and axial (d, e, and f) T2 weighted MRI demonstrate multiple dilated flow-voids, more prominent on the right side, along both cerebellomedullary and cerebellopontine cisterns, representing recurrent dural arteriovenous fistulas of the foramen magnum. There is disappearance of a previously seen thrombosed venous aneurysm and complete resolution of the hematoma in the medulla with small residual hypointense area of hemosiderin stain in the dorsal region of the medulla

management. The neurological examination revealed fully consciousness, evidence of spastic quadriparesis (power grade 2–3/5), hyperreflexia of upper and lower extremities, and the presence of Babinski’s sign. Digital subtraction

angiography (DSA) demonstrated DAVF of the foramen magnum supplied mainly by dural branches of bilateral hypertrophic posterior inferior cerebellar arteries (PICAs), slightly by the posterior meningeal branch of the left

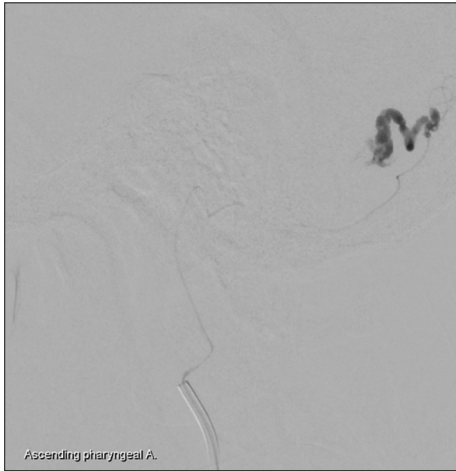

**Figure 7:** Cerebral angiography obtained 7 years after endovascular treatment. Anteroposterior (a), lateral (b) views, and anteroposterior 3-dimensional reconstructed image (c) of the left external carotid artery injection demonstrate recurrent dural arteriovenous fistulas of the foramen magnum mainly supplied by the hypertrophic neuromeningeal trunk of the ascending pharyngeal artery (APA) originating from the occipital artery. The fistulas drain to both sides of the brainstem along cerebellomedullary and cerebellopontine cisterns. On the left side, the fistulas drain superiorly into the great vein of Galen via the left dilated vein of cerebellomesencephalic fissure (black arrow). On the right side, dilated superior hemispheric vein connects from the dilated petrosal vein. Inferiorly, it also drains into anterior medullary vein connecting to anterior spinal vein (white arrowhead). (d) Sagittal maximum intensity projection (MIP) reformatted image of angiographic computerized tomography (CT) of the craniocervical junction clearly shows the APA running along the floor of posterior fossa through the jugular foramen. Anteroposterior (e) and lateral (f) views of the left vertebral artery injection demonstrate the fistulas fed partially by the left posterior inferior cerebellar artery and posterior meningeal branch of the left vertebral artery. Axial (g), sagittal (h), and coronal (i) MIP reformatted images of angiographic CT of the craniocervical junction clearly demonstrated the exact location of the fistulas at the posterior rim of the foramen magnum and the anterior spinal vein (white arrowhead)

vertebral artery (VA), and the neuromeningeal trunk of the left ascending pharyngeal artery (APA) originating from the occipital artery. The venous drainage was split in two

directions via the dilated lateral medullary veins and run superiorly along cerebellomedullary and cerebellopontine cisterns into both petrosal veins. On the left side, the

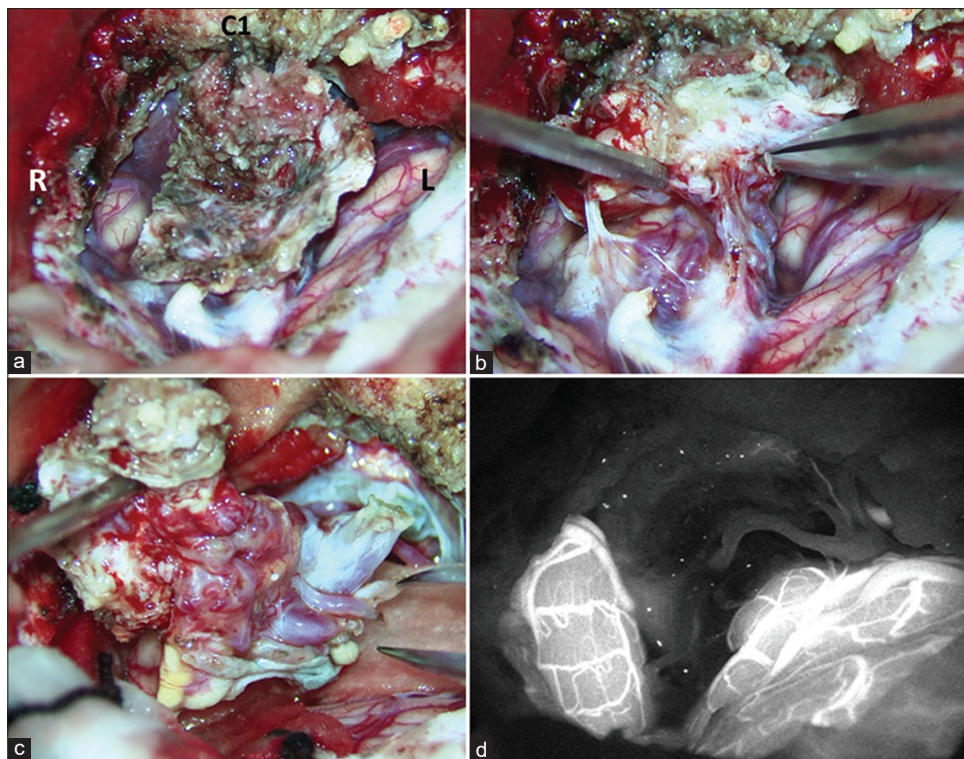
left basal vein of Rosenthal receives venous blood from the anterior pontomesencephalic vein and the left lateral mesencephalic vein with subsequent drainage into the great vein of Galen. On another side, the right dilated superior hemispheric vein connects from the dilated right transverse pontine vein with further drainage into the right proximal transverse sinus through the tentorial sinus [Figure 3]. Transarterial embolization through the bilateral dural branches of the PICAs was successfully performed using N-butyl-2-cyanoacrylate (NBCA). Postembolization



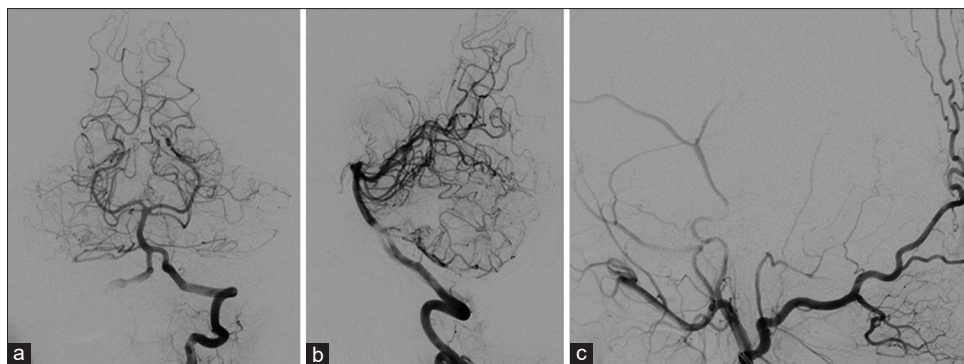
**Figure 8:** During embolization through the left ascending pharyngeal artery, the glue penetrates into the proximal draining vein

angiography confirmed complete obliteration of the fistulas [Figure 4]. MRI of the brain obtained 1 week after endovascular treatment revealed a large round mixed central isointense and peripheral hypointense mass with hyperintensity in a venous aneurysm, probably representing a thrombosed venous aneurysm with resolving hematoma. There was the disappearance of previously seen venous congestion of the medulla and multiple dilated flow-voids surrounding the medulla [Figure 5]. The patient gradually improved, and tracheostomy tube was removed before discharging home 2 weeks after treatment. Six months after endovascular treatment, the patient showed no residual neurological deficits. Routine annual follow-up was scheduled for him, but the patient was lost to follow-up without any reasons.

Seven years later, the patient experienced occipital headache without the stiffness of the neck for 7 days. He went to the local hospital and was sent back to PNI again due to the previous history of DAVFs of the foramen magnum. There were no neurological deficits on neurological examination. Follow-up MRI of the brain showed multiple dilated flow-voids, more prominent on the right side, along both cerebellomedullary and cerebellopontine cisterns, representing recurrent DAVFs of the foramen magnum. There was the disappearance of a previously seen thrombosed venous aneurysm and complete resolution of the hematoma in the medulla with the small residual



**Figure 9:** During s suboccipital craniotomy without C1 laminectomy on prone position. Intraoperative views show a flap of the removed dural leaflets (a), connecting of arterialized veins and the dural leaflets after flipping a flap (b), and the dural leaflets after complete disconnection (c). (d) Indocyanine green fluorescence image confirmed complete removal of the dural arteriovenous fistula



**Figure 10:** Follow-up cerebral angiography obtained 1 month after surgery. Anteroposterior (a), lateral (b) views of the left vertebral artery, and lateral view of the left external carotid artery (c) injections confirm complete obliteration of the fistula

hypointense area of hemosiderin stain in the dorsal region of the medulla [Figure 6]. DSA with angiographic CT in three-dimensional reconstruction and maximum intensity projection (MIP) reformatted images of the craniocervical junction clearly demonstrated the exact location of the DAVFs at the posterior rim of the foramen magnum, mainly supplied by the hypertrophic jugular branch of the APA originating from the occipital artery. Without supplying from the right PICA, the left PICA and posterior meningeal branch of the left VA partially fed the fistulas. The venous drainage drained to both sides of the medulla and run superiorly along cerebellomedullary and cerebellopontine cisterns into both petrosal veins. On the left side, the fistulas drain superiorly into the great vein of Galen through the left dilated vein of cerebellomesencephalic fissure. On the right side, the fistulas still drained into the right proximal transverse sinus through the dilated superior hemispheric vein and tentorial sinus, respectively. Inferiorly, it also drains into anterior medullary vein connecting to anterior spinal vein [Figure 7]. Endovascular treatment was performed through the jugular branch of the left APA using NBCA [Figure 8]. DSA after embolization revealed residual fistulas. Due to incomplete obliteration of the fistulas, the patient then was informed about surgical option and accepted this option.

Following suboccipital craniotomy without C1 laminectomy, resecting the dural leaflets and disconnecting leptomeningeal medullary draining veins were successfully performed using indocyanine green fluorescence imaging during operation [Figure 9]. In addition, watertight duraplasty was done with synthetic dural graft. The postoperative course was uneventful. Follow-up DSA, obtained 1 month after surgery, confirmed complete obliteration of the fistula [Figure 10]. The patient has remained clinically asymptomatic 2 years after the operation.

## Discussion

The common etiologies of the medullary hemorrhages are cavernous malformation or hemorrhagic transformation following infarction.<sup>[10]</sup> To the best of our knowledge,

there was only one previously reported case of medullary hemorrhage caused by DAVF at the craniocervical junction, supplied by the meningeal branch of the VA with draining superiorly into the anterior medullary vein in elderly woman.<sup>[11]</sup> She was complicated by acute neurogenic pulmonary edema, resulting in acute respiratory distress syndrome. In the present study, our case was the first case report of foramen magnum DAVF presented with acute medullary hemorrhage, leading to respiratory dysfunction, subsequent seizure, and finally developing cardiac arrest.

Involuntary convulsive-like movements, for example, jerky, tonic-clonic, intermittent shaking, or decerebrate postures, may occur in patients with brainstem stroke.<sup>[12]</sup> Without electroencephalography, we could not conclude that our case had real seizures. However, foramen magnum DAVF may present with epilepsy due to venous drainage superiorly to the temporal lobe, leading to temporal venous congestion.<sup>[13]</sup>

According to Cognard classification,<sup>[4]</sup> a foramen magnum DAVF with perimedullary and spinal venous drainage in our case is classified as Type V. The patients with Cognard type V intracranial DAVFs may experience bulbar palsy, and/or respiratory failure due to medullary venous congestion.<sup>[14]</sup> Without descriptions in details, Cognard *et al.*<sup>[4]</sup> disclosed that all three cases of foramen magnum DAVFs, classified as Cognard type IV and V, presented with hemorrhages. Based on the study of the relation between clinical presentation and venous drainage of intracranial DAVFs with spinal venous drainage by Brunereau *et al.*,<sup>[15]</sup> they found that the patients presenting with hemorrhage had venous drainage limited to the cervical cord, whereas those with myelopathy had extensive spinal venous drainage descending toward the conus medullaris.

The common types of hemorrhage in intracranial DAVFs are SAH and intracerebral hemorrhage.<sup>[3,16]</sup> Brainstem hemorrhage is extremely rare. Nakajima *et al.*<sup>[17]</sup> reported an elderly man with DAVFs of the sinus of the lesser sphenoid wing presented with pontine hemorrhage

**Table 1: Literature review of foramen magnum dural arteriovenous fistulas**

Authors	Gender/age	Symptoms and signs/images findings	Arterial supply	Location of draining veins	Associating venous varix	Treatment	Neurological outcome
Willinsky <i>et al.</i> , 1990 <sup>[20]</sup>	Male/57	Progressive myelopathy, BBD	APA, VA	PF, SC	No	Decompressive thoracic laminectomy Embolization with NBCA	Slight clinical improvement
Rodesch <i>et al.</i> , 1991 <sup>[21]</sup>	Male/50 Male/37	Tinnitus, right sixth nerve palsy SAH, IVH	APA, OA APA	CS, TL PF, Me	No Yes	Embolization with PVA Embolization with NBCA	Symptoms resolved GR
Pierot <i>et al.</i> , 1992 <sup>[6]</sup>	Male/56	SAH	APA, VA	PF	Yes	Embolization with particles	Death
Mascalchi <i>et al.</i> , 1996 <sup>[22]</sup>	Male/69 Male/53	Progressive myelopathy, BBD Progressive myelopathy	APA, VA APA	SC SC	No No	Surgery Embolization with NBCA	N/A N/A
McDougall <i>et al.</i> , 1997 <sup>[23]</sup>	Male/40	Headache, ataxia, loss of consciousness (cerebellar hemorrhage)	APA, VA	PF	Yes	Blood clot removal	N/A
Kai <i>et al.</i> , 1998 <sup>[24]</sup>	Male/55	Repeated SAH, IVH	APA, OA, VA	PF, Me	Yes	Embolization with liquid adhesive Embolization with liquid coils and EVAL	GR
Hurst <i>et al.</i> , 1999 <sup>[25]</sup>	Male/50	Acute neck pain, dysphagia, progressive myelopathy, respiratory failure	APA	Me, SC	Yes	Embolization with particles	IR
Wiesmann <i>et al.</i> , 2000 <sup>[26]</sup>	Male/46	SAH, progressive myelopathy, respiratory insufficiency	APA	P, Me, SC	No	Embolization with Histaeryl	GR
Reinges <i>et al.</i> , 2001 <sup>[27]</sup>	Male/48	Progressive myelopathy, BBD, respiratory insufficiency	VA	Me, SC	No	Surgery	GR
Kim <i>et al.</i> , 2003 <sup>[28]</sup>	Male/36	Headache, N/V (vermian hemorrhage, IVH)	APA **, VA	PF	Yes	Embolization with NBCA	GR
Lee <i>et al.</i> , 2010 <sup>[29]</sup>	Male/59	Progressive myelopathy, BBD	APA	SC	No	Embolization with NBCA	PR (delay in diagnosis)
Guo <i>et al.</i> , 2010 <sup>[30]</sup>	Male/47	SAH	VA	Me	Yes	Surgery	GR
	Male/35	SAH	VA	Me	No	Surgery	GR
	Male/51	SAH	APA, OA	PF, Me, SC	No	Surgery	GR
	Male/40	SAH	APA **, OA	PF, SC	Yes	No treatment due to financial reasons	N/A
Spiotha <i>et al.</i> , 2011 <sup>[31]</sup>	Male/49	Progressive myelopathy	APA	SC	No	Balloon-augmented Onyx embolization	Marked improvement during 3 months follow-up
Guo and Qiu 2012 <sup>[32]</sup>	Male/45	SAH	VA	PF, Me	Yes	Embolization with Onyx	N/A
Gandhi <i>et al.</i> , 2012 <sup>[3]</sup>	Male/58	SAH	VA	PF	Yes	Embolization	GR
Liang <i>et al.</i> , 2013 <sup>[33]</sup>	Female/49	Progressive myelopathy	APA, OA, VA	SC	No	Surgery Balloon-augmented Onyx embolization	GR
Hiramatsu <i>et al.</i> , 2015 <sup>[34]</sup>	Male/53	A floating sensation	APA, OA	PF, SC	Yes	Transarterial coil embolization for flow reduction	GR
Pop <i>et al.</i> , 2015 <sup>[13]</sup>	Male/38	Epilepsy, progressive myelopathy	APA, OA, VA	TL	No	Surgery Embolization with Onyx	Right hemiparesis (power grade 4/5)



Table 1: Contd...

Authors	Gender/ age	Symptoms and signs/images findings	Arterial supply	Location of draining veins	Associating venous varix	Treatment	Neurological outcome
Motebejane and Choi 2018 <sup>[9]</sup>	Male/57	Progressive myelopathy	APA, VA	SC	Yes	Embolization with NBCA with balloon blocked in the VA	GR
Kim et al., 2018 <sup>[35]</sup>	Male/51	SAH	APA*	PF	Yes	Embolization with NBCA	N/A
Present study, 2019	Male/48	SAH	APA	PF	Yes	Embolization with Onyx	GR
	Male/20	Myelopathy, respiratory insufficiency, seizure, loss of consciousness, cardiac arrest (Medullary hemorrhage)	APA*, PICA	PF, Me, SC	Yes	Multiple embolization with NBCA Surgery	GR

\*Neuromeningeal trunk originating from the occipital artery; \*\*Probable neuromeningeal trunk originating from the occipital artery. APA - Ascending pharyngeal artery; BBD - Bowel and bladder dysfunction; CS - Cavernous sinus; EVAL - Ethylene vinyl alcohol copolymer; F-Female; GR-Good recovery; IR-Incomplete recovery; IVH - Intraventricular hemorrhage; L-Left; M - Male; Me - Medulla oblongata; N/A - Data not available; NBCA - N-butyl-2-cyanoacrylate; N/V - Nausea and vomiting; OA - Occipital artery; P - Pons; PF- Posterior fossa; PICA- Posterior inferior cerebellar artery; PR - Poor result; PVA - Polyvinyl alcohol particles; R - Right; SAH - Subarachnoid hemorrhage; SC - Spinal cord; TL - Temporal lobe; VA - Vertebral artery

caused by venous varix on lateral mesencephalic vein invaginated into the pons. Another case report by Lasjaunias et al.,<sup>[1]</sup> they demonstrated small midbrain hemorrhage probably caused by ruptured perimesencephalic draining vein from a foramen magnum DAVF in middle-aged man.

The presence of retrograde cortical venous drainage or leptomeningeal venous drainage in DAVFs is the most imperative risk factor of intracranial DAVFs associated with hemorrhage.<sup>[6,18,19]</sup> In multivariate logistic regression analysis by Singh et al.,<sup>[5]</sup> male gender, age older than 50, and posterior fossa location were also found to be independently associated with hemorrhagic manifestation. In addition, smoking was more common in the hemorrhagic group. In our case, there were many risk factors, including retrograde leptomeningeal venous drainage, male gender, posterior fossa location, and history of smoking, except young age.

We reviewed the published case reports which have sufficient clinical description and clearly demonstrated figures of foramen magnum DAVFs.<sup>[3,9,13,16,20-35]</sup> The collected data in this review include demographic data (i.e., gender and age of patient), presenting symptoms, the findings of image studies, arterial feeders of the fistula, location of the draining veins, the presence of venous varix, treatment of the fistula, and neurological outcomes following treatment [Table 1]. From the literature review, there were 27 cases, including our case, with 27 foramen magnum DAVFs. All patients except one were male (96.3%) with a median age 49, range 20–69 years. Of 27 cases, 15 (55.6%) were hemorrhagic presentation, including SAH, intraventricular hemorrhage, cerebellar hemorrhage, and medullary hemorrhage (our case). The most common type of hemorrhage was SAH (80%). Another 12 cases were non-hemorrhagic presentation, including progressive myelopathy, epilepsy, tinnitus, floating sensation. The median age in hemorrhagic group was 46 (range 20–58 years), whereas nonhemorrhagic group was 51.5 (range 38–69 years). Only 2 cases, including our case, presented with myelopathy and hemorrhage. Most patients with hemorrhagic manifestation had a venous varix being the source of hemorrhage. The arterial supply included APA, VA, OA, and/or PICA. Twenty-two foramen magnum DAVFs (81.5%) supplied by the branch of APA, including hypoglossal and/or jugular branches. Four cases had blood supply only from VA. Only our case had additional supply from PICA. All patients with progressive myelopathy had venous drainage into the spinal cord, i.e., Cognard Type V. Four cases, including our cases, had respiratory insufficiency resulting from venous drainage to the medulla, leading to medullary congestion. Eighteen fistulas were treated with endovascular treatment alone, five with surgery alone, three with surgery following embolization, and one left

untreated. Most embolic material used for treatment was liquid embolic material, including glue and Onyx. Most patients had good neurological outcome after treatment.

Retrograde leptomeningeal venous drainage, aneurysmal venous dilatation, and galenic drainage are factors predisposing to aggressive neurological presentation, i.e., intracranial hemorrhage or progressive neurological deficit.<sup>[2]</sup> Undoubtedly, leptomeningeal draining pathway with venous varix embedded into the medulla is the source of hemorrhage, leading to catastrophic neurological behavior in our case. Furthermore, we previously reviewed a rare condition of patients suffering from intramedullary hemorrhage caused by spinal DAVFs.<sup>[36]</sup> In most of the cases, venous varices on draining veins were the source of intramedullary hemorrhage. Similar to our case, Kai *et al.*<sup>[24]</sup> demonstrated a false aneurysm protruding into the medulla. However, this case presented with SAH. In addition, Motebejane and Choi<sup>[9]</sup> revealed that all patients harboring foramen magnum DAVFs with SAH in their series had intracranial venous drainage with venous aneurysms. Based on our review, hemorrhage in foramen magnum DAVFs usually resulted from ruptured venous varix.

Foramen magnum DAVFs can be treated by endovascular treatment, surgery, or both depend on institutions preference.<sup>[9,16,27,30]</sup> However, best management decisions should be approached by a multidisciplinary team.<sup>[3]</sup> DAVFs in the region of the foramen magnum tend to have leptomeningeal venous reflux and a high risk for intracranial hemorrhage. Therefore, aggressive treatment should be achieved.<sup>[24]</sup> The goal of treatment is to obtain the anatomical cure.<sup>[16]</sup>

Interestingly, the foramen magnum DAVF in our case mainly supplied by bilateral PICAs, i.e., pial arteries. Only 5% of all intracranial DAVFs supplied by both meningeal and pial arteries.<sup>[4]</sup> DAVFs fed by the pial arteries are associated with a higher risk of stroke or major complications either during endovascular or surgical treatment.<sup>[37]</sup> Osada and Krings<sup>[38]</sup> investigated the characteristics of pial arterial supplies in intracranial DAVFs and classified them into dilated pre-existing dural branches of pial arteries and a pure pial supply. Younger age, DAVFs within tentorium, and the presence of venous dilatation (i.e., a sign of venous hypertension) were independent predictors of a pial arterial supply. In their series, they also reported dilated dural branch of pial arteries from PICA in DVAFs of tentorium, torcular herophili, and foramen magnum DAVFs. Recognition of additional pial supply is imperative for avoiding inadvertent complication related to the reflux of liquid embolic materials into pial vessels supplying normal brain tissue. Dural vessels arising from PICA are the posterior meningeal artery and the artery of the falx cerebelli.<sup>[39]</sup> Onyx embolization in DAVFs through pial arterial supply could increase the risk of procedure-related complications, i.e., periprocedure hemorrhage.<sup>[40]</sup> In our

case, the posterior meningeal arteries from PICAs pierced the dura at the posterior rim of the foramen magnum. Fortunately, the fistula was successfully treated using NBCA via these branches without any complications.

Medullary congestion can be either due to intracranial DAVFs with caudally drainage into the anterior spinal vein through the medullary or cervical DAVFs with rostrally drainage into medullary veins.<sup>[4,41]</sup> According to a systemic review by El Asri *et al.*,<sup>[42]</sup> the poor outcomes were correlated to the presence of brainstem signal abnormalities on MRI. Unlike primary intracerebral hemorrhage, the patient suffering from extensive hemorrhagic venous infarction even caused by high-flow AVF may dramatically recover following prompt endovascular treatment.<sup>[43]</sup> In our case, the patient had regained full motor strength without residual neurological deficits after marked reduction of the flow of the fistula by transarterial embolization using NBCA through pial supply of bilateral PICAs.

Incomplete embolization, using non-permanent embolic, or partial surgical of the fistula may result in recurrent fistula, probably leading to fatal rebleeding.<sup>[16]</sup> Even though using transarterial embolization with Onyx, the recurrence of the fistula can occur.<sup>[13]</sup> Therefore, long-term follow-up with radiographical images is mandatory to early detect the recurrent fistula. Recanalization of embolized vessels occurred in our case several years later with the manifestation of occipital headache. The fistula also recruited other feeding artery, i.e., the APA.

Motebejane and Choi<sup>[9]</sup> demonstrated that all foramen magnum DAVFs in their series were supplied by the hypoglossal and/or jugular branches of the APA, commonly by hypoglossal branch. The APA may arise from the proximal occipital artery.<sup>[44]</sup> With angiographic CT in three-dimensional reconstruction and MIP reformatted images, in our case clearly demonstrated the jugular branch of the APA originating from the occipital artery. Given delay in treatment and probable subsequent poor outcomes, DAVFs at the foramen magnum may not be identified using standard 4 vessels cerebral angiography.<sup>[20,21,24]</sup> Due to common feeder by the neuromeningeal trunk of the APA, selective ascending pharyngeal angiography should be performed. Endovascular treatment through this artery may carry the risks of inadvertent embolization due to potential risk of liquid embolic materials leakage through extracranial-intracranial anastomoses or injury to vasa nervosum of cranial nerves.<sup>[3]</sup> To prevent major reflux into the main trunk, the tip of the microcatheter should be navigated close enough to the fistula.<sup>[35]</sup> In addition, balloon-augmented liquid embolic material embolization through neuromeningeal trunk of APA was used to prevent the risks of injury to the lower cranial nerves.<sup>[9,31,33]</sup> Transarterial embolization alone is likely to be ineffective due to the extensive collateral network and high vascularity of the dura.<sup>[24]</sup> Predictably, there was residual fistula

following transarterial embolization through the APA using NBCA in our case.

MRI and cerebral angiography may not depict the exact location of the fistulas at the skull base.<sup>[21]</sup> We agree with Pop *et al.*<sup>[13]</sup> that rotational angiographic CT is useful in delineating the complex anatomy of the foramen magnum DAVFs. In our case, angiographic CT in three-dimensional reconstructed image and MIP reformatted images can identify the exact location of fistula at the posterior border of the foramen magnum and complex venous drainages.

According to the literature review in Cognard type V intracranial DAVFs by El Asri *et al.*,<sup>[42]</sup> the surgical treatment appears to be more effective than endovascular treatment. Microsurgical treatment of foramen magnum DAVFs probably is an effective and more reliable method of treatment.<sup>[27]</sup> Many surgeons preferred suboccipital approach with partial or hemilaminectomy for foramen magnum DAVFs.<sup>[3,27,30,34]</sup> In our case, suboccipital approach without laminectomy of C1 was enough for resecting the dural leaflets and disconnecting leptomeningeal veins due to knowing the exact location of the fistula from angiographic CT.

## Conclusion

We illustrated an extremely rare case of foramen magnum DAVF, Cognard type V, presented with catastrophic neurological behavior, caused by ruptured venous varix, leading to medullary hemorrhage. The patient had a complete recovery after endovascular treatment via bilateral PICAs with complete obliteration of the fistula. Seven years later, he had a recurrent DAVF presented with occipital headache. The fistula recruited mainly blood supply from the jugular branch of the APA originating from the occipital artery. Finally, we could achieve a cure of the DAVF by surgical removal of the dural leaflets and disconnection of the fistula following endovascular treatment via the APA with excellent outcome. Understanding the angioarchitecture of foramen magnum DAVFs, including arterial feeders, venous drainage pattern, associated venous pouch, and localization of the fistulous zone, is the key to successful management. In addition, the exact location of DAVFs may influence the surgical approach.

## Consent

The patient has given consent to be enrolled and has her data published.

## Declaration of patient consent

The authors certify that they have obtained all appropriate patient consent forms. In the form, the patient has given her consent for her images and other clinical information to be reported in the journal. The patient understands that name and initials will not be published, and due efforts will be made to conceal identity, but anonymity cannot be guaranteed.

## Financial support and sponsorship

Nil.

## Conflicts of interest

There are no conflicts of interest.

## References

1. Lasjaunias P, Berenstein A, Ter Brugge KG. Surgical Neuroangiography. Vol. 2. New York: Springer-Verlag; 2004.
2. Awad IA, Little JR, Akarawi WP, Ahl J. Intracranial dural arteriovenous malformations: Factors predisposing to an aggressive neurological course. *J Neurosurg* 1990;72:839-50.
3. Gandhi D, Chen J, Pearl M, Huang J, Gemmete JJ, Kathuria S. Intracranial dural arteriovenous fistulas: Classification, imaging findings, and treatment. *AJNR Am J Neuroradiol* 2012;33:1007-13.
4. Cognard C, Gobin YP, Pierot L, Bailly AL, Houdart E, Casasco A, *et al.* Cerebral dural arteriovenous fistulas: Clinical and angiographic correlation with a revised classification of venous drainage. *Radiology* 1995;194:671-80.
5. Singh V, Smith WS, Lawton MT, Halbach VV, Young WL. Risk factors for hemorrhagic presentation in patients with dural arteriovenous fistulae. *Neurosurgery* 2008;62:628-35.
6. Li C, Wang Y, Li Y, Jiang C, Yang X, Wu Z. Clinical and angioarchitectural risk factors associated with intracranial hemorrhage in dural arteriovenous fistulas: A single-center retrospective study. *PLoS One* 2015;10:e0131235.
7. Baltasavias G, Valavanis A. Endovascular treatment of 170 consecutive cranial dural arteriovenous fistulae: Results and complications. *Neurosurg Rev* 2014;37:63-71.
8. Piippo A, Laakso A, Seppä K, Rinne J, Jääskeläinen JE, Hernesniemi J, *et al.* Early and long-term excess mortality in 227 patients with intracranial dural arteriovenous fistulas. *J Neurosurg* 2013;119:164-71.
9. Motebejjane MS, Choi IS. Foramen magnum dural arteriovenous fistulas: Clinical presentations and treatment outcomes, A case-series of 12 patients. *Oper Neurosurg (Hagerstown)* 2018;15:262-9.
10. Lee SU, Kim HJ, Kang BS, Kim JS. Isolated medullary hemorrhage: Clinical features in eleven consecutive patients. *J Stroke* 2017;19:111-4.
11. Yagi R, Nishimoto Y, Yamada S, Nakashima H, Okada K, Konoeda F, *et al.* Two medullary hemorrhage cases complicated by respiratory distress in the early phase. *J Stroke Cerebrovasc Dis* 2019;28:229-31.
12. Saposnik G, Caplan LR. Convulsive-like movements in brainstem stroke. *Arch Neurol* 2001;58:654-7.
13. Pop R, Manisor M, Aloraini Z, Chibarro S, Proust F, Quenardelle V, *et al.* Foramen magnum dural arteriovenous fistula presenting with epilepsy. *Interv Neuroradiol* 2015;21:724-7.
14. Haryu S, Endo T, Sato K, Inoue T, Takahashi A, Tominaga T. Cognard type V intracranial dural arteriovenous shunt: Case reports and literature review with special consideration of the pattern of spinal venous drainage. *Neurosurgery* 2014;74:E135-42.
15. Brunereau L, Gobin YP, Meder JF, Cognard C, Tubiana JM, Merland JJ. Intracranial dural arteriovenous fistulas with spinal venous drainage: Relation between clinical presentation and angiographic findings. *AJNR Am J Neuroradiol* 1996;17:1549-54.
16. Pierot L, Chiras J, Meder JF, Rose M, Rivierez M, Marsault C. Dural arteriovenous fistulas of the posterior fossa draining into

- subarachnoid veins. *AJNR Am J Neuroradiol* 1992;13:315-23.
17. Nakajima H, Ishiguro T, Terada A, Komiyama M. Dural arteriovenous fistula of the sinus of the lesser sphenoid wing presenting with Pontine hemorrhage. *World Neurosurg* 2017;98:871.e17-23.
  18. van Dijk JM, terBrugge KG, Willinsky RA, Wallace MC. Clinical course of cranial dural arteriovenous fistulas with long-term persistent cortical venous reflux. *Stroke* 2002;33:1233-6.
  19. Kobayashi A, Al-Shahi Salman R. Prognosis and treatment of intracranial dural arteriovenous fistulae: A systematic review and meta-analysis. *Int J Stroke* 2014;9:670-7.
  20. Willinsky R, TerBrugge K, Lasjaunias P, Montanera W. The variable presentations of craniocervical and cervical dural arteriovenous malformations. *Surg Neurol* 1990;34:118-23.
  21. Rodesch G, Comoy J, Hurth M, Lasjaunias P. Jugular foramen arteriovenous shunt with subarachnoid hemorrhage. *Skull Base Surg* 1991;1:132-6.
  22. Mascalchi M, Scazzari F, Prosetti D, Ferrito G, Salvi F, Quilici N. Dural arteriovenous fistula at the craniocervical junction with perimedullary venous drainage. *AJNR Am J Neuroradiol* 1996;17:1137-41.
  23. McDougall CG, Halbach VV, Dowd CF, Higashida RT, Larsen DW, Hieshima GB. Dural arteriovenous fistulas of the marginal sinus. *AJNR Am J Neuroradiol* 1997;18:1565-72.
  24. Kai Y, Hamada J, Morioka M, Ushio Y, Fujioka S. Foramen magnum dural arteriovenous fistulae with repeated subarachnoid haemorrhage. *Interv Neuroradiol* 1998;4:171-6.
  25. Hurst RW, Bagley LJ, Scanlon M, Flamm ES. Dural arteriovenous fistulas of the craniocervical junction. *Skull Base Surg* 1999;9:1-7.
  26. Wiesmann M, Padovan CS, Pfister HW, Yousry TA. Intracranial dural arteriovenous fistula with spinal medullary venous drainage. *Eur Radiol* 2000;10:1606-9.
  27. Reings MH, Thron A, Mull M, Huffmann BC, Gilsbach JM. Dural arteriovenous fistulae at the foramen magnum. *J Neurol* 2001;248:197-203.
  28. Kim MS, Han DH, Han MH, Oh CW. Posterior fossa hemorrhage caused by dural arteriovenous fistula: Case reports. *Surg Neurol* 2003;59:512-6.
  29. Lee JY, Cho YD, Kwon BJ, Han MH. Dural arteriovenous fistula at the foramen magnum with holocord myelopathy: Case report. *Neurointervention* 2010;5:53-7.
  30. Guo LM, Zhou HY, Xu JW, Wang GS, Tian X, Wang Y, *et al.* Dural arteriovenous fistula at the foramen magnum presenting with subarachnoid hemorrhage: Case reports and literature review. *Eur J Neurol* 2010;17:684-91.
  31. Spiotta AM, Hughes G, Masaryk TJ, Hui FK. Balloon-augmented onyx embolization of a dural arteriovenous fistula arising from the neuromeningeal trunk of the ascending pharyngeal artery: Technical report. *J Neurointerv Surg* 2011;3:300-3.
  32. Guo L, Qiu Y. A dural arteriovenous fistula at the foramen magnum treated with transarterial onyx embolization. *Neurol India* 2012;60:661-3.
  33. Liang G, Gao X, Li Z, Wang X, Zhang H, Wu Z. Endovascular treatment for dural arteriovenous fistula at the foramen magnum: Report of five consecutive patients and experience with balloon-augmented transarterial onyx injection. *J Neuroradiol* 2013;40:134-9.
  34. Hiramatsu R, Kuroiwa T, Nozaki K, Kuroiwa T. Foramen magnum dural arteriovenous fistula treated by a microsurgical technique combined with a feeder occlusion using transarterial coil embolization. *Turk Neurosurg* 2015;25:971-5.
  35. Kim H, Lee YS, Kang HJ, Lee MS, Suh SJ, Lee JH, *et al.* A rare case of subarachnoid hemorrhage caused by ruptured venous varix due to dural arteriovenous fistula at the foramen magnum fed solely by the ascending pharyngeal artery. *J Cerebrovasc Endovasc Neurosurg* 2018;20:120-6.
  36. Iampreechakul P, Lertbutsayanukul P, Siriwiwommas S, Jittapiromsak P, Tantivatana J, Niruthisard S. Persistent central neuropathic pain caused by intramedullary hemorrhage from spinal dural arteriovenous fistula: A case report and literature review. *Austin J Anesthesia Analgesia* 2019;7:1076.
  37. Hetts SW, Yen A, Cooke DL, Nelson J, Jolivald P, Banaga J, *et al.* Pial artery supply as an anatomic risk factor for ischemic stroke in the treatment of intracranial dural arteriovenous fistulas. *AJNR Am J Neuroradiol* 2017;38:2315-20.
  38. Osada T, Krings T. Intracranial dural arteriovenous fistulas with pial arterial supply. *Neurosurgery* 2019;84:104-15.
  39. Bhogal P, Makalanda HL, Brouwer PA, Gontu V, Rodesch G, Mercier P, *et al.* Normal pial-dural arterial connections. *Interv Neuroradiol* 2015;21:750-8.
  40. Wu Q, Zhang XS, Wang HD, Zhang QR, Wen LL, Hang CH, *et al.* Onyx embolization for tentorial dural arteriovenous fistula with pial arterial supply: Case series and analysis of complications. *World Neurosurg* 2016;92:58-64.
  41. Iampreechakul P, Lertbutsayanukul P, Wattanasen Y, Siriwiwommas S. Progressive medullary congestion resulting in life-threatening condition caused by lower cervical dural arteriovenous fistula successfully treated with endovascular treatment: A case report and literature review. *Clin Med Rev Case Rep* 2019;6:1-11.
  42. El Asri AC, El Mostarchid B, Akhaddar A, Naama O, Gazzaz M, Boucetta M. Factors influencing the prognosis in intracranial dural arteriovenous fistulas with perimedullary drainage. *World Neurosurg* 2013;79:182-91.
  43. Iampreechakul P, Tanpun A, Lertbusayanukul P, Siriwiwommas S. Contralateral extensive cerebral hemorrhagic venous infarction caused by retrograde venous reflux into the opposite basal vein of Rosenthal in posttraumatic carotid-cavernous fistula: A case report and literature review. *Interv Neuroradiol* 2018;24:546-58.
  44. Haccin-Bey L, Daniels DL, Ulmer JL, Mark LP, Smith MM, Strottmann JM, *et al.* The ascending pharyngeal artery: Branches, anastomoses, and clinical significance. *AJNR Am J Neuroradiol* 2002;23:1246-56.