

Giant Calvarial Cavernous Hemangioma: A Rare Case Report and Review of Literature

Abstract

Primary intraosseous cavernous hemangiomas (PICHs) are benign vascular lesions that may occur in any part of the body. They account for 0.2% of all bone tumors and 10% of benign skull tumors. PICHs are usually seen in vertebral column and very rarely involve skull. We report a 36-year-old female patient with large right parietal cavernous hemangioma. The lesion had been excised completely with a good neurological outcome.

Keywords: Calvarial, primary intraosseous cavernous hemangiomas, skull

Introduction

Cavernous hemangiomas of the calvarium are rare benign tumors that account for ~ 10% of benign skull tumors.^[1] They are most frequently found in parietal and frontal bones of the skull. Calvarial hemangiomas are usually small and remain as slow-growing asymptomatic lesions. They may become symptomatic if they grow in size and become palpable tender swellings over the scalp. *En bloc* surgical resection is the treatment of choice and the prognosis after a complete excision that is excellent and recurrence is usually rare. We present a rare case of a giant cavernous hemangioma of the skull. The clinical presentation, pathology, differential diagnosis, and treatment of this rare disorder are discussed.

Case Report

A 32-year-old female patient presented with complaints of swelling over the right side of the skull for 3 years. The swelling was gradually increasing in size. On examination, a 10 cm × 14 cm swelling noted over the right parietal region. Skin over the swelling is freely mobile. The swelling is hard in consistency and nontender. No bruit heard over swelling. Neurological examination was normal.

Computed tomography (CT) of the brain revealed a hyperdense osteolytic

lesion within the diploe on the right parietal bone with a characteristic spoke-wheel pattern [Figure 1a]. The lesion was hyperintense on both T1-weighted (T1W1) [Figure 2a and b] and T2W1 [Figure 1b] images with the enhancement on contrast administration.

The patient was evaluated for primary malignancy elsewhere in the body and found to be negative.

The patient was planned for surgery. She was kept in the supine position with head turned to the left side. Horse-shoe shaped incision was given over the right fronto-parietal region and the flap was raised. Bony swelling was exposed with surrounding normal bone. A right parietal craniectomy and total lesion resection with a margin of surrounding normal bones were done under general anesthesia. During surgery, the tumor was found to be intraosseous, the outer table was thin and the inner table was eroded by the tumor, which was entirely extradural and extremely vascular causing a significant intraoperative bleeding [Figure 3a and b]. Postoperative recovery of the patient was uneventful. Histopathological examination confirmed the diagnosis of cavernous hemangioma [Figure 4].

Discussion

Primary intraosseous cavernous hemangiomas (PICHs) are benign vascular malformations that account for

Govindappagari Venkateswara Prasanna, Uday Kiran Katari, Sathish Kumar Vandanapu, Malepeddi Sireesh Reddy, Hima Bindu Adusumilli

Department of Neurosurgery, Simhapuri Institute of Neurological Sciences, Simhapuri Hospital, Nellore, Andhra Pradesh, India

Address for correspondence:

Dr. Uday Kiran Katari, Simhapuri Institute of Neurological Sciences, Simhapuri Hospital, Nellore, Andhra Pradesh, India. E-mail: uday.krn72@gmail.com

Access this article online

Website: www.asianjns.org

DOI: 10.4103/ajns.AJNS_260_18

Quick Response Code:



How to cite this article: Prasanna GV, Katari UK, Vandanapu SK, Reddy MS, Adusumilli HB. Giant calvarial cavernous hemangioma: A rare case report and review of literature. Asian J Neurosurg 2019;14:578-80.

This is an open access journal, and articles are distributed under the terms of the Creative Commons Attribution-NonCommercial-ShareAlike 4.0 License, which allows others to remix, tweak, and build upon the work non-commercially, as long as appropriate credit is given and the new creations are licensed under the identical terms.

For reprints contact: reprints@medknow.com

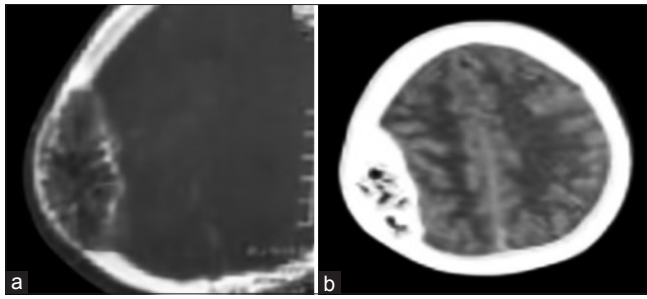


Figure 1: (a and b) Computed tomography of the brain revealed a hyperdense osteolytic lesion within the diploe on the right parietal bone with a characteristic “spoke-wheel” or “honeycomb” pattern

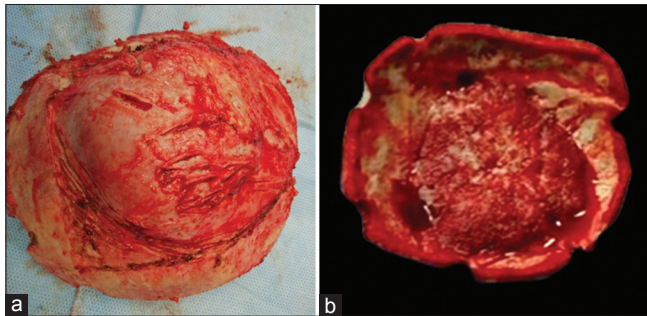


Figure 3: (a and b) Intraoperative photographs showing expansion of diploe and erosion of inner table of the skull

approximately 0.2% of all bone tumors and 10% of benign skull tumors.^[1] Hemangiomas are histologically classified into three subtypes, namely, cavernous, capillary, and mixed type. Cavernous hemangiomas are characterized by the clusters of dilated blood vessels separated by fibrous septa in contrast to capillary hemangiomas which consist of small vascular lumens without much fibrous septa. Cavernous hemangiomas are more common in the skull, whereas the capillary type is more common in the vertebral column.

Calvarial cavernous hemangiomas are more common in the frontal bone followed by parietal, temporal, and occipital bones. Cavernous hemangiomas very rarely involve the skull base. Cavernous hemangioma of the skull arises from the vessels in the diploic space and is supplied by the branches of the external carotid artery. The middle and superficial temporal arteries are the main sources of the blood supply.^[2,3] Pathogenesis of calvarial hemangiomas is not yet known fully. They are considered to be congenital. Proliferation and differentiation of the undifferentiated primitive mesenchymal cells induced by the various stimuli-like traumas may be the potential etiology. The most commonly affected age group is 40–70 years.^[4] The female-to-male ratio is 2:1–3:1.^[5] Calvarial hemangiomas are usually small and remain as slow-growing asymptomatic lesions. They may become symptomatic if they grow in size and become palpable tender swellings over the scalp. Calvarial hemangiomas may become symptomatic if they compress adjacent structures.^[6] Two types of growth patterns have been described. The first type is a “sessile” pattern that grows along the dipole, and the second is a

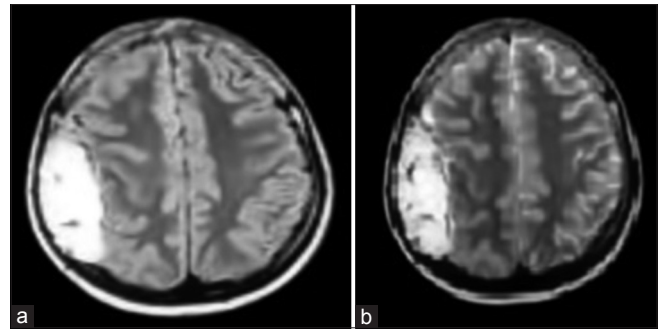


Figure 2: (a) Magnetic resonance imaging of brain T1-weighted images showing hyperintense extra-axial lesion in the right parietal region. (b) Magnetic resonance imaging of brain T2-weighted images showing hyperintense extra-axial lesion in the right parietal region

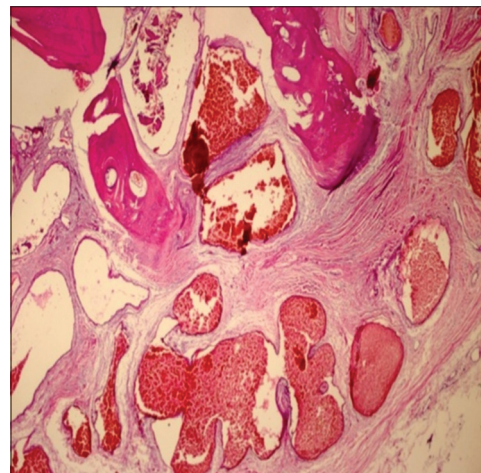


Figure 4: Photomicrograph of h and e stained preparation showing bony trabeculae with a lesion comprising of multiple large thin-walled lattice pattern of vessels, lined by thin endothelium

“globular” pattern which arises from the skull base and presents as a space-occupying lesion.^[7]

Calvarial hemangiomas usually involve the outer table of the skull. Extensive involvement of the inner table and dura are usually rare.^[8]

The investigation of choice is CT scan which classically depicts lytic expansile and bubbly lesion with a sclerotic rim also known as “sunburst” or “spoke-wheel” appearance. CT also helps in delineating the extent of tumor in to surrounding structures. Magnetic resonance imaging (MRI) signal intensity depends on the amount of venous stasis in the lesion and also on the rate of red bone marrow in to yellow marrow. T1W1 images have high-or-low intensity signals. T2W1 and fluid-attenuated inversion recovery show high-signal intensity.^[9,10]

The lesions enhance on contrast administration intensely on both CT and MRI.

Histopathology of cavernous hemangioma shows unencapsulated dilated sinusoidal channels that are lined by a single layer of flattened endothelium and are interspersed among bony trabeculae.

The other differential diagnosis of intradiploic skull masses includes eosinophilic granulomas, aneurysmal bone cysts (ABCs), dermoid tumors, metastatic deposits, meningiomas, sarcomas, and Langerhans cell histiocytosis.^[11,12]

CT findings of various pathological lesions in differential diagnosis of a skull tumor are as follows.

CT scan of Langerhans cell histiocytosis shows a lytic defect with “beveled” edges (inner Table > outer Table) and a soft-tissue mass within the defect. No periosteal reaction is seen. Soft tissue in the lytic defect enhances on contrast administration. Patients with eosinophilic granuloma are usually <5 years of age. CT scan shows a lesion with beveled edges. Hole-within – a hole/button sequestrum appearance is seen. Patients with metastasis deposits in the skull are usually older; often have a history of cancer. CT imaging shows hemorrhagic hyper intensity, with a contrast enhancing mass centered in the bone with osseous destruction lacking “benign” sclerotic border. Dermoid cyst shows a well-defined round hypodense unilocular cystic mass on CT imaging, which expands the diploe. There will be no enhancement on contrast administration.^[13] CT imaging of ABC shows sharply-defined expansile osteolytic lesion with thin sclerotic margins. Multiple fluid levels which represent sedimentation of red blood cells within blood filled cavities will be seen.^[14] Intradiploic meningioma may be osteoblastic ~ 65% or osteolytic ~ 35%. The osteolytic subtype has to be differentiated from calvarial hemangioma. Osteolytic subtype is seen as expansile lytic lesion of the skull involving the inner and outer tables with thinning of both tables. Intense contrast enhancement is usually seen.^[15]

Preoperative diagnosis of cavernous hemangiomas is often difficult because imaging findings are not specific. Histopathological examination is often necessary to confirm the diagnosis.

En bloc surgical resection with normal bone margins is the treatment of choice for PICH of the skull.^[16] Embolization before surgery is helpful to reduce the blood loss in large lesions. Radiotherapy can prevent the tumor growth but does not cure the lesion.

Conclusion

Calvarial cavernous hemangiomas are rare benign skull tumors. They most frequently involve parietal and frontal bones of the skull. They are slow-growing asymptomatic lesions. They may become symptomatic if they attain a large size or compress adjacent structures. Complete tumor excision with normal bony margins is the treatment of choice. Radiological features may not be classic sometimes and may mimic other skull tumors. Histopathological confirmation of tumor is the definitive method for the diagnosis of calvarial cavernous hemangioma. These lesions should always be considered in the differential diagnosis of skull tumors because surgery provides definitive cure for the disease.

Declaration of patient consent

The authors certify that they have obtained all appropriate patient consent forms. In the form the patient(s) has/have given his/her/their consent for his/her/their images and other clinical information to be reported in the journal. The patients understand that their names and initials will not be published and due efforts will be made to conceal their identity, but anonymity cannot be guaranteed.

Financial support and sponsorship

Nil.

Conflicts of interest

There are no conflicts of interest.

References

1. Rumana M, Khursheed N, Farhat M, Othman S, Masood L. Congenital intraosseous cavernous hemangioma of the skull: An unusual case. *Pediatr Neurosurg* 2013;49:229-31.
2. Kawai K, Fukui M, Tanaka A, Kuramoto S, Kitamura K. Extracerebral cavernous hemangioma of the middle fossa. *Surg Neurol* 1978;9:19-25.
3. Hook SR, Font RL, McCrary JA, Harper RL. Intraosseous capillary hemangioma of the frontal bone. *Am J Ophthalmol* 1987;103:824-7.
4. Ajja A, Oukacha N, Gazzaz M, Akhaddar A, Elmostarchid B, Kadiri B, *et al.* Cavernous hemangioma of the parietal bone. A case report. *J Neurosurg Sci* 2005;49:159-62.
5. Nguyen BD, McNaughton D. AJR teaching file: Nuclear imaging of a tender skull mass. *AJR Am J Roentgenol* 2007;189:S61-3.
6. Corr P. Multiple calvarial haemangiomas. *Australas Radiol* 2000;44:118-20.
7. Yoshida D, Sugisaki Y, Shimura T, Teramoto A. Cavernous hemangioma of the skull in a neonate. *Childs Nerv Syst* 1999;15:351-3.
8. Khanam H, Lipper MH, Wolff CL, Lopes MB. Calvarial hemangiomas: Report of two cases and review of the literature. *Surg Neurol* 2001;55:63-7.
9. Murrone D, De Paulis D, Millimaggi DF, Del Maestro M, Galzio RJ. Cavernous hemangioma of the frontal bone: A case report. *J Med Case Rep* 2014;8:121.
10. Yucel E, Akkaya H, Gürkanlar D, Ergun T. Congenital cavernous hemangioma of the skull. *Turk Neurosurg* 2011;21:645-7.
11. Kang DW, Choi CH. A case of calvarial hemangioma in cranioplasty site. *J Korean Neurosurg Soc* 2009;46:484-7.
12. Gordhan A, Soliman J, Malpani A, Peg E 3rd. Symptomatic calvarial cavernous hemangioma: Presurgical confirmation by scintigraphy. *J Radiol Case Rep* 2009;3:25-9.
13. Osborn AG, Salzman KL, Jhaveri MD. *Diagnostic Imaging: Brain*. 3rd ed. Philadelphia, PA: Elsevier; 2016. p. 1185-95.
14. Purohit A, Chopra S, Sinha VD, Dharker SR. Aneurysmal bone cyst of the temporal bone: A case report. *Neurol India* 2002;50:511-3.
15. Yener U, Bayrakli F, Vardereci E, Sav A, Peker S. Intradiploic meningioma mimicking calvarial metastasis: Case report. *Turk Neurosurg* 2009;19:297-301.
16. Liu JK, Burger PC, Harnsberger HR, Couldwell WT. Primary intraosseous skull base cavernous hemangioma: Case report. *Skull Base* 2003;13:219-28.