

# The Relation between Cord Signal and Clinical Outcome after Anterior Cervical Discectomy in Patients with Degenerative Cervical Disc Herniation

## Abstract

**Introduction:** Cervical spondylotic myelopathy is a cervical cord compressive lesion that occurs as a result of the normal degenerative process which may cause magnetic resonance imaging (MRI) cord intensity changes that may worsen the clinical outcome even after successful anterior cervical decompression. **Objective:** To assess the relation between MRI T2 Weighted images (T2 WI) hyperintense cord signal and clinical outcome after anterior cervical discectomy in patients with degenerative cervical disc herniation. **Materials and Methods:** This is a retrospective observational study that was conducted on twenty-five patients with degenerative cervical disc prolapse associated with MRI T2WI hyperintense cord signal, at the Department of Neurosurgery, Qena University Hospital, South Valley University from August 2014 to December 2016. A complete clinical and radiological evaluation of the patients was done. Anterior cervical discectomy and fusion was done for all patients. Patients were clinically assessed preoperatively and postoperatively at 3, 6, and 12 months using Modified Japanese Orthopedic Association (MJOA) score. Radiographic assessment was done by preoperative and postoperative T2WI MRI. The statistical analysis was done using Statistical Package for the Social Sciences (SPSS) software (version 22.0). **Results:** There were 25 patients included in the study; 16 (64%) females and 9 (36%) males. The mean age was  $46.89 \pm 7.52$  standard deviation (SD) years with range from 26 to 64 years, 3 (12%) patients had worsened in the form of postoperative motor power deterioration, and 14 (56%) patients has no improvement and remain as preoperative condition. The remaining 8 (32%) patients had a reported postoperative improvement of symptoms and signs according to MJOA score. The mean follow-up period (in months) was  $11 \pm 2.34$  (SD). **Conclusion:** The presence of T2W hyperintense signal on preoperative MRI predicts a poor surgical outcome in patients with cervical disc prolapse. The regression of T2W ISI postoperatively correlates with better functional outcomes.

**Keywords:** Anterior cervical discectomy, cervical spondylotic myelopathy, compressive myelopathy, T2 hyperintense signal, clinical outcome

## Introduction

Degenerative cervical myelopathy represents the wide spectrum of age-related changes of the cervical spine that result in spinal cord injury and dysfunction.<sup>[1]</sup> Objective clinical assessment of myelopathy can demonstrate signs such as hyperreflexia, gait ataxia, Hoffmann's sign, and ankle clonus. While the diagnosis of cervical myelopathy is primarily based on clinical assessment, magnetic resonance imaging (MRI) is typically used to confirm the diagnosis where the static compression of the cord and hyperintensity may be the most likely appearance with increasing age.<sup>[1-4]</sup>

This is an open access journal, and articles are distributed under the terms of the Creative Commons Attribution-NonCommercial-ShareAlike 4.0 License, which allows others to remix, tweak, and build upon the work non-commercially, as long as appropriate credit is given and the new creations are licensed under the identical terms.

For reprints contact: reprints@medknow.com

Several reports have thought to assess the extent of spinal cord dysfunction and the potential for postoperative neurological recovery through the evaluation of spinal cord signal changes on T2-weighted (T2WI) and T1-weighted images (T1WI).<sup>[5-13]</sup> To address this knowledge gap, MRI studies were previously conducted and reported using the AOSpine cervical spondylotic myelopathy-North America prospective multicenter data.<sup>[14,15]</sup>

## Materials and Methods

A retrospective observational study was conducted from August 2014 to December 2016 in the Neurosurgery Department, Qena University Hospital,

**How to cite this article:** Hamdan AR. The relation between cord signal and clinical outcome after anterior cervical discectomy in patients with degenerative cervical disc herniation. Asian J Neurosurg 2019;14:106-10.

## Ali Rabee Kamel Hamdan

Department of Neurosurgery,  
Faculty of Medicine, South  
Valley University, Qena, Egypt

### Address for correspondence:

Dr. Ali Rabee Kamel Hamdan,  
Department of Neurosurgery,  
Qena University Hospital,  
The 4<sup>th</sup> Floor, South Valley  
University, Qena, Egypt.  
E-mail: abdallahneuro2010@  
gmail.com

### Access this article online

Website: [www.asianjns.org](http://www.asianjns.org)

DOI: 10.4103/ajns.AJNS\_262\_17

### Quick Response Code:



South Valley University. An informed signed consent was taken from all the patients and for the use of their data before enrolling them into the study after approval of the Ethical Committee of Faculty of Medicine, South Valley University. Twenty-five patients were enrolled in the study. The inclusion criteria were patients with a diagnosed degenerative cervical disc herniation associated with MRI T2 hyperintense signal surgically treated by ACD. Patients with a history of acute cervical trauma were excluded.

Clinical and radiographical analyses were performed for all these patients. Clinical evaluation included a detailed history as a regard of symptoms, and a complete neurological assessment of motor power, sensory deficits, bulk, and tone of all the limbs was evaluated preoperatively and postoperatively at 3, 6, and 12 months using Modified Japanese Orthopedic Association (MJOA). MRI of the cervical spine was done preoperatively and 3-month postoperatively and all patient images showed T2 hyperintensity preoperatively [Figure 1]. Score MJOA was done preoperatively and at 3, 6, and 12 months postoperatively and results were tabulated and diagrammatically represented.

**Statistical analysis**

Statistical analysis was performed using SPSS software version 22.0.

**Results**

Twenty-five patients including 16 (64%) females and 9 (36%) males were included in the study, with their ages ranged from 26 years to 64 years; mean age was  $46.89 \pm 7.52$  standard deviation (SD) in years. Clinically, the data of patient symptoms and signs were collected and analyzed according to MJOA score. The predominant symptom was neck pain 96% ( $n = 24$ ), followed by difficult walking (spastic gait) and weakness 92% ( $n = 23$ ), urge incontinence 52% ( $n = 13$ ), and brachialgia 20% ( $n = 5$ ).

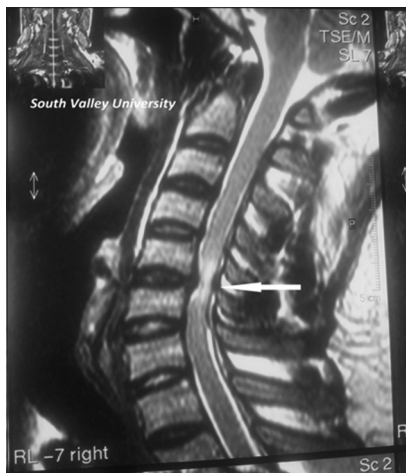

Figure 1: Magnetic resonance imaging T2 sagittal image showing cervical disc prolapse C (5-6) associated with hyperintense cord signal (white arrow)

The most common presenting clinical signs were the myelopathic types, hyperreflexia 96% ( $n = 24$ ), Babinski sign 88% ( $n = 22$ ), spastic weakness 76% ( $n = 19$ ), Hoffman sign 64% ( $n = 16$ ), clonus (patellar or ankle sustained or illsustained) 44% ( $n = 11$ ), and hyposthesia according to the affected level 20% ( $n = 5$ ) [Table 1 and Figure 2].

Postoperatively, 3 (12%) patients had worsened in the form of motor power deterioration and 14 (56%) patients have no improvement and remain as preoperative condition. The remaining 8 (32%) patients had a reported postoperative improvement. All of the twenty-five in the study were scored according to previous clinical data by MJOA score preoperatively and through follow-up visits at Qena university neurosurgery outpatient clinic at 3, 6, and 12 months and it showed slight clinical improvement as the mean MJOA score increased from  $12.89 \pm 1.39$  (SD) preoperatively up to  $13.79 \pm 1.33$  (SD) [Table 2 and Figure 3].

**Table 1: Demographic and preoperative clinical data**

Information	No. (%)
Sex	
Male	9 (36)
Female	16 (64)
Age (mean±SD)	26-64 (46.89±7.52)
Symptoms	
Neck pain	24 (96)
Spastic gait and weakness	23 (93)
Urge incontinence	13 (52)
Brachialgia	5 (20)
Signs	
Hyperreflexia	24 (96)
Babinski sign	22 (88)
Spastic weakness	19 (76)
Hoffman sign	16 (64)
Clonus (ankle and patellar)	11 (44)
Sensory hypoesthesia	5 (20)

SD – Standard deviation

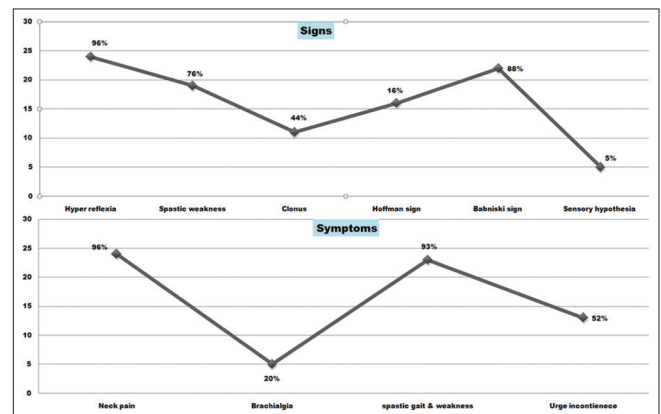


Figure 2: Linegram showing preoperative clinical signs and symptoms

Radiographically, cervical spine MRI was done preoperatively and 3-month postoperatively and all patient images showed T2 hyperintensity preoperatively [Figure 4]. Three-month postoperative MRI showed recovery of the cord signal in 19 (76%) patients while in the remaining six (24%) patients, the signal was present [Figure 5]. It was noted that nine patients out of 19 patients who showed radiographical recovery was not associated with clinical improvement.

**Discussion**

Demographic features of patients studied in preceding studies with moderate variability are shown in Table 3. In this study, we note that there were female majority in the studied cases where 25 patients were included in the study; 16 (64%) females and 9 (36%) males. Mean age was  $46.89 \pm 7.52$  SD years with range from 26 to 64 years; it is a retrospective observational study and the follow-up duration was 12 months. This is not coincidental with the formentioned studies as there were male majority and most of studies were of a prospective type.

Clinically, symptoms and signs of patients were documented and analyzed according to variable outcome scores such as Nurick score, Ranawat scale, Japanese orthopedic association score, MJOA score, and neck disability index. These scores were used variably from one study to another. MJOA Score is the most common scale used to record the neurological status as shown in [Table 4].<sup>[23]</sup>

T2W increased signal intensity (ISI) was associated with worse surgical functional outcomes. The sharp, intense, well-circumscribed ISI was associated with poorer functional status at follow-up.<sup>[26-30]</sup> Patients who had postoperative better results are those patients without T2W ISI or with postoperative regression of ISI.<sup>[20,30-32]</sup> In our study, postoperatively, 3 (12%) patients had worsened in the form of motor power deterioration, 14 (56%) patients has no improvement and remain as preoperative condition, and the remaining 8 (32%) patients had a reported postoperative improvement. All of the twenty-five in the study were scored according to previous clinical data by MJOA score preoperatively and through follow-up visits at 3, 6, and 12 months and it showed very slight clinical improvement as the mean MJOA score increased from  $12.89 \pm 1.39$  (SD) preoperatively up to  $13.79 \pm 1.33$  (SD) at the end of 1-year postoperatively.

**Table 2: Modified Japanese Orthopedic Association score preoperatively and through 1-year postoperatively**

Time of MJOA score	Mean±SD
Preoperatively	12.89±1.39
3-month postoperatively	13.32±1.26
6-month postoperatively	13.56±1.47
12-month postoperatively	13.79±1.33

MJOA – Modified Japanese Orthopedic Association;  
SD – Standard deviation

It has been suggested that tracking changes in T2W ISI after decompressive surgery could predict long-term

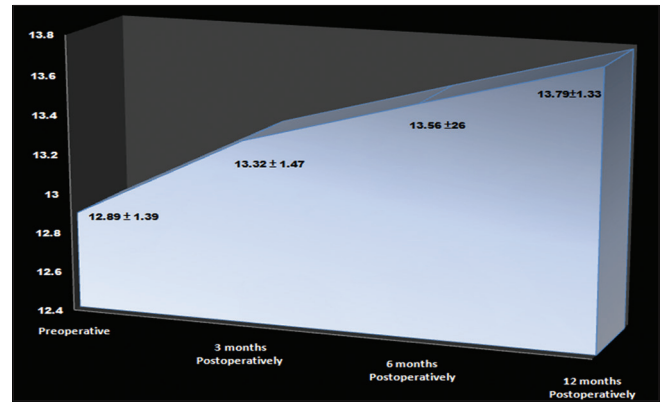


Figure 3: Three-dimensional area chart demonstrating mean Modified Japanese Orthopedic Association score preoperatively, and through 1-year postoperatively, there is slight ascending increase in the curve denoting that there is slight postoperative clinical improvement after anterior cervical discectomy was done for cervical disc prolapse associated with magnetic resonance imaging T2 hyperintensity

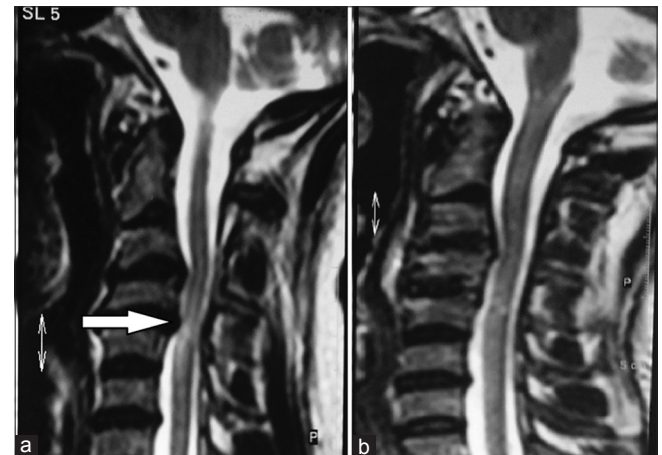


Figure 4: T2-weighted images sagittal magnetic resonance imaging showing preoperative image (a) with C (3–4), C (4–5) Disc prolapse with hyperintense cord signal (white arrow) and 3-month postoperative image (b) with recovery of the signal

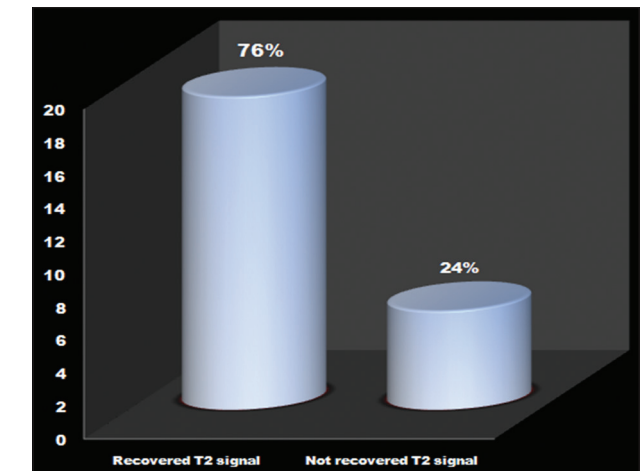


Figure 5: Three-dimensional columnar chart showing the 3-month postoperative cervical discectomy state for the cord signal recovery



**Table 3: Demographic data in preceding studies in relation to this study**

	Sex	Mean age (year)	Mean follow-up duration (months)	Type of study
Ahn <i>et al.</i> <sup>[16]</sup>	27 males (69%), 12 females (31%)	62.4	19.1	Retrospective
Arvin <i>et al.</i> <sup>[17]</sup>	34 males (65%), 18 females (35%)	56.2	12	Prospective
Kohno <i>et al.</i> <sup>[18]</sup>	15 males (68%), 7 females (32%)	60.5	61.2	Prospective
Mehalic <i>et al.</i> <sup>[19]</sup>	10 males (52%), 9 females (48%)	-	-	Retrospective
Yukawa <i>et al.</i> <sup>[20]</sup>	105 males (75%), 35 females (25%)	61	40	Prospective
Singh <i>et al.</i> <sup>[21]</sup>	40 males (57%), 29 females (43%)	Male 57, female 62	3	Prospective
Mastronardi <i>et al.</i> <sup>[22]</sup>	33 males (70%), 14 females (30%)	40.2	40.2	Prospective
In this study	9 males (36%), 16 females (64%)	46.89±7.52 (SD)	11±2.34 (SD)	Retrospective

SD – Standard deviation

**Table 4: Types of scores used by different studies**

	Outcome score
Vedantam <i>et al.</i> <sup>[24]</sup>	Nurick score
Singh <i>et al.</i> <sup>[21]</sup>	Nurick and Ranawat scales
Arvin <i>et al.</i> <sup>[17]</sup>	MJOA score, Nurick score, and NDI
Papadopoulos <i>et al.</i> <sup>[25]</sup>	MJOA score only
In this study	MJOA score only

MJOA – Modified Japanese Orthopedic Association; NDI – Neck disability index

functional outcome. Mehalic *et al.* were one of the first to provide evidence for this relationship.<sup>[19]</sup> Many studies concluded that complete or partial regression of T2W ISI postoperatively was associated with better outcomes when compared with patients who had no change in ISI after surgery.<sup>[18,22,33]</sup> Arvin *et al.* showed that an improvement in the grade of T2W ISI at 6-month postoperatively predicted better functional status at 1 year after surgery, and regression of ISI after surgery is associated with a higher probability of functional recovery.<sup>[17]</sup> In this study, 3-month postoperative MRI showed recovery of the cord hyperintense signal in 19 (76%) patients, while in the remaining 6 (24%) patients, the signal was present. It was noted that 9 patients out of 19 patients who showed radiographical recovery were not associated with clinical improvement and this is quietly similar to the overmentioned studies.

## Conclusion

The presence of T2W hyperintense signal on preoperative MRI predicts a poor surgical outcome in patients with cervical disc prolapse. The regression of T2W ISI postoperatively correlates with better functional outcomes.

## Financial support and sponsorship

Nil.

## Conflicts of interest

There are no conflicts of interest.

## References

- Nouri A, Tetreault L, Singh A, Karadimas SK, Fehlings MG. Degenerative cervical myelopathy: Epidemiology, genetics, and pathogenesis. *Spine (Phila Pa 1976)* 2015;40:E675-93.
- Ames CP, Blondel B, Scheer JK, Schwab FJ, Le Huec JC, Massicotte EM, *et al.* Cervical radiographical alignment: Comprehensive assessment techniques and potential importance in cervical myelopathy. *Spine (Phila Pa 1976)* 2013;38:S149-60.
- Cook C, Brown C, Isaacs R, Roman M, Davis S, Richardson W, *et al.* Clustered clinical findings for diagnosis of cervical spine myelopathy. *J Man Manip Ther* 2010;18:175-80.
- Karadimas SK, Gatzounis G, Fehlings MG. Pathobiology of cervical spondylotic myelopathy. *Eur Spine J* 2015;24 Suppl 2:132-8.
- Kim TH, Ha Y, Shin JJ, Cho YE, Lee JH, Cho WH, *et al.* Signal intensity ratio on magnetic resonance imaging as a prognostic factor in patients with cervical compressive myelopathy. *Medicine (Baltimore)* 2016;95:e4649.
- Kadanka Z, Kerkovsky M, Bednarik J, Jarkovsky J. Cross-sectional transverse area and hyperintensities on magnetic resonance imaging in relation to the clinical picture in cervical spondylotic myelopathy. *Spine (Phila Pa 1976)* 2007;32:2573-7.
- Tetreault LA, Dettori JR, Wilson JR, Singh A, Nouri A, Fehlings MG, *et al.* Systematic review of magnetic resonance imaging characteristics that affect treatment decision making and predict clinical outcome in patients with cervical spondylotic myelopathy. *Spine (Phila Pa 1976)* 2013;38:S89-110.
- Harrop JS, Naroji S, Maltenfort M, Anderson DG, Albert T, Ratliff JK, *et al.* Cervical myelopathy: A clinical and radiographic evaluation and correlation to cervical spondylotic myelopathy. *Spine (Phila Pa 1976)* 2010;35:620-4.
- Vedantam A, Rajshekhar V. Does the type of T2-weighted hyperintensity influence surgical outcome in patients with cervical spondylotic myelopathy? A review. *Eur Spine J* 2013;22:96-106.
- Chen CJ, Lyu RK, Lee ST, Wong YC, Wang LJ. Intramedullary high signal intensity on T2-weighted MR images in cervical spondylotic myelopathy: Prediction of prognosis with type of intensity. *Radiology* 2001;221:789-94.
- Wang LF, Zhang YZ, Shen Y, Su YL, Xu JX, Ding WY, *et al.* Using the T2-weighted magnetic resonance imaging signal intensity ratio and clinical manifestations to assess the prognosis of patients with cervical ossification of the posterior longitudinal ligament. *J Neurosurg Spine* 2010;13:319-23.
- Salem HM, Salem KM, Burget F, Bommireddy R, Klezl Z. Cervical spondylotic myelopathy: The prediction of outcome following surgical intervention in 93 patients using T1- and T2-weighted MRI scans. *Eur Spine J* 2015;24:2930-5.
- Arvin B, Kalsi-Ryan S, Mercier D, Furlan JC, Massicotte EM, Fehlings MG, *et al.* Preoperative magnetic resonance imaging is associated with baseline neurological status and can predict postoperative recovery in patients with cervical spondylotic myelopathy. *Spine (Phila Pa 1976)* 2013;38:1170-6.

14. Nouri A, Tetreault L, Zamorano JJ, Dalzell K, Davis AM, Mikulis D, *et al.* Role of magnetic resonance imaging in predicting surgical outcome in patients with cervical spondylotic myelopathy. *Spine (Phila Pa 1976)* 2015;40:171-8.
15. Nouri A, Tetreault L, Dalzell K, Zamorano JJ, Fehlings MG. The relationship between preoperative clinical presentation and quantitative magnetic resonance imaging features in patients with degenerative cervical myelopathy. *Neurosurgery* 2017;80:121-8.
16. Ahn JS, Lee JK, Kim BK. Prognostic factors that affect the surgical outcome of the laminoplasty in cervical spondylotic myelopathy. *Clin Orthop Surg* 2010;2:98-104.
17. Arvin B, Kalsi-Ryan S, Karpova A, Mercier D, Furlan JC, Massicotte EM, *et al.* Post-operative magnetic resonance imaging can predict neurological recovery following surgery for cervical spondylotic myelopathy: A prospective study with blinded assessments. *Neurosurgery* 2011;69:362-8.
18. Kohno K, Kumon Y, Oka Y, Matsui S, Ohue S, Sakaki S, *et al.* Evaluation of prognostic factors following expansive laminoplasty for cervical spinal stenotic myelopathy. *Surg Neurol* 1997;48:237-45.
19. Mehalic TF, Pezzuti RT, Applebaum BI. Magnetic resonance imaging and cervical spondylotic myelopathy. *Neurosurgery* 1990;26:217-26.
20. Yukawa Y, Kato F, Yoshihara H, Yanase M, Ito K. MR T2 image classification in cervical compression myelopathy: Predictor of surgical outcomes. *Spine (Phila Pa 1976)* 2007;32:1675-8.
21. Singh A, Crockard HA, Platts A, Stevens J. Clinical and radiological correlates of severity and surgery-related outcome in cervical spondylosis. *J Neurosurg* 2001;94:189-98.
22. Mastronardi L, Elsawaf A, Roperto R, Bozzao A, Caroli M, Ferrante M, *et al.* Prognostic relevance of the postoperative evolution of intramedullary spinal cord changes in signal intensity on magnetic resonance imaging after anterior decompression for cervical spondylotic myelopathy. *J Neurosurg Spine* 2007;7:615-22.
23. Benzel EC, Lancon J, Kesterson L, Hadden T. Cervical laminectomy and dentate ligament section for cervical spondylotic myelopathy. *J Spinal Disord* 1991;4:286-95.
24. Vedantam A, Jonathan A, Rajshekhar V. Association of magnetic resonance imaging signal changes and outcome prediction after surgery for cervical spondylotic myelopathy. *J Neurosurg Spine* 2011;15:660-6.
25. Papadopoulos CA, Katonis P, Papagelopoulos PJ, Karampekios S, Hadjipavlou AG. Surgical decompression for cervical spondylotic myelopathy: Correlation between operative outcomes and MRI of the spinal cord. *Orthopedics* 2004;27:1087-91.
26. Chatley A, Kumar R, Jain VK, Behari S, Sahu RN. Effect of spinal cord signal intensity changes on clinical outcome after surgery for cervical spondylotic myelopathy. *J Neurosurg Spine* 2009;11:562-7.
27. Mizuno J, Nakagawa H, Inoue T, Hashizume Y. Clinicopathological study of "snake-eye appearance" in compressive myelopathy of the cervical spinal cord. *J Neurosurg* 2003;99:162-8.
28. Shen HX, Li L, Yang ZG, Hou TS. Position of increased signal intensity in the spinal cord on MR images: Does it predict the outcome of cervical spondylotic myelopathy? *Chin Med J (Engl)* 2009;122:1418-22.
29. Zhang YZ, Shen Y, Wang LF, Ding WY, Xu JX, He J, *et al.* Magnetic resonance T2 image signal intensity ratio and clinical manifestation predict prognosis after surgical intervention for cervical spondylotic myelopathy. *Spine (Phila Pa 1976)* 2010;35:E396-9.
30. Suri A, Chhabra RP, Mehta VS, Gaikwad S, Pandey RM. Effect of intramedullary signal changes on the surgical outcome of patients with cervical spondylotic myelopathy. *Spine J* 2003;3:33-45.
31. Avadhani A, Rajasekaran S, Shetty AP. Comparison of prognostic value of different MRI classifications of signal intensity change in cervical spondylotic myelopathy. *Spine J* 2010;10:475-85.
32. Wada E, Yonenobu K, Suzuki S, Kanazawa A, Ochi T. Can intramedullary signal change on magnetic resonance imaging predict surgical outcome in cervical spondylotic myelopathy? *Spine (Phila Pa 1976)* 1999;24:455-61.
33. Park YS, Nakase H, Kawaguchi S, Sakaki T, Nikaido Y, Morimoto T, *et al.* Predictors of outcome of surgery for cervical compressive myelopathy: Retrospective analysis and prospective study. *Neurol Med Chir (Tokyo)* 2006;46:231-8.