

How to Treat Repeated Subdural Hematomas after Lumbar Puncture?

Abstract

Serious complications following spinal anesthesia (SA) are rare. However, surgeons and neurologist need to be aware that postsurgery headache refractory to conservative treatment or change in headache's characteristics could be due to serious intracranial complications such as a subdural hematoma. Any delay in diagnosis and treatment can be fatal. We report and discuss a case of a patient who suffered repeated subdural bleeds following SA.

Keywords: *Complications, postural puncture headache, spinal anesthesia, subdural hematoma*

Introduction

Spinal anesthesia (SA) is used worldwide for surgical procedures in the lower limbs such as arthroscopic procedures or knee prosthesis. At our institute, about 7000 SA procedures are performed annually. SA is a safe procedure, while serious complications are exceptional.^[1] The most common complication is postdural puncture headache (PDPH) which resolves in most cases with conservative treatment such as bed rest and hydration.^[2] An extremely rare event is cranial subdural hematoma.^[3] The literature reports only five cases of cranial subdural hematoma after neuraxial blockades on 1,710,000 procedures among spinal and epidural blockades between 1990 and 1999 in Sweden.^[3] A review of literature showed a higher incidence of subdural hematomas in obstetric population.^[4] This trend was confirmed by a recent review, where 56 articles about intracranial subdural hematoma following neuraxial anesthesia were identified, 34 of which occurred in the obstetric population.^[5]

In this paper, we describe the clinical presentation and management of a patient with subacute/chronic subdural cranial hematoma and brain shift after SA for a knee prosthesis.

Case Report

A 56-year-old HIV-positive male was admitted to our institution for knee arthralgia and submitted to knee prosthesis.

This is an open access journal, and articles are distributed under the terms of the Creative Commons Attribution-NonCommercial-ShareAlike 4.0 License, which allows others to remix, tweak, and build upon the work non-commercially, as long as appropriate credit is given and the new creations are licensed under the identical terms.

For reprints contact: reprints@medknow.com

The patient's pharmacological treatment at entry consisted in antiplatelet, antiviral, and analgesic medication. His full blood count and clotting were within normal range. Electrocardiography and chest X-ray were normal.

SA was performed in sitting position at L3-L4 level on the midline, using a 27-gauge SPOTTE needle BROWN (only one puncture) with 20-gauge epidural catheter; 12.5 mg of Chirocaina 0.5% was administered for analgesia with an optimal efficacy. He underwent knee prosthesis surgery that lasted 114 min. The surgical procedure was uneventful. On the 2nd day, the patient complained of headache with the typical features of postural headache without other neurological symptoms or signs, in particular, there was no nuchal rigidity. PDPH was diagnosed and treatment with paracetamol and ketorolac, bed rest therapy, and hydration started. On the 4th postoperative day, the patient was pain free and he could be discharged 4 days later with anticoagulant therapy.

Two days after discharge, the patient complained of severe headache and presented at our emergency department. Neurological examination was normal. The patient was discharged after hydration, corticosteroid (Soldesam 8 mg/die) was prescribed, and bed rest ordered.

Due to the persistence of headache and the change in the headache's characteristic, even being present in clinostatism, the patient visited again the emergency room; neurological examination was once again

How to cite this article: Zekaj E, Saleh C, Minichiello M, Perazzo P, Servello D. How to treat repeated subdural hematomas after lumbar puncture?. *Asian J Neurosurg* 2019;14:249-52.

**Edvin Zekaj,
Christian Saleh,
Marina Minichiello,
Paolo Perazzo,
Domenico Servello**

*Department of Neurosurgery
and Neurology, IRCCS Galeazzi
Hospital, 20161 Milan, Italy*

Address for correspondence:

*Dr. Edvin Zekaj,
Department of Neurosurgery,
IRCCS Galeazzi Hospital,
20161 Milan, Italy.
E-mail: ezekaj@yahoo.com*

Access this article online

Website: www.asianjns.org

DOI: 10.4103/ajns.AJNS_263_17

Quick Response Code:



normal. In consideration of the persistence of headache in clinostatism, we decided to perform a brain computed tomography (CT) scan, which showed a bilateral subdural hematoma, larger on the right side (12 mm) causing a left-sided brain shift of about 5.3 mm [Figure 1]. The patient was hospitalized at the neurosurgical unit. Antiplatelet medication was suspended. Initially, given the absence of neurological deficit and in light of the dimensions of the bleed, which were borderline for surgical intervention, we adopted for a conservative treatment which consisted in bed rest, hydration, and analgesia. Four days later, the patient complained again of worsening headache, so we performed a brain CT scan which showed an increase in density of the subdural collection with an increase in brain shift [Figure 2]. Considering that the conservative treatment was not sufficient, we considered and proposed a subdural hematoma evacuation, which the patient accepted. Surgical procedure was performed under general anesthesia and was uneventful. The postoperative CT scan showed the evacuation of the blood collection with reduction of the midline brain shift [Figure 3]. The patient reported a significant reduction of his headache. At this point, deambulation was commenced. On the 3rd postoperative day, the patient again complained of worsening of headache with accompanying photophobia. A brain CT scan was performed demonstrating a reformation of the subdural hematoma on the right side larger than that one before surgery; hydration, analgesia, and bed rest were again implemented [Figure 4a and b]. Nine days after the intervention, a cranial CT showed a further increase of the subdural blood collection with brain shift [Figure 4c]. At this point, as the only hematoma evacuation was not sufficient, we decided performing a lumbar blood patch and a surgical re-evacuation of the subdural hematoma. Lumbar blood patch was performed at L3-L4 level with midline approach, and 15 cc of a solution composed by the patient's blood, iopamiro, and fibrin glue was introduced through a Tuohy needle under fluoroscopic control. The surgical procedure was uneventful. Intraoperative fluoroscopy control showed a good extension from L2-L5 level. Surgical procedure of hematoma evacuation was regular. Radiological control showed a complete evacuation of subdural hematoma with decrease of the intracranial structure shift of the midline. The patient reported a complete resolution of headache. Three months after surgical procedure, the patient was symptom free, and CT scan showed a complete resolution of the subdural hematoma without brain shift [Figure 5].

Discussion

Our case shows how complicated management of subdural hematomas after SA may become. PDPH is the most common complication after SA, while subdural hematomas are an extremely rare entity. The low rate of incidence of the latter one renders the optimal management more

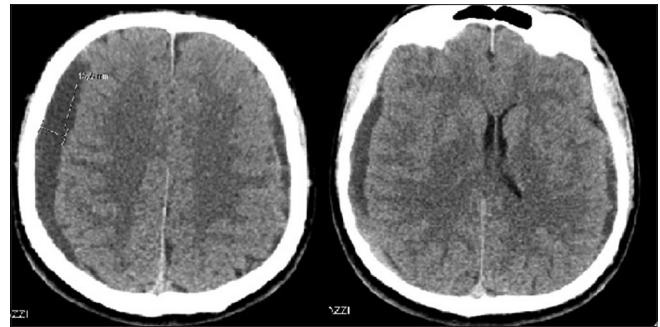


Figure 1: Computed tomography scan image shows a subdural collection on the right side with a lesser subdural collection on the left side. A midline brain shift is present

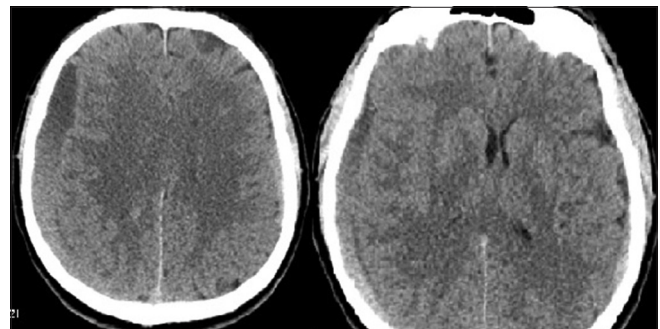


Figure 2: Computed tomography scan image: the subdural collection is increased in dimension with a higher density in the posterior part by persistent midline brain shift

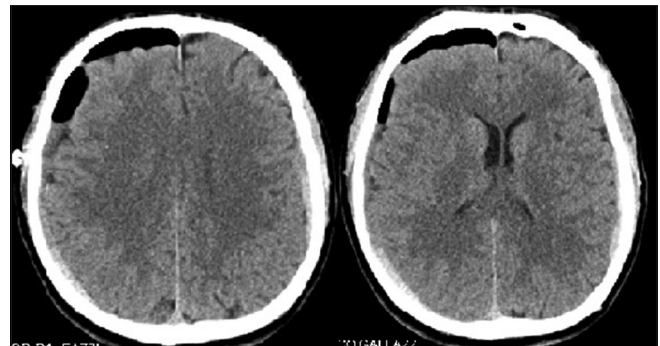


Figure 3: Postsurgical computed tomography scan control shows the evacuation of the collection with air in the anterior part and a reduction of midline brain shift

challenging. Both PDPH and postdural puncture subdural hematoma are due to a cerebrospinal fluid (CSF) leakage through the dural breach. This CSF loss causes a decrease of intraspinal and intracranial pressure accompanied by a reduction in CSF volume causing the caudal displacement of the neuraxis, first, and brain, which results in a traction of the bridging veins. Yamashima and Friede reported, based on electron microscopic data, that the wall consistency of bridging veins appear to be different in the subdural area from that in the subarachnoid space.^[6] When the traction exceeds the veins' elasticity, the vessel may rupture and bleed into the subdural space. Symptoms of subdural hematoma are linked to the mass effect and displacement

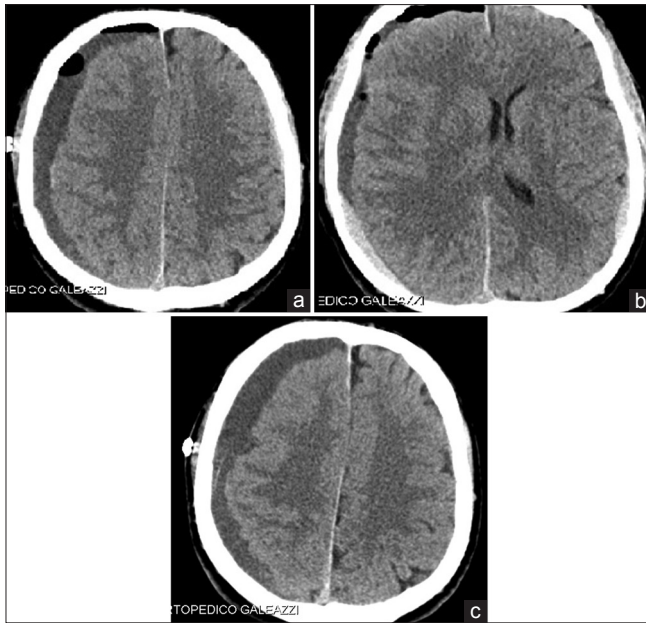


Figure 4: (a) shows the subdural collection with air inclusions (b) shows the important brain shift due to the collection (c) shows an increase in the subdural collection

exercised on intracranial structures such as contralateral paresis, speech difficulties, or sensibility disturbances.

When to suspect a subdural hematoma after SA?

We have to differentiate two entities of subdural hematomas, i.e., acute versus subacute/chronic forms. Acute subdural hematomas develop in most cases in the first 2 days after SA.^[7-11] The clinical presentation of acute subdural hematomas is due to rapid increase of intracranial pressure manifesting clinically with severe nonpostural headache and neurological deficits, such as anisocoria, paresis, and altered level of consciousness.^[12]

Such an acute clinical presentation needs an urgent brain CT scan. A subacute or chronic subdural hematoma tends to have a clinical presentation with symptoms similar to PDPH rendering proper diagnosis challenging. According to Amorim *et al.*,^[4] in approximately 95% of PDPH cases, the symptoms subsided within 5 days. When headache persists for more than 1 week after spinal blockade or it changes in its characteristics, from postural to nonpostural, and it is accompanied by other neurological signs, the possibility of intracranial complication needs to be considered promptly. In these cases, it is imperative to perform a brain CT scan. Any delay in a diagnostic work-up can have devastating consequences as fatal cases have been reported.^[13,14]

Once diagnosis is made, the treatment depends on symptom severity, hematoma dimensions, and mass effect on brain structures. For small hematomas (<10 mm), without brain shift or brain shift <5 mm and mild symptoms, a conservative management like that of PHPD with bed rest, hydration, and analgesia might be sufficient.^[4,15] Surgery should be considered for more

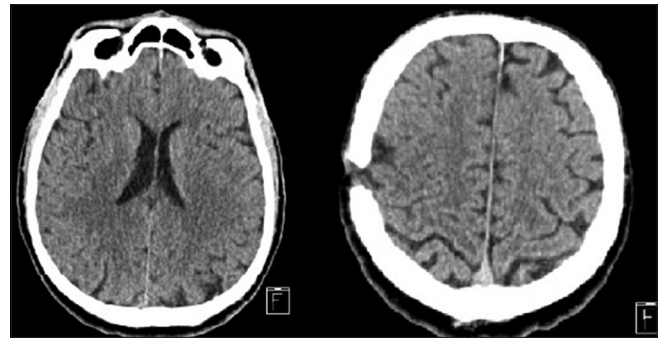

Figure 5: Control computed tomography scan shows no more subdural collection with no midline brain shift

severe cases with neurological deficits, large hematomas, and brain shift over 5 mm. There have been reported urgent surgical evacuations with craniotomy for acute subdural hematomas,^[12] subacute subdural hematomas,^[16] and chronic forms.^[4] In the above-reported studies, surgery alone resolved the clinical problem, while in our patient, cranial surgery was not sufficient.

The question that we raised was if epidural blood patch should be considered as an adjunct therapy to surgery for subdural hematoma after a dural puncture?

This argument is controversial as some authors sustain a possible worsening of neurological symptoms due to rebound intracranial hypertension,^[17] while others have performed epidural blood patch in patients with subdural hematoma.^[18,19] In our opinion, as the physiopathology of the subdural collection is probably related to acute–subacute intracranial hypotension due to CSF leakage from the dural tear, the epidural blood patch should be considered in cases of failure of standard conservative treatment for small hematomas or for patients with recurrent hematomas after surgical evacuation.

We did not experience any adverse effects from epidural blood patch application. The literature shows only a paucity of reports on adverse effects such as acute meningeal irritation,^[20] transient back pain or radiculopathy,^[21] or fever in a child after epidural blood patch use.^[22]

While in cases of hematomas of greater dimensions which have indication of surgical evacuation, hematoma larger than 10 mm, or brain shift >5 mm, epidural blood patch might be performed at the same time of surgical evacuation.

Conclusions

SA is a safe procedure with PDPH as the most frequent complication. Intracranial complication must be considered in the presence of severe nonpostural headache, with mild or severe neurological deficits. In these cases, brain CT/magnetic resonance imaging scan is imperative as misdiagnosis, or any delay in diagnosis may lead to death. Surgery is indicated for patients with neurological deficits (paresis and altered level of consciousness) and/or

hematomas >10 mm with a brain shift >5 mm. For patients who do not respond to conservative treatment or present recurrent hematomas an epidural blood patch should be considered in association with surgical evacuation.

Consent

Informed consent was obtained from the individual described in this report.

Declaration of patient consent

The authors certify that they have obtained all appropriate patient consent forms. In the form, the patient has given his consent for his images and other clinical information to be reported in the journal. The patient understands that name and initials will not be published and due efforts will be made to conceal identity, but anonymity cannot be guaranteed.

Financial support and sponsorship

Nil.

Conflicts of interest

There are no conflicts of interest.

References

1. Wheatley RG, Schug SA, Watson D. Safety and efficacy of postoperative epidural analgesia. *Br J Anaesth* 2001;87:47-61.
2. International Headache Society Classification Subcommittee. International classification of headache disorders, 2nd edition. *Cephalalgia* 2004;24:1-160.
3. Moen V, Dahlgren N, Irestedt L. Severe neurological complications after central neuraxial blockades in Sweden 1990-1999. *Anesthesiology* 2004;101:950-9.
4. Amorim JA, Remigio DS, Damázio Filho O, de Barros MA, Carvalho VN, Valença MM, *et al.* Intracranial subdural hematoma post-spinal anesthesia: Report of two cases and review of 33 cases in the literature. *Rev Bras Anesthesiol* 2010;60:620-9, 344-9.
5. Cuypers V, Van de Velde M, Devroe S. Intracranial subdural haematoma following neuraxial anaesthesia in the obstetric population: A literature review with analysis of 56 reported cases. *Int J Obstet Anesth* 2016;25:58-65.
6. Yamashima T, Friede RL. Why do bridging veins rupture into the virtual subdural space? *J Neurol Neurosurg Psychiatry* 1984;47:121-7.
7. Abbinante C, Lauta E, Di Venosa N, Ribezzi M, Colamaria A, Ciappetta P, *et al.* Acute subdural intracranial hematoma after combined spinal-epidural analgesia in labor. *Minerva Anesthesiol* 2010;76:1091-4.
8. Liang MY, Pagel PS. Bilateral interhemispheric subdural hematoma after inadvertent lumbar puncture in a parturient. *Can J Anaesth* 2012;59:389-93.
9. Ramos-Aparici R, Segura-Pastor D, Edo-Cebollada L, Vila-Sánchez M. Acute subdural hematoma after spinal anesthesia in an obstetric patient. *J Clin Anesth* 2008;20:376-8.
10. Dawley B, Hendrix A. Intracranial subdural hematoma after spinal anesthesia in a parturient. *Obstet Gynecol* 2009;113:570-3.
11. Ulivieri S, Oliveri G, Dell'Acqua S. Intracerebral haematoma following spinal anaesthesia for caesarean section: Case report. *G Chir* 2009;30:109-11.
12. Schweiger V, Zanconato G, Lonati G, Baggio S, Gottin L, Polati E, *et al.* Intracranial subdural hematoma after spinal anesthesia for cesarean section. *Case Rep Obstet Gynecol* 2013;2013:253408.
13. Yildirim GB, Colakoglu S, Atakan TY, Büyükkirli H. Intracranial subdural hematoma after spinal anesthesia. *Int J Obstet Anesth* 2005;14:159-62.
14. Demetriades AK, Sheikh MF, Minhas PS. Fatal bilateral subdural haematoma after epidural anaesthesia for pregnancy. *Arch Gynecol Obstet* 2011;284:1597-8.
15. Gómez-Ríos MÁ, Kuczkowski KM. Bilateral subdural intracranial hematoma after accidental dural puncture. *Anesthesiology* 2012;117:646.
16. Hassen GW, Kalantari H. Diplopia from subacute bilateral subdural hematoma after spinal anesthesia. *West J Emerg Med* 2012;13:108-10.
17. Ramsay M, Roberts C. Epidural injection does cause an increase in CSF pressure. *Anesth Analg* 1991;73:668.
18. Mashour GA, Schwamm LH, Leffert L. Intracranial subdural hematomas and cerebral herniation after labor epidural with no evidence of dural puncture. *Anesthesiology* 2006;104:610-2.
19. Fiala A, Furgler G, Baumgartner E, Paal P. Delayed subdural haematoma complicated by abducens nerve palsy and cortical vein thrombosis after obstetric epidural anaesthesia. *Br J Anaesth* 2012;108:705-6.
20. Oh J, Camann W. Severe, acute meningeal irritative reaction after epidural blood patch. *Anesth Analg* 1998;87:1139-40.
21. Tekkök IH, Carter DA, Brinker R. Spinal subdural haematoma as a complication of immediate epidural blood patch. *Can J Anaesth* 1996;43:306-9.
22. Hunyady AI, Anderson CT, Kuratani JD, Kundu A. Fever following an epidural blood patch in a child. *Case Rep Anesthesiol* 2012;2012:753875.