

Microvascular Decompression in Patients Aged 30 Years or Younger

Abstract

Objective: The aim of this study was to identify the etiology of hemifacial spasm (HFS) and trigeminal neuralgia (TN) in patients aged 30 years or younger and to examine the efficacy of microvascular decompression (MVD). **Patients and Methods:** Between 1996 and 2012, 228 HFS and 190 TN patients underwent MVD at Atsuchi Neurosurgical Hospital. Of these, 7 patients were 30 years of age or younger at the time of treatment (HFS: $n = 6$, TN: $n = 1$). Assessments were based on their medical history and on magnetic resonance imaging, magnetic resonance angiography, surgical, and follow-up findings. **Results:** The age of the 6 HFS patients ranged from 23 to 30 years (mean 27.8 ± 1.8 [standard deviation] years) at the time of surgery; the earliest symptom onset was in an 11-year-old boy. We noted vascular variations in 5 patients, a duplicate posterior inferior cerebellar artery in 2 patients, a short basilar artery in 1 patient, and an aberrant arterial course in 2 patients. At the latest follow-up, 1–69 months after MVD, 5 of the HFS patients were asymptomatic and the 6th had mild residual symptoms. A 23-year-old TN female underwent straightening of the trigeminal nerve by separation of a thickened arachnoid membrane from the nerve and dislocation of a small branch of the superior cerebellar artery from the distal end of the root exit zone. While she continued to experience occasional facial pain 48 months after the operation, she required no medication because surgery yielded significant pain amelioration. **Conclusion:** Although the pathogenesis of early-onset HFS and TN remains unclear, our findings suggest that vascular variations may be related to the etiology of vascular compression symptoms in patients with HFS or TN. MVD was useful for the treatment of neurovascular compression symptoms in young patients.

Keywords: Hemifacial spasm, surgical outcome, trigeminal neuralgia, vascular variation, young

Introduction

Microvascular decompression (MVD) for hyperactive dysfunction of cranial nerves was developed by Gardner and Miklos^[1,2] and discussed by Jannetta^[3-5] after the introduction of microsurgery under an operative microscope. MVD for trigeminal neuralgia (TN) has been shown to afford complete and long-lasting relief of pain in 70%–91% of adult patients.^[6,7] On hemifacial spasm (HFS), the cure rate of MVD was from 54% to 85%.^[8-12] HFS is seen almost exclusively in middle-aged and older individuals, predominately women.^[3-5,13,14] It is extremely rare in children.^[15-18] TN, primarily a disease of the elderly, is thought to be related to atherosclerotic changes in posterior fossa arteries that increase their tortuosity and result in the vascular compression that elicits TN.^[19] Hemodynamic effects due to the aging process and to hypertension in elderly patients result in the elongation, redundancy, and atherosclerosis of the

involved artery.^[3,16] Such changes in the vasculature are not likely to be implicated in younger patients with HFS and TN. We reviewed 6 patients with HFS and 1 patient with TN who underwent MVD at a single institution (contributor's institute no. 3) when they were 30 years old or younger.

Patients and Methods

Among 418 patients who underwent MVD between January 1996 and December 2012, 228 (55%) presented with HFS and 190 (45%) presented with TN; 142 HFS (62%) and 114 TN patients (60%) were female. HFS was on the left side in 126 of the 228 HFS patients (55%); TN was on the right side in 115 of the 190 TN patients (61%) [Table 1].

We focused on 7 patients who were 30 years old or younger at the time of MVD; 6 patients were treated for HFS and 1 patient for TN. The age of 30 years or younger accounted for 2.64% (6/227) of all HFS patients and 0.52% (1/190)

Prasanna Karki^{1,2,3},
Masayuki Yamagami^{2,3},
Koji Takasaki^{2,3},
Manoj Bohara^{1,2},
Hiroschi Hosoyama²,
Tomoko Hanada²,
Fumiyuki Yamasaki⁴,
Ryosuke Hanaya²,
Kazunori Arita²

¹Department of Neurosurgery, Nepalgunj Medical College and Teaching Hospital, Nepalgunj, Nepal, ²Department of Neurosurgery, Graduate School of Medical and Dental Sciences, Kagoshima University, ³Division of Neurosurgery, Atsuchi Neurosurgical Hospital, Kagoshima, ⁴Department of Neurosurgery, Graduate School of Biomedical and Health Sciences, Hiroshima University, Hiroshima, Japan

Address for correspondence:

Dr. Ryosuke Hanaya,
Department of Neurosurgery,
Graduate School of Medical and
Dental Sciences, Kagoshima
University, 8-35-1, Sakuragaoka,
890-8544, Kagoshima, Japan.
E-mail: hanaya@m2.kufm.
kagoshima-u.ac.jp

Access this article online

Website: www.asianjns.org

DOI: 10.4103/ajns.AJNS_266_17

Quick Response Code:



How to cite this article: Karki P, Yamagami M, Takasaki K, Bohara M, Hosoyama H, Hanada T, *et al.* Microvascular decompression in patients aged 30 years or younger. *Asian J Neurosurg* 2019;14:111-7.

This is an open access journal, and articles are distributed under the terms of the Creative Commons Attribution-NonCommercial-ShareAlike 4.0 License, which allows others to remix, tweak, and build upon the work non-commercially, as long as appropriate credit is given and the new creations are licensed under the identical terms.

For reprints contact: reprints@medknow.com

Table 1: Baseline characteristic of 418 patients

Characteristic	HFS >30 years	HFS ≤30 years	TN >30 years	TN ≤30 years
All patients (n=418)	222	6	189	1
Female:male ratio	140:82	2:4	113:76	1:0
Left:right ratio	125:97	1:5	74:115	1:0
Compressing vessel involved, n (%)				
AICA	55 (24.8)	2 (33.3)	21 (11.1)	-
PICA	75 (33.8)	2 (33.3)	5 (2.6)	-
SCA	2 (0.9)	-	86 (45.5)	1 (100)
VA	4 (1.8)	-	2 (1.1)	-
AICA + PICA	30 (13.5)	-	-	-
AICA + VA	19 (8.6)	-	-	-
PICA + VA	23 (10.4)	-	1 (0.5)	-
AICA + PICA + VA	14 (6.3)	-	-	-
AICA + SCA	-	-	26 (13.8)	-
PICA + SCA	-	-	1 (0.5)	-
AICA + BA	-	-	1 (0.5)	-
SCA + BA	-	-	1 (0.5)	-
VA + BA	-	-	2 (1.1)	-
Vein	-	-	10 (5.3)	-
Vein + artery	-	-	12 (6.3)	-
Atypical	-	-	4 (2.1)	-
Adhesion	-	-	5 (2.6)	-
Duplicated SCA	-	-	2 (1.1)	-
Duplicated PICA	-	2 (33.3)	-	-
Adhesion due to previous MVD	-	-	10 (5.3)	-

AICA – Anterior inferior cerebellar artery; PICA – Posterior inferior cerebellar artery; SCA – Superior cerebellar artery; VA – Vertebral artery; BA – Basilar artery; MVD – Microvascular decompression; TN – Trigeminal neuralgia

of all TN patients. The patients underwent preoperative magnetic resonance imaging (MRI) studies including fast imaging with steady-state acquisition (FIESTA); in all patients, we acquired magnetic resonance angiography (MRA) images.

Surgical technique for microvascular decompression

All procedures were performed by exploring the cerebellopontine angle through a small retrosigmoid craniectomy; auditory brain stem evoked responses were monitored throughout the procedure. For HFS, we dissected the arachnoid membrane covering the 9th, 10th, and 11th cranial nerves for easy retraction of the flocculonodular lobe. After reaching the root exit zone (REZ) of the facial nerve, the involved artery was mobilized from the compressed facial nerve and an arterial loop was fixed to the dura with a bundle of Teflon fibers soaked in fibrin glue. For TN, the horizontal fissure of the cerebellum was opened widely to visualize the root entry zone (REZ) of the trigeminal nerve for identification of the involved vessel.

Ethical consideration

This retrospective study was approved by the Ethical Committee (reference no: 170159) at contributor's institute no. 2.

Results

Hemifacial spasm in youth

Neither 6 patients with HFS (4 males, 2 females, age range 23–30 years at the time of surgery, mean 27.8 + 1.8) nor a 23-year-old female patient with TN had a history of head injury, intracranial tumors, meningitis, or other infectious diseases [Table 2]. Different from the older HFS group (n=222) with 97 (44%) on the right side and 125 (56%) on the left side, 5 of 6 HFS patients younger than 30 years old were strongly involved on the right side. The earliest onset occurred at the age of 11 years (Case 1), and in the other 5 patients, the age at onset ranged from 23 to 30 years. One patient (Case 2) suffered persistent facial spasms for 2 years after her first MVD procedure performed at a different institute when he was 22 years old and mild spasms after undergoing MVD at our hospital. The initial symptom in 5 patients was a slight twitching of the lower eyelid, which later involved the entire face ipsilaterally. In 4 patients (Cases 1, 2, 3, and 6), we observed mild facial spasms at the time of discharge; at the latest postoperative follow-up (mean 29.7 months), 5 patients (Cases 2–6) were asymptomatic. None of the operated patients developed postoperative complications.

Vascular variations in hemifacial spasm

In Case 1, the anterior inferior cerebellar artery (AICA) was located between the distal part of the 7th and 8th cranial nerve [Figure 1]. Case 2 presented with a posterior inferior cerebellar artery (PICA) duplication [Figure 2]. MRI showed that the PICA of the distal origin compressed the REZ. The 4th patient also harbored a PICA duplication [Figure 3]; MRI revealed that the distal PICA was involved. In the 5th patient, the right AICA originated from the distal vertebral artery (VA). This patient's basilar artery (BA) was short (18 mm) [Figure 4]; its loop compressed the REZ. The AICA was transpositioned and fixed to dura mater. Intraoperatively, we detected no atherosclerotic changes in arteries explored during surgery in any of the 5 patients.

Trigeminal neuralgia in a youth

Our sole patient with left-sided TN (Case 7) was initially treated with carbamazepine, which yielded pain amelioration. However, her pain reappeared 4 weeks later and MRI revealed deformation of the trigeminal nerve root [Figure 5]. Intraoperatively, we found that a thick arachnoid membrane surrounded the trigeminal nerve. A branch of the left superior cerebellar artery (SCA) passed between the motor and sensory components of the nerve at the distal part of the REZ, and the root was bent dorsally.

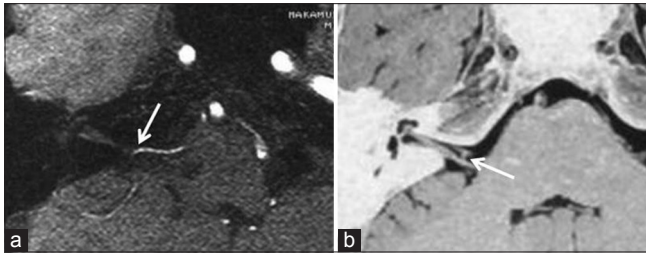


Figure 1: Case 1 (a) Axial enhanced magnetic resonance imaging demonstrating the right anterior inferior cerebellar artery (arrow) at the distal portion of the 7th and 8th cranial nerve complex, (b) axial T2 reverse magnetic resonance imaging showing the right anterior inferior cerebellar artery (arrow) between the 7th and 8th cranial nerve

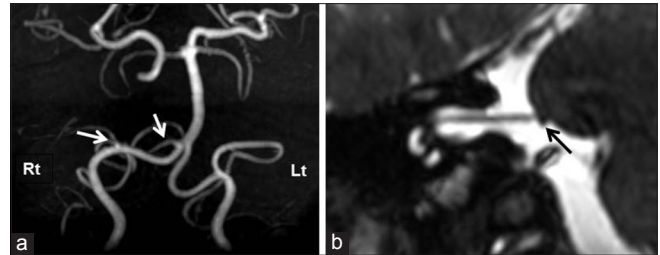


Figure 2: Case 2 (a) magnetic resonance angiography showing duplication of posterior inferior cerebellar artery (arrows) on the right side, (b) sagittal three-dimensional fast imaging with steady-state acquisition magnetic resonance imaging showing the artery (arrow) compressing the root exit zone

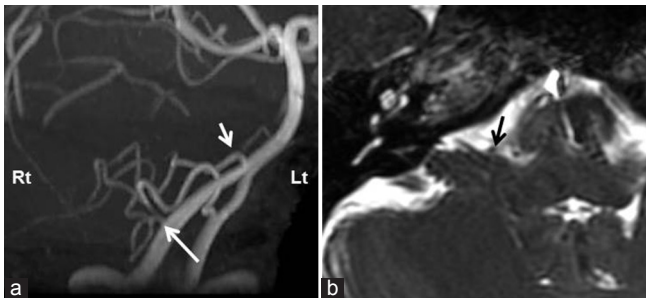


Figure 3: Case 4 (a) magnetic resonance angiography showing posterior inferior cerebellar artery duplication (arrows) on the right side, (b) axial three-dimensional fast imaging with steady-state acquisition magnetic resonance imaging showing distal posterior inferior cerebellar artery (arrow) compressing the root exit zone

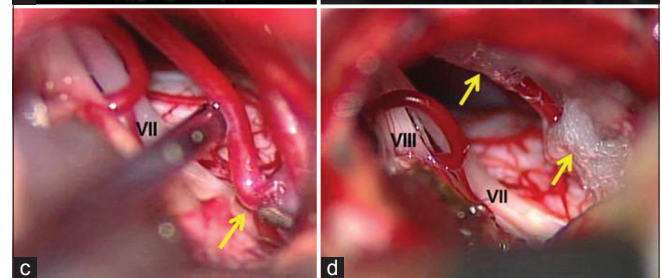
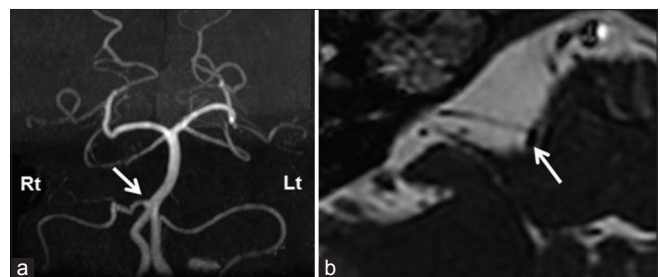


Figure 4: Case 5 (a) magnetic resonance angiography showing the origin of the right anterior inferior cerebellar artery from the distal vertebral artery (arrow) and short basilar artery, (b) axial three-dimensional fast imaging with steady-state acquisition magnetic resonance imaging showing the right anterior inferior cerebellar artery (arrow) compressing the root exit zone, (c) intraoperative photograph of the site compressed by the right anterior inferior cerebellar artery (arrow) intraoperative photograph, (d) the right anterior inferior cerebellar artery is transpositioned and fixed to the dura mater with two Teflon slings (arrows) and fibrin glue

Separating the membrane from the nerve fibers straightened the trigeminal root. After separating a branch of the SCA from the nerve fibers, we transpositioned it distally from the REZ and fixed it to the dura mater with Teflon fibers and fibrin glue. In the course of 4-year postoperative follow-up, she reported occasional facial pain not requiring medication.

Discussion

Hemifacial spasms in youth

HFS is primarily seen in middle-aged and older individuals;^[3-5,12,19] primary HFS is extremely rare in younger persons.^[15-18] The major offending vessel in 4 of our 6 young HFS patients was the PICA; the AICA was involved in the other 2 cases. In 5 previously reported HFS patients younger than 18 years, the major offender was the AICA.^[20] In another series of individuals younger than 25 years, the PICA was involved in 17 (51.5%) and the AICA in 13 (39.4%) of 33 patients. Multiple vessels were implicated in the other 3 patients (9.1%).^[21] Ehni and Woltman first suggested atherosclerosis as a possible etiology in patients with HFS^[15] and Jannetta^[3] cited elongation and tortuosity of the vascular loop and sagging of the brain that accompanies the aging process as factors in vascular compression in the elderly. Such vasculitic change of the offending vessels do not adequately explain HFS in young individuals. While arachnoid membrane thickening, venous compression, and venous anomalies may trigger HSF

in some young individuals,^[16,20,22-24] Chang *et al.*^[21] detected neither anatomical vessel variations nor arachnoid thickening around the REZ and cerebellopontine cistern in their series. Others^[23] attributed HFS to a posterior cranial fossa of small volume due to basilar invagination and/or a flat skull base^[23] or to narrowing of the posterior fossa and a Chiari type 1 malformation resulting in the neurovascular compression seen in patients with HFS.^[25,26]

Trigeminal neuralgia in youth

Mason *et al.*^[27] encountered a 13-month-old child with typical TN; the patient underwent MVD at the age of 7 years when marked venous compression of the nerve was revealed. In their large series, Resnick *et al.*^[28] reported 23 patients in whom TN developed at an age younger than 18 years. Their patients underwent surgery at a mean age

Table 2: Summary of 7 patients with hemifacial spasm or trigeminal neuralgia who were 30 years or less at the time of microvascular decompression

Case number	Age at onset (year old)	Sex	Age at surgery	Side	Diagnosis	Offending vessels	Vascular variation and length of BA (mm)	Other treatment before surgery (duration of therapy)	Symptoms at discharge	Symptoms at the latest follow-up (duration after surgery)
1	11	Male	24	Right	HFS	AICA	AICA between 7 th and 8 th nerve BA: 22.0	Diazepam (intermittently 4 years)	Slight facial spasm	Slight facial spasm (1 month)
2	24	Female	26	Right	Recurrent	PICA	Duplicated PICA BA: 22.8	MVD (preceding 2 years)	Mild blepharospasm	Asymptomatic (69 months)
3	Unknown	Male	30	Right	HFS	PICA	None BA: 27.3	Botulinum toxin (2 years)	Slight facial spasm	Asymptomatic (10 months)
4	21	Female	28	Right	HFS	PICA	Duplicated PICA BA: 22.9	Botulinum toxin (prior year)	No symptoms	Asymptomatic (21 months)
5	29	Male	29	Right	HFS	AICA	Very short BA BA: 18.0	Clonazepam (6 months)	No symptoms	Asymptomatic (42 months)
6	25	Male	26	Left	HFS	PICA	None BA: 22.7	None	Mild facial spasm	Asymptomatic (17 months)
7	23	Female	23	Left	TN	SCA branch	SCA branch between motor and sensory component BA: 21.6	Carbamazepine (2 months)	No symptoms	Residual facial pain (48 months)

HFS – Hemifacial spasm; TN – Trigeminal neuralgia; AICA – Anterior inferior cerebellar artery; PICA – Posterior inferior cerebellar artery; SCA – Superior cerebellar artery; BA – Basilar artery; MVD – Microvascular decompression

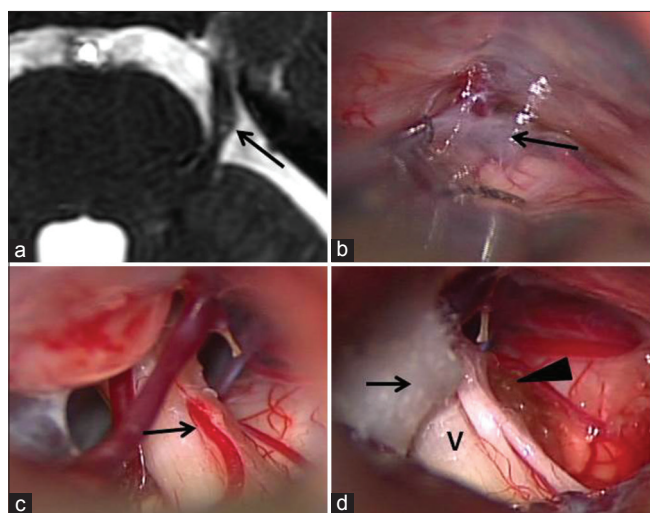


Figure 5: Case 7 (a) axial three-dimensional fast imaging with steady-state acquisition magnetic resonance imaging showing deformation of the left trigeminal nerve root (arrow), (b) intraoperative photograph. The arachnoid membrane is thick (arrow) around veins, arteries, and nerves, (c) intraoperative photograph. A left superior cerebellar artery branch passing between the motor and sensory component of the 5th cranial nerve (arrow), (d) intraoperative photograph. A left superior cerebellar artery branch is transpositioned distally and fixed to the dura mater of the suprameatal tubercle using a Teflon sling (arrow), a Teflon ball (arrowhead), and fibrin glue

of 29.1 years, venous compression was found in 20 (87%). While Matsushima *et al.*^[29] reported that TN due to venous compression is rare (5.8%), others documented a high rate in TN patients, including young individuals [Table 3].^[28,30-32]

Our series included one patient with TN (Case 7); it first occurred appeared when she was 23 years old. We detected no venous compression, rather, a thickened arachnoid membrane bent the trigeminal root, and the SCA branch went through the root, a phenomenon that has also been observed in patients with HFS.

Vascular variations

While Jho and Jannetta^[16] suggested that anatomical variations in vessels at the base of the brain or at the REZ contribute to the development of HFS in youngsters,^[16] Chang *et al.*^[21] detected no such anatomic variations and no arachnoid thickening. In older patients, a characteristic angiographic finding is enlargement of the VA on the side ipsilateral to the HFS, resulting in a sharp, hairpin curve at the 4th segment of the VA. Furthermore, the ipsilateral PICA which branches at the angulated portion is commonly more ectatic, elongated, and redundant than the vessel on the contralateral side.^[33] While vertebral angiograms of young HFS patients usually do not show such changes in the vasculature of the vertebro-BA,^[22] 5 of our 7 patients manifested various types of vascular variations. Two patients (Cases 2 and 4) had a PICA duplication with the distal PICA being the offender; in another 2 (Cases 3 and 6), we detected an aberrant arterial course. The AICA ran between the 7th and 8th nerves in a patient with HFS (Case 1) and a branch of the SCA ran between the motor and sensory components of the 5th nerve in our TN patient (Case 7). The length of BA was reported to be

Table 3: Putative causes/triggering factors and surgical outcomes in young patients treated for hemifacial spasms and trigeminal neuralgia

	Age at the surgery (year old)	Age at the onset (year old)	Possible causes except for typical artery compression	Incidence, objective/total cases (%)	Surgical outcome				Mean follow-up period (months)
					Objective cases		All cases		
					Excellent	Partial	Excellent	Partial	
Hemifacial spasm									
Chang <i>et al.</i> , 2001 ^[21]	11-25 (n=33)	21-30	Venous compression/both venous and arterial compression	0/33 (0)	-	-	29/33 (87.9)	2/33 (6)	22.3
Feng <i>et al.</i> , 2011 ^[20]	9-18 (n=5)	5-14	Thickening of the arachnoid membrane	0/33 (0)					
Jho and Jannetta, 1987 ^[16]	13-57 (n=10)	6-20	Both venous and arterial compression	1/5 (20)	-	1/1 (100)	2/5 (40)	3/5 (60)	16.8 (3-27)
Kobata <i>et al.</i> , 1995 ^[22]	17-28 (n=8)	15-24	Thickening of the arachnoid membrane	1/5 (20)	1/1 (100)	-			
Levy <i>et al.</i> , 1997 ^[24]	13-56 (n=12)	6-17	Venous compression	2/10 (20)	2/2 (100) ^a	-	9/10 (90)	0/10 (0)	87.6 (18-132)
Liang <i>et al.</i> , 2014 ^[23]	13-36 (n=16)	11-18	Both venous and arterial compression	1/10 (10)	1/1 (100)	-			
			Thickened arachnoid membrane thickening encasing the offending artery	7/7 (100) ^b	7/7 (100)	-	-	-	NA
			Venous compression	3/12 (25)	-	-	6/9 (67) ^c	0/9 (0) ^c	125 (83-223)
			Both venous and arterial compression	5/12 (42)					
			Small volume posterior of cranial fossa due to basilar invagination and/or flat skull base	9/16 (56)	NA	NA	14/16 (88)	2/16 (13)	22.9 (1-44)
			Thickening and adhesion of the arachnoid membrane	13/16 (81)					
Trigeminal neuralgia									
Bahgat <i>et al.</i> , 2011 ^[30]	15-24.5 (n=7)	20.6-25	Venous compression	6/7 (86)	2/6 (33) ^d	3/6 (50) ^e	2/7 (29) ^d	3/7 (43) ^e	35.6 (6-108)
Bender <i>et al.</i> , 2011 ^[31]	3-18 (n=6)	NA	Venous compression	3/6 (50)	3/3 (100)	-	5/6 (83)	1/6 (17)	15.3 (9.1-24.8)
			Both venous and arterial compression	1/6 (17)	-	1/1 (100)			
Mousavi <i>et al.</i> , 2016 ^[32]	10-30 (n=21)	NA	Venous compression	6/21 (29) ^f	0/6 (0)	0/6 (0)	6/21 (29)	2/21 (10)	83.4 (6-108)
			Both venous and arterial compression	6/21 (29) ^g	3/6 (50)	1/6 (16.7)			
Resnick <i>et al.</i> , 1998 ^[28]	3-53 (n=22)	2-18	Venous compression	5/22 (23)	NA	NA	9/21 (43) ^h	2/21 (10) ^h	105.2 (12-225)
			Both venous and arterial compression	14/22 (64)	NA	NA			

^aOne patient experienced 2 recurrences, A 3rd operation resulted in relief, ^bOne patient who underwent previous surgery at another hospital was excluded, ^cThree patients were excluded because the follow-up period was with <12 months, ^dBoth patients needed a 2nd operation, ^eOne patient needed a 2nd operation, ^fAll 6 patients underwent additional invasive treatment including MVD, ^gFour patients had additional invasive treatment including MVD, ^hOne patient was lost to follow-up. MVD – Microvascular decompression; NA – Not available

24–36 mm (average 30 mm).^[34,35] According to Saeki and Rhoton,^[36] it ranges from 15 to 40 mm (mean 32 mm). Based on our MRA measurements, it ranged from 18.0 to 27.3 mm (mean 22.5 ± 2.7 mm) and we cannot preclude a length underestimation. In one patient with HFS (Case 5), the BA length was only 18 mm.

Vascular compression syndrome (HFS or TN) cannot be attributed to any particular type of variation because vascular variations are not very rare although we observed this phenomenon in 5 of our 7 patients. We think that vascular variations may be involved in the etiology of vascular compression syndrome in young adults. Ohta *et al.*^[37] reported that arteriosclerotic changes were not involved in the pathogenesis of HFS and that vascular compression syndrome was attributable, even in adults, to anatomical features of the intracranial arteries and facial nerves formed during the prenatal stage.

Surgical outcome of microvascular decompression in young patients

Although mild facial spasms persisted in the perioperative period in 4 of our 6 HFS patients, in the course of postoperative follow-up (mean 29.71 months), 5 reported their complete disappearance. Samii *et al.*^[38] found that among 117 HFS patients (mean age 54.5 years) who underwent MVD, 69 (59%) were spasm free at the time of discharge and 106 (91%) experienced no symptoms during a mean follow-up duration of 9.4 years. In another series of 1642 HFS patients, 56 (3.4%) of whom were younger than 30 years at the time of MVD; there was no significant difference between young and older patients in terms of symptom duration and surgical outcomes.^[39] Therefore, immediate as well as long-term postoperative outcomes appear to be similar in young and older patients with HFS. Thickening of the arachnoid membrane (our Case 7) and a small posterior cranial fossa volume may not be predictive of a poor prognosis after MVD; while the prognosis may be poor in cases, the offending vessel is a vein [Table 3].^[20,22,23]

In 294 of 362 adults (81%) with TN, Sindou *et al.*^[40] reported a successful outcome 1 year after MVD; the cure rate fell to 75% at 15 years. Barker *et al.*^[7] also obtained an excellent outcome (79.7%) at 1 year after surgery in their TN patients; the outcome at 10 years was also excellent in 69.6%. In other case series, MVD to treat TN in young patients yielded unsatisfactory results^[28,30,32] although Bender *et al.*^[31] reported a good outcome in 83% of their patients [Table 3]. TN associated with veins is more common in young patients and may be a factor associated with unfavorable MVD outcomes in young TN patients.

Conclusion

Although the etiology of early-onset HFS and TN remains unclear, our findings suggest that vascular variations may be a contributing factor in the nerve compression seen

in younger patients. At least with respect to young HFS patients, the outcomes of MVD are comparable to those in older patients.

Financial support and sponsorship

Nil.

Conflicts of interest

There are no conflicts of interest.

References

- Gardner WJ, Miklos MV. Response of trigeminal neuralgia to decompression of sensory root; discussion of cause of trigeminal neuralgia. *J Am Med Assoc* 1959;170:1773-6.
- Gardner WJ, Sava GA. Hemifacial spasm: A reversible pathophysiologic state. *J Neurosurg* 1962;19:240-7.
- Jannetta PJ. Neurovascular compression in cranial nerve and systemic disease. *Ann Surg* 1980;192:518-25.
- Jannetta PJ. Treatment of trigeminal neuralgia by microoperative decompression. In: Youmans JR, editors. *Neurological Surgery*. 2nd ed. Vol. 6. Philadelphia, USA: W.B. Saunders Co.; 1982. p. 3589-603.
- Jannetta PJ. Microsurgical management of trigeminal neuralgia. *Arch Neurol* 1985;42:800.
- Barba D, Alksne JF. Success of microvascular decompression with and without prior surgical therapy for trigeminal neuralgia. *J Neurosurg* 1984;60:104-7.
- Barker FG 2nd, Jannetta PJ, Bissonette DJ, Larkins MV, Jho HD. The long-term outcome of microvascular decompression for trigeminal neuralgia. *N Engl J Med* 1996;334:1077-83.
- Choi SJ, Sung KW, Sung WH, Lee JS, Kang JK, Choi CR. The clinical analysis of 75 patients which were operated on MVD. *J Korean Neurosurg Soc* 1990;19:506-12.
- Huang CI, Chen IH, Lee LS. Microvascular decompression for hemifacial spasm: Analyses of operative findings and results in 310 patients. *Neurosurgery* 1992;30:53-6.
- Huh R, Han IB, Moon JY, Chang JW, Chung SS. Microvascular decompression for hemifacial spasm: Analyses of operative complications in 1582 consecutive patients. *Surg Neurol* 2008;69:153-7.
- Jang IH, Lee YH, Chung UW. Intraoperative electromyographic monitoring of the facial nerve during microvascular decompression for hemifacial spasm. *J Korean Acad Rehabil Med* 1994;18:142-51.
- Jannetta PJ. Hemifacial spasm. *Neurol Neurosurg Update Ser* 1982;3:1-7.
- Loeser JD, Chen J. Hemifacial spasm: Treatment by microsurgical facial nerve decompression. *Neurosurgery* 1983;13:141-6.
- Wilkins RH. Hemifacial spasm: A review. *Surg Neurol* 1991;36:251-77.
- Ehni G, Woltman HW. Hemifacial spasm: Review of one hundred and six cases. *Arch Neurol Psychiatry* 1945;53:205-11.
- Jho HD, Jannetta PJ. Hemifacial spasm in young people treated with microvascular decompression of the facial nerve. *Neurosurgery* 1987;20:767-70.
- Langston JW, Tharp BR. Infantile hemifacial spasm. *Arch Neurol* 1976;33:302-3.
- Milani N, Scaioli V, Giombini S, Grisoli M, Angelini L. Hemifacial spasm in a child. *Childs Nerv Syst* 1991;7:466-8.
- Jannetta PJ. Arterial compression of the trigeminal nerve at the pons in patients with trigeminal neuralgia. *J Neurosurg* 1967;26

- Suppl:159-62.
20. Feng B, Zheng X, Zhang W, Yang M, Tang Y, Zhong J, *et al.* Surgical treatment of pediatric hemifacial spasm patients. *Acta Neurochir (Wien)* 2011;153:1031-5.
 21. Chang JW, Chang JH, Park YG, Chung SS. Microvascular decompression of the facial nerve for hemifacial spasm in youth. *Childs Nerv Syst* 2001;17:309-12.
 22. Kobata H, Kondo A, Kinuta Y, Iwasaki K, Nishioka T, Hasegawa K, *et al.* Hemifacial spasm in childhood and adolescence. *Neurosurgery* 1995;36:710-4.
 23. Liang J, Guo Z, Zhang L, Yu Y. Adolescent-onset idiopathic hemifacial spasm. *Neurol India* 2014;62:175-7.
 24. Levy EI, Resnick DK, Jannetta PJ, Lovely T, Bissonette DJ. Pediatric hemifacial spasm: The efficacy of microvascular decompression. *Pediatr Neurosurg* 1997;27:238-41.
 25. Kamiguchi H, Ohira T, Ochiai M, Kawase T. Computed tomographic analysis of hemifacial spasm: Narrowing of the posterior fossa as a possible facilitating factor for neurovascular compression. *J Neurol Neurosurg Psychiatry* 1997;62:532-4.
 26. Felicio AC, de Godeiro C Jr., Borges V, de Azevedo Silva SM, Ferraz HB. Young onset hemifacial spasm in patients with Chiari type I malformation. *Parkinsonism Relat Disord* 2008;14:66-8.
 27. Mason WE, Kollros P, Jannetta PJ. Trigeminal neuralgia and its treatment in a 13-month-old child: A review and case report. *J Craniomandib Disord* 1991;5:213-6.
 28. Resnick DK, Levy EI, Jannetta PJ. Microvascular decompression for pediatric onset trigeminal neuralgia. *Neurosurgery* 1998;43:804-7.
 29. Matsushima T, Huynh-Le P, Miyazono M. Trigeminal neuralgia caused by venous compression. *Neurosurgery* 2004;55:334-7.
 30. Bahgat D, Ray DK, Raslan AM, McCartney S, Burchiel KJ. Trigeminal neuralgia in young adults. *J Neurosurg* 2011;114:1306-11.
 31. Bender MT, Pradilla G, James C, Raza S, Lim M, Carson BS, *et al.* Surgical treatment of pediatric trigeminal neuralgia: Case series and review of the literature. *Childs Nerv Syst* 2011;27:2123-9.
 32. Mousavi SH, Sekula RF, Gildengers A, Gardner P, Lunsford LD. Concomitant depression and anxiety negatively affect pain outcomes in surgically managed young patients with trigeminal neuralgia: Long-term clinical outcome. *Surg Neurol Int* 2016;7:98.
 33. Kondo A, Ishikawa J, Konishi T. The pathogenesis of hemifacial spasm: Characteristic changes of vasculature in vertebra-basilar artery system. In: Samii M, Jannetta PJ, editors. *The Cranial Nerves: Anatomy, Pathology, Pathophysiology, Diagnosis, Treatment*. Berlin: Springer-Verlag; 1987. p. 494-501.
 34. Pai BS, Varma RG, Kulkarni RN, Nirmala S, Manjunath LC, Rakshith S, *et al.* Microsurgical anatomy of the posterior circulation. *Neurol India* 2007;55:31-41.
 35. Wankhede HA, Hosmani PB, Nimje DA. Morphological study of the basilar artery in adult human cadavers. *Int J Anat Res* 2014;2:497-502.
 36. Saeki N, Rhoton AL Jr. Microsurgical anatomy of the upper basilar artery and the posterior circle of Willis. *J Neurosurg* 1997;46:563-78.
 37. Ohta M, Kobayashi M, Terano N, Wakiya K, Suzuki K, Fujimaki T, *et al.* Does arteriosclerosis contribute to hemifacial spasm? *Acta Neurochir (Wien)* 2016;158:181-7.
 38. Samii M, Günther T, Iaconetta G, Muehling M, Vorkapic P, Samii A, *et al.* Microvascular decompression to treat hemifacial spasm: Long-term results for a consecutive series of 143 patients. *Neurosurgery* 2002;50:712-8.
 39. Han IB, Chang JH, Chang JW, Huh R, Chung SS. Unusual causes and presentations of hemifacial spasm. *Neurosurgery* 2009;65:130-7.
 40. Sindou M, Leston J, Decullier E, Chapuis F. Microvascular decompression for primary trigeminal neuralgia: Long-term effectiveness and prognostic factors in a series of 362 consecutive patients with clear-cut neurovascular conflicts who underwent pure decompression. *J Neurosurg* 2007;107:1144-53.