

Local Balloon-Assisted Navigation of a Microcatheter into an Aneurysm during Intracranial Aneurysmal Coiling: A Dunk Shot Technique

Abstract

Objectives: Various endovascular approaches have been reported for patients with intracranial aneurysms. However, the safety of navigating a microcatheter into the aneurysm remains debatable. In this study, we evaluated a novel method “dunk shot technique,” in which a proximal balloon and a local balloon are used for navigation of a microcatheter into an aneurysm under challenging situations. **Materials and Methods:** We have reported two cases of unruptured internal carotid artery–superior hypothalamic artery aneurysm. An 8-F balloon-attached catheter was used as the guiding catheter. A local balloon catheter for neck remodeling and a microcatheter for coil insertion were navigated around the aneurysmal neck region. When it seemed difficult to navigate a microcatheter into an aneurysm, both the guiding balloon and a local balloon catheter were used for assistance. After inflation of the guiding balloon, the local balloon was inflated partially to negotiate the tip of the microcatheter. **Results:** The uncontrollable tip of the microcatheter could be intentionally moved by the local balloon. **Conclusions:** We evaluated the effectiveness of the balloon-assisted technique for the navigation of a microcatheter in cases with challenging anatomy. A little bit of direct effect to the tip of the microcatheter by a local balloon could produce effective outcomes under the proximal flow arrest.

Keywords: Balloon-assisted technique, catheterization, coil embolization, intracranial aneurysm

Introduction

Navigating a microcatheter into the aneurysm is necessary for successful coil embolization; however, it is often difficult because of the underlying anatomical condition. Rough manipulation may introduce a premature intraprocedural rupture that may prove fatal. We encountered two challenging anatomical conditions: one had a ledge effect due to distal aneurysmal neck, while another had a curved parent artery. Because we advanced the 8-F balloon-attached guiding catheter (BGC) for the treatment of all anterior circulation aneurysms, a local balloon could be inflated at the precise desired position under the proximal flow arrest by the BGC. Here, we have reported a novel technique that employed a proximal balloon and a local balloon for the navigation of a microcatheter into an aneurysm under challenging anatomical situations.

This is an open access journal, and articles are distributed under the terms of the Creative Commons Attribution-NonCommercial-ShareAlike 4.0 License, which allows others to remix, tweak, and build upon the work non-commercially, as long as appropriate credit is given and the new creations are licensed under the identical terms.

For reprints contact: WKHLRPMedknow_reprints@wolterskluwer.com

Case Report

Case 1

A previously healthy 62-year-old female was diagnosed with an unruptured right internal carotid artery (ICA)–superior hypothalamic artery aneurysm [Figure 1a]. The patient received an endovascular coil embolization under general anesthesia. An 8-F Optimo BGC (Tokai Medical Products, Aichi, Japan) was advanced into her right ICA via the right femoral artery. First, the Transform SC 4 × 7 Balloon Catheter (Stryker, Kalamazoo, MI, USA) was navigated around the aneurysmal neck region using the Chikai 14 Microguidewire (Asahi Intecc, Aichi, Japan). Next, the Phenom 17 Microcatheter (Medtronic, Irvine, CA, USA) was navigated into the aneurysm using the Traxess Microguidewire (Terumo, Tokyo, Japan). However, the tip of the Phenom 17 was prevented from navigation due to the ledge effect at the distal aneurysmal neck region [Figure 1b]. Therefore, we induced the

Tomotaka Ohshima¹,
Reo Kawaguchi²,
Naoki Matsuo²,
Shigeru Miyachi^{1,2}

¹Neuroendovascular Therapy Center, Aichi Medical University, ²Department of Neurosurgery, Aichi Medical University, Nagakute, Aichi, Japan

Address for correspondence:
Dr. Tomotaka Ohshima,
Neuroendovascular
Therapy Center, Aichi
Medical University, 1-1
Yazakokarimatoa, Nagakute
480-1195, Aichi, Japan.
E-mail: tmtkoh@gmail.com

Access this article online

Website: www.asianjns.org

DOI: 10.4103/ajns.AJNS_26_21

Quick Response Code:



How to cite this article: Ohshima T, Kawaguchi R, Matsuo N, Miyachi S. Local balloon-assisted navigation of a microcatheter into an aneurysm during intracranial aneurysmal coiling: A dunk shot technique. *Asian J Neurosurg* 2021;16:384-6.

Submitted: 19-Jan-2021

Revised: 19-Feb-2021

Accepted: 17-Mar-2021

Published: 28-May-2021

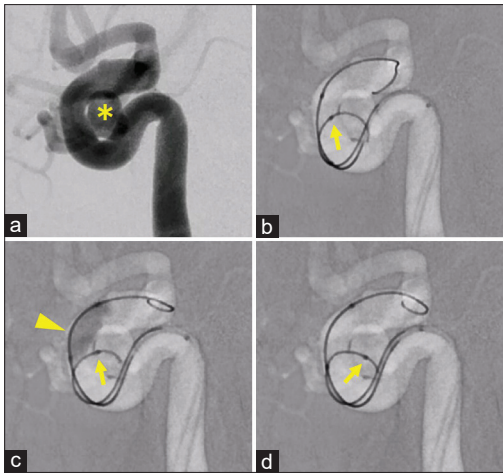


Figure 1: (a) An angiography of the working angle * Aneurysm (b) the tip of the microcatheter (arrow) could not exceed the distal aneurysmal neck portion due to the ledge effect between the microguidewire and the microcatheter. (c) After the balloon inflation (arrowhead), the tip of the microcatheter (arrow) could exceed the gap. (d) Finally, the tip of the microcatheter (arrow) could be navigated into the aneurysm

local balloon-assisted technique at this point. The proximal balloon of the BGC was inflated before the local balloon inflation. The local balloon was partially inflated from the distal side of the aneurysmal neck and then withdrawn [Figure 1c]. The tip of the microcatheter could be successfully navigated into the aneurysm [Figure 1d]. A schematic drawing of the technique is illustrated in Figure 2.

Case 2

A 54-year-old female was diagnosed with an unruptured left ICA–superior hypothalamic artery aneurysm [Figure 3a]. The patient received an endovascular coil embolization under general anesthesia. An 8-F Optimo BGC (Tokai Medical Products) was advanced into her left ICA via the right femoral artery. Next, the Scepter XC 4 × 11 Balloon Catheter (Terumo) was navigated around the aneurysmal neck with the Chikai 14 Microguidewire (Asahi Intecc). Then, the Phenom 17 Microcatheter (Medtronic), which was S-shaped, was navigated into the aneurysm using the Traxess Microguidewire (Terumo). However, the tip of the Phenom 17 faced the opposite direction toward the neck along with the curved parent artery. It could not be turned by controlling the microguidewire [Figure 3b]. Therefore, we induced the local balloon-assisted technique. The proximal balloon of the BGC was inflated before inflating the local balloon, and the local balloon was partially inflated at the aneurysmal neck position [Figure 3c]. As a result, the curvature of the microcatheter overturned and the tip became positioned facing the aneurysmal neck. Finally, the tip of the microcatheter could be navigated into the aneurysm [Figure 3d]. A schematic drawing of this technique is illustrated in Figure 4.

Discussion

Some past studies used the 8-F BGC and found it useful for coil embolizations.^[1-4] The main reason for using

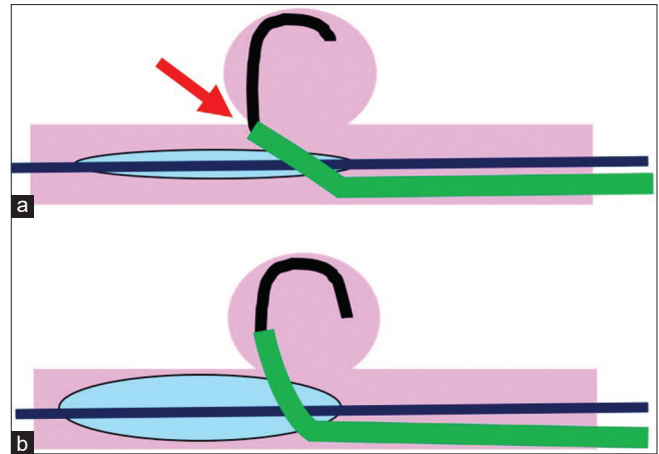


Figure 2: Schematic illustration of the local balloon-assisted technique in Case 1. (a) The arrow indicates the ledge effect between the wire and the catheter at the distal aneurysmal neck portion. (b) The expanded balloon allows the tip of the catheter to exceed the corner

the BGC was for insurance in case of an intraprocedural rupture of the aneurysm. Meanwhile, a blood flow control during coil deployment into the aneurysm was another benefit of using the 4th adjunctive technique, followed by balloon-assistance, stent-assistance, and a double-catheter technique.^[3] We believe that the temporary proximal flow arrest by the 8-F BGC functions to prevent excessive flow into the aneurysm when the local balloon is inflated at the distal portion from the aneurysmal neck region.

The uses of both the proximal and distal balloons during coil embolization have been reported. Ansari *et al.*^[4] reported that the proximal flow control was effective for subsequent accurate deployment of the local balloon. They reported a case of repeatedly ruptured, fragile, small ICA aneurysm. The aneurysm was successfully embolized using the double-balloon-trapping technique. In the local balloon-assisted technique used in the present case, there was no need for a full expansion of the distal balloon in comparison with that in the double-balloon-trapping technique.

Parasellar ICA aneurysms are often challenging to treat because the complicated shape of the microcatheter tip is occasionally required for the tortuous parent artery. In our country, a flow diverter is allowed to use only for a broad-necked aneurysm. A variety of microcatheter shaping methods including those under three-dimensional (3D) angiographic guidance, with the use of a 3D printer, and *in vivo* microcatheter printing method have been recently reported.^[5-7] However, even after the precise shaping is achieved, navigating the microcatheter remains challenging. Therefore, we considered that a little bit of direct touch with a microcatheter at the local site could be effective to assist its navigation into the aneurysm, such as by dunk shot of the basketball. We thought that this dunk shot technique was quite useful for the cases which required making a sharp-angled bent of the tip of the microcatheter [Figure 5].

However, the local balloon-assisted technique offers some disadvantages, and this study has some limitations. First,

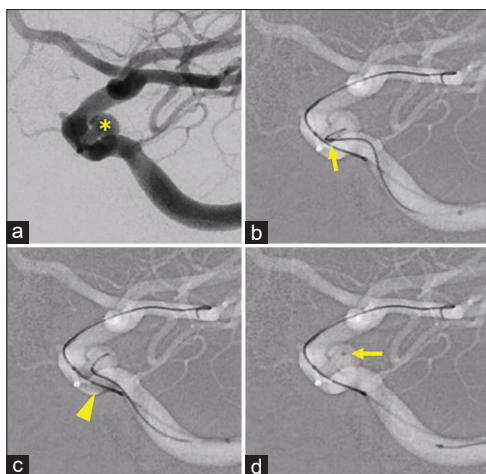


Figure 3: (a) An angiography of the working angle * Aneurysm (b) the tip of the microcatheter (arrow) could not face toward the aneurysm. (c) After the balloon inflation (arrowhead), the tip of the microcatheter could face toward the aneurysm. (d) Finally, the tip of the microcatheter (arrow) could be navigated into the aneurysm

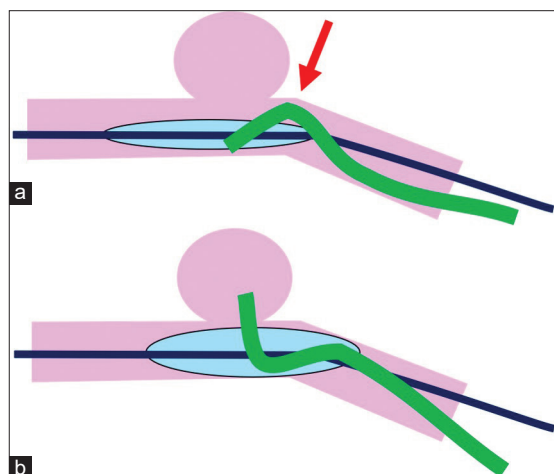


Figure 4: Schematic illustration of the local balloon-assisted technique in Case 2. (a) The bent microcatheter faced the opposite side of the aneurysm and fixed along with the curvature of the parent artery (arrow). (b) The expanded balloon allows the tip of the catheter to face the aneurysm

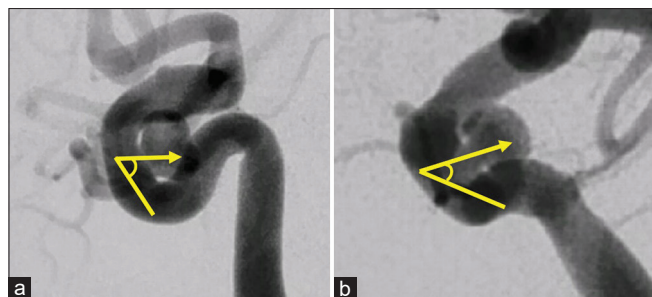


Figure 5: (a) An angiography of the working angle of the Case 1. Yellow lines indicate the ideal bent of the tip of the microcatheter. The subtended angle is 60 degrees. (b) An angiography of the working angle of the Case 2. Yellow lines indicate the ideal bent of the tip of the microcatheter. The subtended angle is 40°

this was a retrospective analysis conducted at a single center with only two cases. Second, the risk of thromboembolic events was greater with this technique than that with the conventional one. Stent-type devices such as Comaneci temporary embolization assist device (Rapid Medical, Yokneam, Israel) are not available in our country. Finally, this technique requires a more extensive caliber arterial sheath than the conventional technique. Thus, careful and secure hemostasis of the access site is mandatory in this situation.

Conclusions

We have reported the use of balloon-assisted technique for the navigation of a microcatheter in cases of challenging anatomy. A little bit of direct touch with a microcatheter at the local site was found to be effective in assisting its navigation into the aneurysm, such as a dunk shot of the basketball. The proximal flow control by BGC is important to advance an inflated local balloon to avoid excessive flow into the aneurysm when the local balloon is placed distal to the aneurysmal neck region.

Financial support and sponsorship

Nil.

Conflicts of interest

There are no conflicts of interest.

References

1. Tajima H, Ohshima T, Goto S, Yamamoto T, Shimato S, Nishizawa T, *et al.* Usefulness of the 8Fr Optimo as a guiding catheter during endovascular treatment for intracranial aneurysms: Original article. *J Neuroendovasc Ther* 2015;9:16-21.
2. Ohshima T, Dash C, Belayev A, Yamamoto T, Goto S, Kato Y. 8-F balloon guide catheter for embolization of anterior circulation aneurysms: An institutional experience in 152 patients. *Nagoya J Med Sci* 2017;79:435-41.
3. Ohshima T, Miyachi S, Matsuo N, Kawaguchi R, Niwa A, Maejima R, *et al.* Efficacy of the proximal balloon flow control method for endovascular coil embolisation as a novel adjunctive technique: A retrospective analysis. *Interv Neuroradiol* 2018;24:375-8.
4. Ansari A, Ohshima T, Goto S, Yamamoto T, Ishikawa K, Kato Y. Double-balloon trapping for coil embolization of ruptured internal carotid artery aneurysm: A novel technique. *Asian J Neurosurg* 2019;14:873-7.
5. Toyota S, Fujimoto Y, Iwamoto F, Wakayama A, Yoshimine T. Technique for shaping microcatheter tips in coil embolization of paraclinoid aneurysms using full-scale volume rendering images of 3D rotational angiography. *Minim Invasive Neurosurg* 2009;52:201-3.
6. Namba K, Higaki A, Kaneko N, Mashiko T, Nemoto S, Watanabe E. Microcatheter shaping for intracranial aneurysm coiling using the 3-dimensional printing rapid prototyping technology: Preliminary result in the first 10 consecutive cases. *World Neurosurg* 2015;84:178-86.
7. Ohshima T, Imai T, Goto S, Yamamoto T, Nishizawa T, Shimato S, *et al.* A novel technique of microcatheter shaping with cerebral aneurysmal coil embolization: *In vivo* printing method. *J Neuroendovasc Ther* 2017;11:48-52.