

# Endoscope-Assisted Microneurosurgery for Neurovascular Compression Syndromes: Basic Principles, Methodology, and Technical Notes

## Abstract

**Background:** Microscopic microvascular decompression (MVD) has a low but not negligible failure rate due to some missed conflicts, especially in case of multiple offending vessels. The reported study is aimed to assess the principles, methodology, technical notes, and effectiveness of the endoscope-assisted (EA) MVD for neurovascular compression syndromes (NVCS) in the posterior fossa. **Materials and Methods:** A series of 43 patients suffering from an NVCS and undergone to an EA MVD were retrospectively reviewed. Syndromes were trigeminal neuralgia in 25 cases, hemifacial spasm in nine cases, positional vertigo in six cases, glossopharyngeal neuralgia in two cases, and spasmodic torticollis in one case. In all cases, a 0°–30° specially designed endoscope was inserted into the surgical field to find/treat those conflicts missed by the microscopic exploration. Each procedure was judged in terms of the effectiveness of the adjunct of the endoscope according to a three types classification system: Type I – improvement in the visualization of the nerve's root entry/exit zone; Type II – endoscopic detection of one or more conflicts involving the ventral aspects of the nerve and missed by the microscope; Type III – endoscope-controlled release of the neurovascular conflict otherwise difficult to treat under the only microscopic view. **Results:** A total of 55 conflicts were found and treated. Twenty-eight procedures were classified as Type I, nine as Type II, and six as Type III. All the patients had a full recovery from their symptoms. **Conclusions:** In selected cases, EA MVD offers some advantages in the detection and treatment of neurovascular conflicts in the posterior fossa.

**Keywords:** Endoscope-assisted microneurosurgery, glossopharyngeal neuralgia, hemifacial spasm, microvascular decompression, trigeminal neuralgia

## Introduction

Posterior fossa microvascular decompression (MVD) is the most widely accepted surgical technique for the treatment of different neurovascular compression syndromes (NVCS). Its effectiveness has been recognized both for common syndromes, as trigeminal neuralgia (TN), hemifacial spasm (HFS), and glossopharyngeal neuralgia (GPN),<sup>[1-11]</sup> and for less common cranial nerve rhizopathies as disabling positional vertigo (PV) and spasmodic torticollis (ST).<sup>[12-20]</sup>

Although historically based on the employment of the microscope,<sup>[5,6,8]</sup> MVD technique has been enhanced over the years by the integration with the endoscope in the so-called endoscope-assisted (EA) microneurosurgery.<sup>[12-14,16,17,21-26]</sup> Basically, EA MVD arises from a combined

microscopic and endoscopic approach where the microscope provides a direct illumination and magnification of the superficial aspects of the surgical field and the endoscope allows for a clearer visualization of very deep-seated neurovascular structures. EA procedures also exploit all the advantages the endoscope offers in “looking around the corner,” although the surgical maneuvers are however performed under a pure microscopic control. Rarely, some benefits can be obtained in the performing the release of the conflict in an endoscope-controlled mode.

The avoidance of the cerebellar retraction constitutes one of the main strengths of EA-MVD technique. EA-MVD technique appears therefore to be able to provide for some theoretical advantages in neurovascular compression rhizopathies.

The present study aims to review the basic principles, methodology, and technical

Sabino Luzzi<sup>1</sup>,  
Mattia Del Maestro<sup>2</sup>,  
Donatella  
Trovarelli<sup>3</sup>,  
Danilo De Paulis<sup>1</sup>,  
Soheila Raysi  
Dechordi<sup>1</sup>,  
Hambra Di  
Vitantonio<sup>1</sup>,  
Valerio Di Norcia<sup>1</sup>,  
Daniele Francesco  
Millimaggi<sup>1</sup>,  
Alessandro Ricci<sup>1</sup>,  
Renato Juan  
Galzio<sup>1,2</sup>

Departments of <sup>1</sup>Neurosurgery  
and <sup>3</sup>Anesthesiology, San  
Salvatore City Hospital,  
<sup>2</sup>Department of Life,  
Health and Environmental  
Sciences (MESVA), University of  
L'Aquila, L'Aquila, Italy

## Address for correspondence:

Dr. Sabino Luzzi,  
Neurosurgery Unit,  
"San Salvatore" City Hospital,  
P.zza Salvatore Tommasi 1,  
67100, L'Aquila, Italy.  
E-mail: sabino.luzzi@gmail.com

## Access this article online

Website: [www.asianjns.org](http://www.asianjns.org)

DOI: 10.4103/ajns.AJNS\_279\_17

## Quick Response Code:



**How to cite this article:** Luzzi S, Del Maestro M, Trovarelli D, De Paulis D, Dechordi SR, Di Vitantonio H, et al. Endoscope-assisted microneurosurgery for neurovascular compression syndromes: Basic principles, methodology, and technical notes. Asian J Neurosurg 2019;14:193-200.

This is an open access journal, and articles are distributed under the terms of the Creative Commons Attribution-NonCommercial-ShareAlike 4.0 License, which allows others to remix, tweak, and build upon the work non-commercially, as long as appropriate credit is given and the new creations are licensed under the identical terms.

For reprints contact: [reprints@medknow.com](mailto:reprints@medknow.com)

notes of EA MVD, as well as its usefulness, reliability, and feasibility in the treatment of several types of neurovascular conflicts causing NVCS in the posterior fossa.

## Materials and Methods

### Patient population

The charts, clinical notes, and videos of a 10-year consecutive series of 43 patients (23 males and 20 females; age ranging between 22 and 77 years [mean 57]) undergone to an MVD because of an NVCS were retrospectively reviewed. Patients who harbored a hybrid NVCS involving more than a single cranial nerve were excluded from the review. According to the classification scheme proposed by Burchiel<sup>[27,28]</sup> TN was classified in Type I, shock-like pain, and Type II, constant pain.

Preoperatively, all the patients were undergone to T1–T2 magnetic resonance imaging (MRI), three-dimensional (3D) constructive interference in steady-state MRI, and time-of-flight MR angiography to study the course of the cranial nerve and to identify the neurovascular conflict. All the procedures were performed by the same surgeon (RJG).

### Technical notes of endoscope-assisted microvascular decompression

The retrosigmoid approach was performed always with the patient in a modified park-bench position. A tailored navigation-guided craniotomy, ranging between 20 mm and 25 mm in diameter, was sufficient in all cases apart from those conflicts involving the vertebral artery, where a more generous bony removal was necessary to achieve a full mobilization of the offending artery. In HFSs, intraoperative neurophysiological monitoring of the facial nerve, consisting in a free-running electromyography, was conducted.

A generous cerebrospinal fluid release under microscopic view was paramount to avoid cerebellar retraction and mechanical stress to the cranial nerves in their cisternal segment. No rigid retractors were used. Dynamic retraction technique, by means of suction tube, cottonoids, and bipolar were performed to obtain the retraction of the cerebellar hemisphere and to access to the cerebellopontine angle (CPA) and adjacent areas. After the first microscopic inspection and microneurolysis of the arachnoid bands around the target nerve, the endoscope was introduced into the operative field under microscopic control to avoid contact injuries to the neurovascular structures. The visualization of the neurovascular conflict and the surgical maneuvers were executed under a simultaneous microscopic-endoscopic view.

Two types of endoscopes were employed: A 0° straight-forward telescope and a 30° forward-oblique telescope with a downward or upward view direction (Karl Storz GmbH and Co. KG, Tuttlingen, Germany, Hopkins Galzio Endoscope). Outer diameter was 2.7 mm

and working length 15 cm for both endoscopes. Endoscopes had a 45° angled eyepiece aimed to avoid the encroachment with the line of sight of the microscope [Figure 1]. Light power of the endoscope never exceeded 15% to avoid thermal injuries to the nerves. Microscope's light source offered the background lighting of the surgical field. Microscopic and endoscopic images were simultaneously viewed picture-in-picture on a 7-inch high-resolution liquid crystal display (LCD) monitor mounted on the microscope's headpiece [Figure 2]. A 21-inch LCD external monitor of the endoscope offered a further source of view. The smaller LCD monitor attached to the microscope allowed to alternate microscopic and endoscopic view by means of a simple gaze movement [Figure 3]. The 0° and 30° endoscopes were used sequentially in all cases to achieve a circumferential 360° inspection of the entire length of the nerve also in those cases where at least one conflict had already been found through the microscopic exploration. In selected cases, the endoscope was fixed to a dedicated mechanical holder attached to the operative table and the surgical maneuvers were performed under a simultaneous microscopic-endoscopic view. Seldom and in selected cases, MVD was performed solely under the endoscopic control (endoscope-controlled MVD). A small graft of autologous muscle between the offending artery and the involved nerve was used in all cases to release the conflict.

### The assessment of the usefulness of endoscope-assisted microvascular decompression

Each procedure was judged in terms of the usefulness of the adjunct of the endoscope according to a three types classification system: Type I – improvement in the

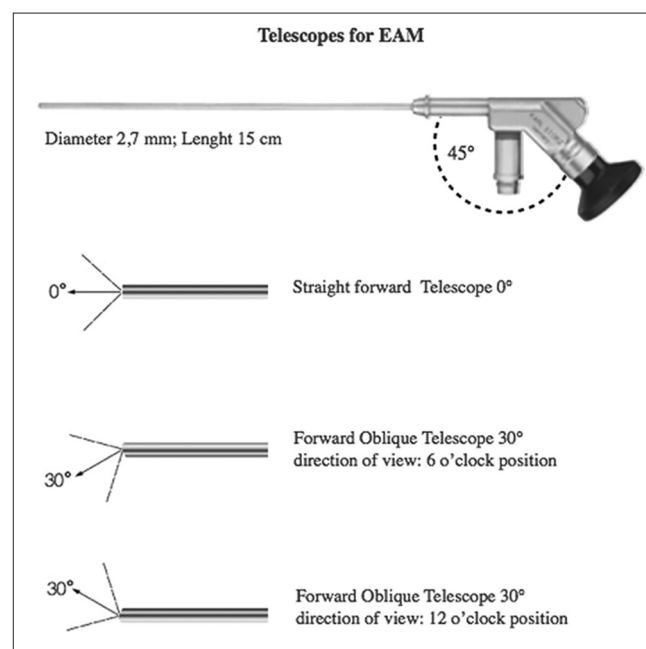


Figure 1: Endoscopes designed by the senior author (RJG) for endoscope-assisted microneurosurgery

visualization of the nerve's root entry/exit zone (REZ); Type II – endoscopic detection of one or more conflicts involving the ventral aspects of the nerve and missed by the microscope; Type III – endoscope-controlled release of the neurovascular conflict otherwise difficult to treat under the pure microscopic view [Table 1]. The criterion of objectivity in the evaluation of the usefulness of endoscopic use consisted in the assessment of the number of treated cases, in which at the end of the microscopic inspection and after it has not allowed the finding or adequate treatment of the conflict, the addition of the endoscope was essential in achieving the primary goal of the surgery. Basically, Type I was assigned to those procedures where the endoscope allowed only a better understanding of the local anatomy, but where, however, the adjunct of the endoscope was not essential. Type II procedures were those where the endoscope permitted the identification of one or more conflicts that certainly or most probably would have been missed, by means of the microscopic exploration alone, because hidden or deep-seated. In these cases, MVD was performed under a microscopic view, the endoscope being only a tool through which to reach an exhaustive inspection of the nerve in its entire length and circumference. Type III was reserved to the endoscope-controlled procedures, in which MVD would never have been satisfactory or complete if not performed under a pure endoscopic view. Type II and III procedures were those where the employment of the endoscope was objectively essential to achieve the MVD.

## Results

Twenty-five patients were diagnosed with a TN, nine patients with an HFS, six patients with a disabling PV, two patients with a GPN, and one patient with an ST [Graph 1]. Fifty-five conflicts in 43 patients were found

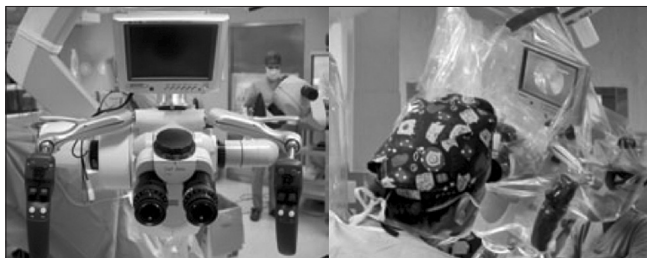

Figure 2: Seven-inch high-resolution liquid crystal display monitor mounted on the microscope's headpiece

and released. Forty-three conflicts were single (78%), whereas 12 were multiple (22%) sustained by more than a single offending vessel [Graph 2]. Twenty-two patients suffered from a Type I TN, whereas three patients had a Type II neuralgia. None of the patients with TN underwent other surgical treatments before MVD. Among HFSs, seven patients showed with a typical presentation with initial twitching starting in the orbicularis muscle and gradually progressing caudally, and two had an atypical pattern of onset consisting in an initial twitching starting in the buccal muscles and going rostrally [Table 2].

Anterior inferior cerebellar artery (AICA) was involved in 24 cases, superior cerebellar artery (SCA) in 21 cases, posterior inferior cerebellar artery (PICA) in five cases, and vertebral artery in two cases. In three cases, the conflict was venous by an ectatic Dandy's vein (DV) causing a TN [Graph 3]. In no cases, the superior petrosal vein was sacrificed. All the patients suffering from TN experienced a complete recovery from their symptoms without (22 cases) or with (3 cases) medication. A complete resolution of the twitching was observed in all cases of HFS. An excellent outcome, characterized by an early pain relief, was achieved in all GPN. The same early recovery occurred in PVs. The unique case of ST had a residual mechanical impairment.

Two patients suffered by a cerebrospinal fluid leak as a complication of surgery. Both cases were treated successfully by means of a lumbar drain placed on the second postoperative day and maintained for 3 days in the first case and 5 days in the second patient.

Twenty-eight procedures (65%) were classified as Grade I, 9 (21%) as Grade II, and 6 as Grade III (14%) [Graph 4].

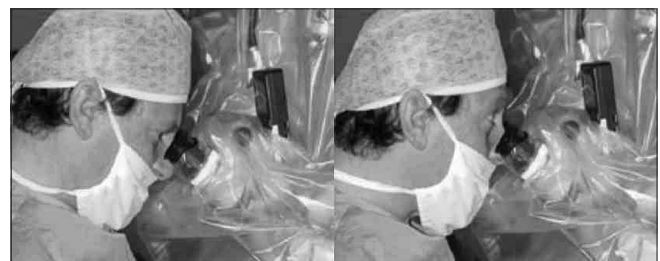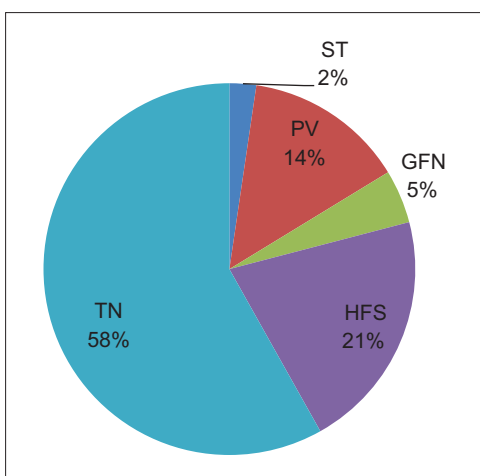


Figure 3: Surgeon's gaze movement during endoscope-assisted microvascular decompression allowing to alternate microscopic and endoscopic view

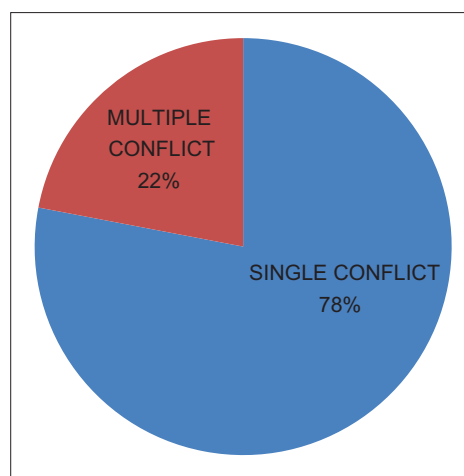
**Table 1: Classification system for the evaluation of the effectiveness of the adjunct of the endoscope to the microscopic microvascular decompression**

Type	Effectiveness of the endoscope assistance to the microscopic MVD		
	Improvement in the visualization of the nerve at REZ	Endoscopic detection of the conflicts missed by the microscope	Endoscope-controlled release of the conflict otherwise difficult to treat under the microscopic view
Type I	Yes	No	No
Type II	Yes	Yes	No
Type III	Yes	Yes	Yes

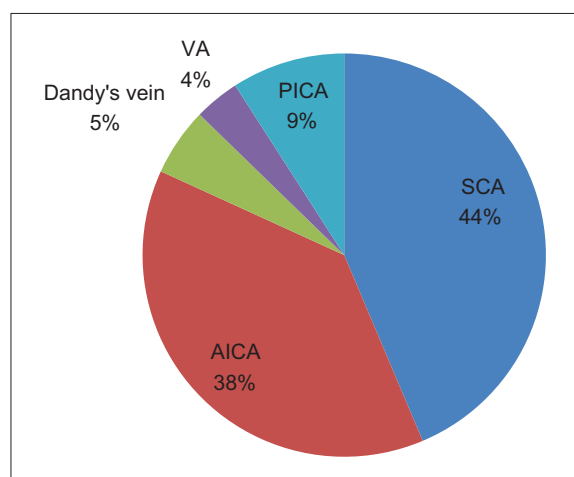
MVD – Microvascular decompression; REZ – Nerve's root entry/exit zone



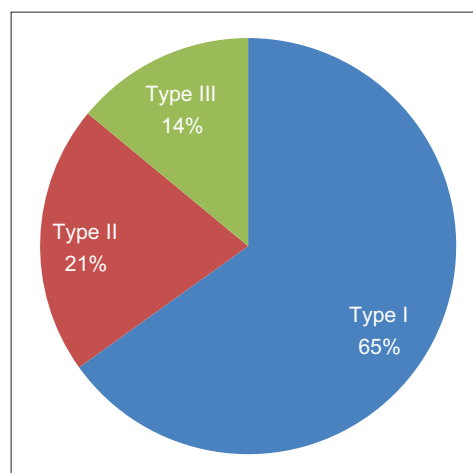
Graph 1: Pie graph showing the percentage of representativity of the different neurovascular compression syndromes in the present series. TN – Trigeminal neuralgia; HFS – Hemifacial spasm; GPN – Glossopharyngeal neuralgia; PV – Positional vertigo; ST – Spasmodic torticollis



Graph 2: Pie graph showing the overall percentage of single and multiple neurovascular conflicts in the present series



Graph 3: Pie graph showing the percentage of involvement of the different offending vessels in the present series



Graph 4: Pie graph showing the overall percentages of types assigned to each procedure according to the proposed classification system about the utility of endoscope adjunct to the microscopic microvascular decompression

## Illustrative cases

### Case 1

A 57-year-old male diagnosed with a Type I TN due to a double neurovascular conflict involving the left trigeminal nerve [Figure 4]. Microscopic exploration allowed to detect the first conflict by an extremely tortuous AICA at the inferior aspect of the trigeminal nerve and a second conflict by SCA at the upper aspect of the nerve. Both conflicts were easily released under microscopic view, but after the upward transposition of SCA, the endoscopic assistance allowed to immediately appreciate a further hidden conflict by a duplication of SCA at REZ. In the present case, the endoscopic assistance was also useful to assess the adequacy of MVD. The procedure was classified as Type II.

### Case 2

A 48-year-old female diagnosed with a severe, typical, right HFS. Intraoperatively, the microscopic exploration

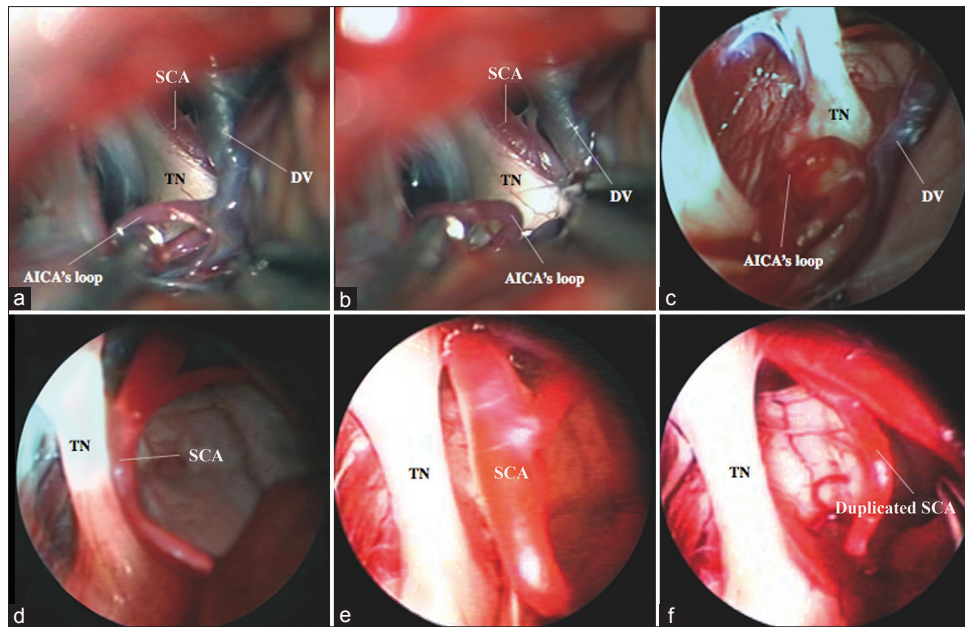
Table 2: Types of neurovascular compression syndromes in the reported series

Neurovascular compression syndrome		n
Type	Subtype	
TN	Type I	22
	Type II	3
HFS	Typical	7
	Atypical	2
PV		6
GPN		2
ST		1

TN – Trigeminal neuralgia; HFS – Hemifacial spasm; PV – Positional vertigo; GPN – Glossopharyngeal neuralgia; ST – Spasmodic torticollis

allowed only a very limited view of the right facial nerve at REZ, in the absence of a rigid retraction and the conflict caused by the high-riding PICA was only supposed. Endoscopic exploration with a 30° endoscope highlighted





**Figure 4:** Illustrative case 1. 57-year-old male diagnosed with a Type I left trigeminal neuralgia. Microscopic exploration showing a double neurovascular conflict involving the left trigeminal nerve by anterior inferior cerebellar artery and superior cerebellar artery. (a and b) Endoscopic assistance allowed to inspect clearly the inferior aspect (c) and the superior aspect (d and e) of the nerve at root entry/exit zone and to detect a further hidden conflict by a duplication of superior cerebellar artery at root entry/exit zone (f). The endoscopic assistance was also useful to assess the adequacy of microvascular decompression. The procedure was classified as Type II. DV – Dandy's vein

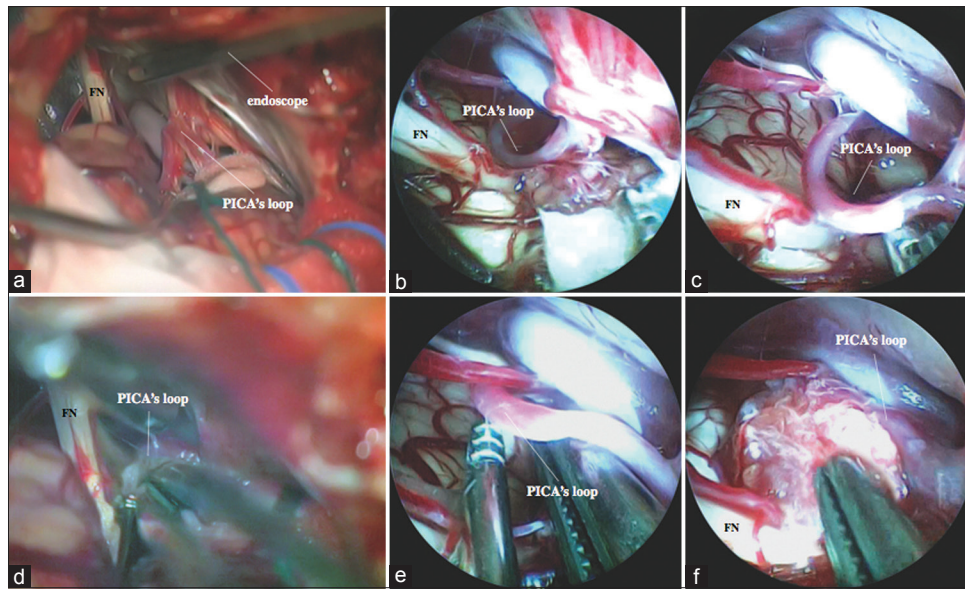
clearly the encroachment of the facial nerve at REZ by the cranial loop of PICA, leading to avoid completely any rigid retraction of the cerebellar hemisphere [Figure 5]. Note that the light output of the endoscope was set at a 5% of the maximum power. Ultimately, the detection of the neurovascular conflict was endoscopic. The procedure was classified as Type II.

## Discussion

MVD is a well-established and effective treatment for many cranial nerves rhizopathies. According to the historical and widely confirmed theory proposed by Jannetta, it does exist at least one conflict underlying each TN.<sup>[5,6,8,29]</sup> The same concept also applies for other NVCS within the posterior fossa. Based on these evidence, the identification and release of all the putative neurovascular conflicts at the base of each syndrome is paramount to achieve the best patient's outcome. In large series, the failure rate related to the conventional MVD for TN ranges between 12% and 34%.<sup>[2,3,30]</sup> We speculate that most of these cases, ultimately resulting in a poor outcome, are due to missing conflicts, especially at REZ. Although MVD is classically executed under microscopic view, many works have demonstrated an additional accuracy up to 80% of the endoscope-assistance of MVD.<sup>[13,15,16,21,22,31-36]</sup> It seems to be particularly useful for less common compression syndromes as disabling PV and GPN. In 1993, Perneckzy popularizes the use of the endoscope in neurosurgery by introducing the concept of "minimally invasive key-hole approach"<sup>[24,25]</sup> and in 1994, Magnan first reported a case of HFS treated with a combined microscopic-endoscopic approach.<sup>[15,16]</sup> In 2002,

Jarrahay *et al.* reported the first case of a fully endoscopic MVD in a TN case who had an excellent outcome.<sup>[23]</sup>

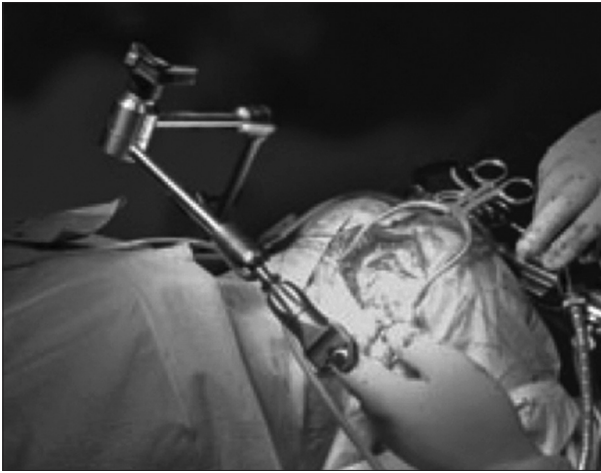The personal authors' experience proved that, in selected cases, EA MVD is an extremely useful and reliable technique to identify and manage the neurovascular conflicts, especially if multiple because sustained by more than a single offending vessel. Often, these vessels are duplicated or fenestrated. EA MVD is very effective also in assessing the adequacy of decompression. Based on the reported classification system, 9 procedures out of 43 (21%) were classified as Type II and 6 (14%) as Type III. It means that in a 35% of the treated cases, the adjunct of the endoscope to the classic microscopic MVD was very useful to detect or even to treat the conflict in the posterior fossa. Furthermore, 21% of the overall number of conflicts probably would have been even missed without endoscopic inspection. The line of sight of the microscope consists in a 270° view limited to the superior, posterior, and inferior aspect of the nerve; moreover, difficult to achieve at REZ if not in the presence of an unattractive cerebellar retraction. On the other hand, as widely proven and reported in literature, the compression by the offending vessel can occur anywhere around the circumference and anywhere along the length of the nerve.<sup>[26,37]</sup> The adjunct of the 0° and 30° endoscopic view contributes to overcome some limits of the pure microscopic view, ultimately transforming the 270° view of the microscope into a 360° view around the whole circumference of the nerve. Furthermore, the endoscope allows for an easier visualization of the cranial nerves at REZ, where classically both arteries and veins can create the conflict.<sup>[32,38]</sup> All



**Figure 5: Illustrative case 2.** 48-year-old female diagnosed with a right hemifacial spasm. Microscopic exploration allowed a limited view of facial nerve at root entry/exit zone (a) Endoscopic exploration with a 30° endoscope showed the encroachment of the facial nerve at REZ by the cranial loop of posterior-inferior cerebellar artery. (b and c) Rigid retraction of the cerebellar hemisphere was completely avoided. Endoscope-assisted microvascular decompression of the conflict. (d-f) The procedure was classified as Type II. FN – facial nerve

these aspects imply that EA MVD offers the advantages of a lesser or no need for cerebellar retraction, which is associated in turn with the most serious morbidities as cerebellar hemorrhage, infarction, swelling, and hearing loss.<sup>[1,2,26,30,36,39]</sup> Far from least, the keyhole concept of Perneczky is applicable to MVD also. The endoscope allows to reach very easily all the areas of the surgical field in depth, regardless of the size of the craniotomy. Indeed, in the authors' experience, the diameter of the retrosigmoid craniotomy has been continuously reduced up to no  $\geq 25$  mm over the years. Some potential risks of mechanical or thermal injury to the cranial nerves or other critical neurovascular structures have been associated with the use of the endoscope.<sup>[30,32,36]</sup> With the aim to decrease the risk of mechanical injury, in the authors' technical note, the endoscope is introduced and shifted into the operative field always under a direct microscopic view and coaxially with the line of sight of the microscope. The combined microscopic-endoscopic view, exploiting the background illumination of the microscope's light beam, allows to set at a very low output the light intensity of the endoscope, thus limiting the risk of thermal injury also. Most of the authors have emphasized the need for a dedicated instrumentation for EA MVD.<sup>[22,23,30,32,36,37,40]</sup> Since 2002, a dedicated system of endoscopes and mechanical holders, designed by the senior author (RJG), has been introduced in our institution. One of the most common problems of EA procedures is the partial obstruction of the microscopic view caused by the camera head. This problem, strictly related to the use of conventional endoscopes, is particularly evident during the rotation of the instrument aimed to obtain different visual perspectives. To avoid this limitation of the surgical view, the authors have developed a specific type of endoscope

with an eyepiece angled at 45°, so that the camera head remains out of the surgical field [Figure 1]. Furthermore, the 45° angled design of the eyepiece resulted very ergonomic during surgery, ultimately allowing for a quick and effective adjustment of the endoscope according to the needs of the surgeon. The system also includes a mechanical holder which allows for a precise and nontraumatic fixation of the endoscope to the operative table [Figure 6]. A further problem raised by different authors concerns the difficulty in sharing microscopic and endoscopic view.<sup>[30,32,36]</sup> As reported in the present technical note, this problem can be partially overcome thanks to the screen above the microscope. In fact, a simple gaze upward movement by the surgeon can allow to obtain easily a combined microscopic-endoscopic view [Figure 3]. Furthermore, while the microscope offers a 3D view giving a wider sense of depth, the endoscope allows a two-dimensional view limited in depth. With the progressive implementation and spread of 3D endoscopes, this discomfort will be further minimized. Although ultimately performed under a pure endoscopic view, endoscope-controlled procedures and fully endoscopic procedures are however quite different. Fully-endoscopic MVD involves that the endoscope is introduced through minimal "key-hole" approaches, which are even smaller than the retrosigmoid minicraniotomy performed in the present series, light source has to be set at medium/high output power, and the instrument must be held by the assistant surgeon or by a holder. Some authors reported the successes of a fully endoscopic MVD for NVCS in the CPA.<sup>[12,15,16,22,29,30,40]</sup> We believe that, for the aforementioned risks of mechanical and thermal injuries, the fully endoscopic MVD may be dangerous, beyond difficult in some cases, especially because the endoscopic



**Figure 6: Mechanical holder for endoscope-assisted microneurosurgery**

light beam power causes an excessive local heating when used at medium-to-high output.<sup>[1,30,32,36]</sup>

Unfortunately, despite the large improvement of the modern neuroimaging techniques, it is still difficult, in the preoperative planning, to anticipate exactly where the main conflict responsible for the symptoms will be found around the nerve. It follows that there are no strict preoperative selection criteria for EA MVD, apart from those cases of multiple symptoms (e.g., symptoms attributable to the involvement of more than a single trigeminal division). According to their personal experience, the authors suggest to perform EA MVD in all cases where, intraoperatively, the conflict results apparently absent or not clear by means of the conventional microscopic exploration which, as general rule, must always involve the entire length of the nerve from the REZ to the distal cisternal part. Furthermore, the endoscopic inspection is advised in the presence of anatomic variations of the offending vessels (e.g., duplicated SCA).

Rather than a novel surgical technique, EA MVD has to be considered a technical variation of the conventional microscopic MVD where some not negligible advantages of the endoscopic view are exploited to maximize the effectiveness of the standard and well-established microscopic technique. EA MVD decreases the need for a rigid cerebellar retraction and diminishes the false negatives of the technique due to the missed conflicts.

## Conclusion

EA-MVD technique appears therefore to be able to provide for some theoretical advantages in neurovascular compression rhizopathies

## Consent

Informed consent was obtained from all individual participants included in the study.

## Declaration of patient consent

The authors certify that they have obtained all appropriate patient consent forms. In the form, the patient(s) has/have given his/her/their consent for his/her/their images and other clinical information to be reported in the journal. The patients understand that their names and initials will not be published and due efforts will be made to conceal their identity, but anonymity cannot be guaranteed.

## Financial support and sponsorship

Nil.

## Conflicts of interest

There are no conflicts of interest.

## References

1. Barker FG, Jannetta PJ, Bissonette DJ, Larkins M V, Jho HD. The long-term outcome of microvascular decompression for trigeminal neuralgia. *N Engl J Med* [Internet] 1996;334:1077-83. Available from: <http://www.ncbi.nlm.nih.gov/pubmed/8598865>.
2. Bederson JB, Wilson CB. Evaluation of microvascular decompression and partial sensory rhizotomy in 252 cases of trigeminal neuralgia. *J Neurosurg* [Internet] 1989;71:359-67. Available from: <http://www.ncbi.nlm.nih.gov/pubmed/2769387>.
3. Broggi G, Ferroli P, Franzini A, Servello D, Dones I. Microvascular decompression for trigeminal neuralgia: comments on a series of 250 cases, including 10 patients with multiple sclerosis. *J Neurol Neurosurg Psychiatry* [Internet] 2000;68:59-64. Available from: <http://www.ncbi.nlm.nih.gov/pubmed/10601403>.
4. Hitotsumatsu T, Matsushima T, Inoue T. Microvascular decompression for treatment of trigeminal neuralgia, hemifacial spasm, and glossopharyngeal neuralgia: Three surgical approach variations: technical note. *Neurosurgery* [Internet] 2003;53:1436-41; discussion 1442-3. Available from: <http://www.ncbi.nlm.nih.gov/pubmed/14633313>.
5. Jannetta PJ. Arterial compression of the trigeminal nerve at the pons in patients with trigeminal neuralgia. *J Neurosurg* [Internet] 1967;26:Suppl:159-62. Available from: <http://www.ncbi.nlm.nih.gov/pubmed/6018932>.
6. Jannetta PJ, Abbasy M, Maroon JC, Ramos FM, Albin MS. Etiology and definitive microsurgical treatment of hemifacial spasm. Operative techniques and results in 47 patients. *J Neurosurg* [Internet] 1977;47:321-8. Available from: <http://www.ncbi.nlm.nih.gov/pubmed/894338>.
7. Kondo A. Follow-up results of microvascular decompression in trigeminal neuralgia and hemifacial spasm. *Neurosurgery* [Internet] 1997;40:46-51; discussion 51-2. Available from: <http://www.ncbi.nlm.nih.gov/pubmed/8971823>.
8. McLaughlin MR, Jannetta PJ, Clyde BL, Subach BR, Comey CH, Resnick DK. Microvascular decompression of cranial nerves: lessons learned after 4400 operations. *J Neurosurg* [Internet] 1999;90:1-8. Available from: <http://www.ncbi.nlm.nih.gov/pubmed/10413149>.
9. Sindou M, Leston J, Decullier E, Chapuis F. Microvascular decompression for primary trigeminal neuralgia: long-term effectiveness and prognostic factors in a series of 362 consecutive patients with clear-cut neurovascular conflicts who underwent pure decompression. *J Neurosurg* [Internet] 2007;107:1144-53. Available from: <http://www.ncbi.nlm.nih.gov/pubmed/18077952>.
10. Tronnier VM, Rasche D, Hamer J, Kienle AL, Kunze S.



- Treatment of idiopathic trigeminal neuralgia: comparison of long-term outcome after radiofrequency rhizotomy and microvascular decompression. *Neurosurgery* [Internet] 2001;48:1261-7; discussion 1267-8. Available from: <http://www.ncbi.nlm.nih.gov/pubmed/11383728>.
11. Zakrzewska JM, Lopez BC, Kim SE, Coakham HB. Patient reports of satisfaction after microvascular decompression and partial sensory rhizotomy for trigeminal neuralgia. *Neurosurgery* [Internet] 2005;56:1304-11; discussion 1311-2. Available from: <http://www.ncbi.nlm.nih.gov/pubmed/15918947>.
  12. Abdeen K, Kato Y, Kiya N, Yoshida K, Kanno T. Neuroendoscopy in microvascular decompression for trigeminal neuralgia and hemifacial spasm: technical note. *Neurol Res* [Internet] 2000;22:522-6. Available from: <http://www.ncbi.nlm.nih.gov/pubmed/10935228>.
  13. Fries G, Pernecky A. Endoscope-assisted brain surgery: part 2--analysis of 380 procedures. *Neurosurgery* [Internet] 1998;42:226-31; discussion 231-2. Available from: <http://www.ncbi.nlm.nih.gov/pubmed/9482172>.
  14. Fukushima T. Endoscopy of Meckel's cave, cisterna magna, and cerebellopontine angle. Technical note. *J Neurosurg* [Internet] 1978;48:302-6. Available from: <http://www.ncbi.nlm.nih.gov/pubmed/304887>.
  15. Magnan J, Caces F, Locatelli P, Chays A. Hemifacial spasm: Endoscopic vascular decompression. *Otolaryngol Head Neck Surg* [Internet] 1997;117:308-14. Available from: <http://www.ncbi.nlm.nih.gov/pubmed/9339788>.
  16. Magnan J, Chays A, Caces F, Lepetre-Gillot C, Cohen JM, Belus JF, *et al.* [Role of endoscopy and vascular decompression in the treatment of hemifacial spasm]. *Ann Otolaryngol Chir Cervicofac* [Internet] 1994;111:153-60. Available from: <http://www.ncbi.nlm.nih.gov/pubmed/7840488>.
  17. De Ridder D, Møller A, Verlooy J, Cornelissen M, De Ridder L. Is the root entry/exit zone important in microvascular compression syndromes? *Neurosurgery* [Internet] 2002;51:427-33; discussion 433-4. Available from: <http://www.ncbi.nlm.nih.gov/pubmed/12182781>.
  18. Samii M, Günther T, Iaconetta G, Muehling M, Vorkapic P, Samii A. Microvascular decompression to treat hemifacial spasm: long-term results for a consecutive series of 143 patients. *Neurosurgery* [Internet] 2002;50:712-8; discussion 718-9. Available from: <http://www.ncbi.nlm.nih.gov/pubmed/11904020>.
  19. Shin JC, Chung UH, Kim YC, Park CI. Prospective study of microvascular decompression in hemifacial spasm. *Neurosurgery* [Internet] 1997;40:7.
  20. Sun K, Lu Y, Hu G, Luo C, Hou L, Chen J, *et al.* Microvascular decompression of the accessory nerve for treatment of spasmodic torticollis: Early results in 12 cases. *Acta Neurochir (Wien)* 2009;151:1251-7.
  21. Badr-El-Dine M, El-Garem HF, Talaat AM, Magnan J. Endoscopically assisted minimally invasive microvascular decompression of hemifacial spasm. *Otol Neurotol* 2002;23:122-8.
  22. Jarrahy R, Berci G, Shahinian HK. Endoscope-assisted microvascular decompression of the trigeminal nerve. *Otolaryngol Head Neck Surg* 2000;123:218-23.
  23. Jarrahy R, Eby JB, Cha ST, Shahinian HK. Fully endoscopic vascular decompression of the trigeminal nerve. *Minim Invasive Neurosurg* 2002;45:32-5.
  24. Pernecky A, Boecher-Schwarz HG. Endoscope-assisted microsurgery for cerebral aneurysms. *Neurol Med Chir (Tokyo)* 1998;38:33-4.
  25. Pernecky A, Fries G. Endoscope-assisted brain surgery: Part 1 – Evolution, basic concept, and current technique. *Neurosurgery* 1998;42:219-24.
  26. Teo C, Nakaji P, Mobbs RJ. Endoscope-assisted microvascular decompression for trigeminal neuralgia: Technical case report. *Neurosurgery* 2006;59:ONSE489-90.
  27. Burchiel KJ. A new classification for facial pain. *Neurosurgery* 2003;53:1164-6.
  28. Miller JP, Acar F, Burchiel KJ. Classification of trigeminal neuralgia: Clinical, therapeutic, and prognostic implications in a series of 144 patients undergoing microvascular decompression. *J Neurosurg* 2009;111:1231-4.
  29. Artz GJ, Hux FJ, Larouere MJ, Bojrab DI, Babu S, Pieper DR, *et al.* Endoscopic vascular decompression. *Otol Neurotol* 2008;29:995-1000.
  30. Cheng WY, Chao SC, Shen CC. Endoscopic microvascular decompression of the hemifacial spasm. *Surg Neurol* 2008;70 Suppl 1:40-6.
  31. Caces F, Chays A, Locatelli P, Bruzzo M, Epron JP, Fiacre E, *et al.* Neuro-vascular decompression in hemifacial spasm: Anatomical, electrophysiological and therapeutic results apropos of 100 cases. *Rev Laryngol Otol Rhinol (Bord)* 1996;117:347-51.
  32. El-Garem HF, Badr-El-Dine M, Talaat AM, Magnan J. Endoscopy as a tool in minimally invasive trigeminal neuralgia surgery. *Otol Neurotol* 2002;23:132-5.
  33. Kaye AH, Adams CB. Hemifacial spasm: A long term follow-up of patients treated by posterior fossa surgery and facial nerve wrapping. *J Neurol Neurosurg Psychiatry* 1981;44:1100-3.
  34. King WA, Wackym PA, Sen C, Meyer GA, Shiau J, Deutsch H, *et al.* Adjunctive use of endoscopy during posterior fossa surgery to treat cranial neuropathies. *Neurosurgery* 2001;49:108-15.
  35. Lovely TJ, Jannetta PJ. Microvascular decompression for trigeminal neuralgia. Surgical technique and long-term results. *Neurosurg Clin N Am* 1997;8:11-29.
  36. Rak R, Sekhar LN, Stimac D, Hechl P. Endoscope-assisted microsurgery for microvascular compression syndromes. *Neurosurgery* 2004;54:876-81.
  37. Lee SH, Levy EI, Scarrow AM, Kassam A, Jannetta PJ. Recurrent trigeminal neuralgia attributable to veins after microvascular decompression. *Neurosurgery* 2000;46:356-61.
  38. Chen MJ, Zhang WJ, Yang C, Wu YQ, Zhang ZY, Wang Y, *et al.* Endoscopic neurovascular perspective in microvascular decompression of trigeminal neuralgia. *J Craniomaxillofac Surg* 2008;36:456-61.
  39. Fritz W, Schäfer J, Klein HJ. Hearing loss after microvascular decompression for trigeminal neuralgia. *J Neurosurg* 1988;69:367-70.
  40. Kabil MS, Eby JB, Shahinian HK. Endoscopic vascular decompression versus microvascular decompression of the trigeminal nerve. *Minim Invasive Neurosurg* 2005;48:207-12.