

Spontaneous Disappearance of an Intracranial Small Unruptured Aneurysm on Magnetic Resonance Angiography: Report of Two Cases

Abstract

Spontaneous radiographic disappearance of cerebral aneurysms is often observed under special conditions such as giant aneurysms. However, spontaneous disappearance of an unruptured and nongiant intracranial saccular aneurysms is rare. We describe two cases of this rare vascular phenomenon. The first patient is a 64-year-old female diagnosed with a small unruptured aneurysm arising from the distal anterior cerebral artery. Spontaneous disappearance of the aneurysm on magnetic resonance angiography (MRA) was observed 5 years after the initial diagnosis. Continuous imaging surveillance also revealed spontaneous reappearance of the aneurysm 2 years later. The second patient is a 57-year-old female harboring a small unruptured saccular aneurysm arising from the M1–M2 bifurcation of the middle cerebral artery. The aneurysm showed spontaneous disappearance on MRA 13 years after the initial diagnosis. These cases provide a new insight into this natural dynamic process even in cases of a small unruptured intracranial saccular aneurysm.

Keywords: Spontaneous disappearance, thrombosis, unruptured cerebral aneurysm

Introduction

Saccular intracranial aneurysms can often have a variable degree of thrombosis. Although spontaneous thrombosis including partial thrombosis in giant aneurysms is a relatively common vascular event,^[1-3] the occurrence of this phenomenon in nongiant saccular aneurysms is rarely reported.^[4-6] Here, we report two cases of a small unruptured saccular aneurysm showing a radiographic spontaneous disappearance and present a brief literature review related to these cases.

Case Reports

Case 1

A 64-year-old female visited our hospital for a brain checkup in November, 2011. An aneurysm located at the left distal anterior cerebral artery was found on magnetic resonance angiography (MRA) [Figure 1a]. Three-dimensional computed tomography (CT) angiography performed at the same time showed no vessel stenosis around the aneurysm [Figure 2]. The size of the aneurysm was 4.9 mm in diameter. Laboratory tests revealed no abnormalities,

including those of the coagulation system. Follow-up MRA, conducted every 6 months, showed no remarkable change of the aneurysm for 3.5 years after the initial diagnosis. MRA performed 4 years after the initial diagnosis showed a slight reduction in the aneurysm size [Figure 1b]. The aneurysm completely disappeared the following year [Figure 1c]. MRA performed 2 years after the disappearance of the aneurysm showed a recurrence at the same site [Figure 1d]. MRA performed 1 year after the recurrence showed a slight enlargement of the aneurysm [Figure 1e].

Case 2

A 57-year-old female visited our hospital for a brain checkup in October, 2006. A saccular aneurysm located at M1–M2 bifurcation of the right middle cerebral artery was found on MRA [Figure 3a]. The size of the aneurysm was 2.4 mm in diameter. Laboratory tests revealed no abnormalities including those of the coagulation system. Follow-up MRA, conducted once a year, showed no remarkable change for 11 years [Figure 3b], but showed spontaneous disappearance of

**Yu Akimoto,
Kiyoyuki Yanaka,
Kuniyuki Onuma,
Kazuhiro Nakamura,
Nobuyuki
Takahashi¹,
Eiichi Ishikawa²**

Departments of Neurosurgery and ¹Radiology, Tsukuba Memorial Hospital, ²Department of Neurosurgery, Institute of Clinical Medicine, University of Tsukuba, Tsukuba, Ibaraki, Japan

Address for correspondence:

*Dr. Eiichi Ishikawa,
Department of Neurosurgery,
Institute of Clinical Medicine,
University of Tsukuba,
1-1-1 Tennodai, Tsukuba,
Ibaraki 305-8575, Japan.
E-mail: e-ishikawa@md.tsukuba.ac.jp*

Access this article online

Website: www.asianjns.org

DOI: 10.4103/ajns.AJNS_281_20

Quick Response Code:



This is an open access journal, and articles are distributed under the terms of the Creative Commons Attribution-NonCommercial-ShareAlike 4.0 License, which allows others to remix, tweak, and build upon the work non-commercially, as long as appropriate credit is given and the new creations are licensed under the identical terms.

For reprints contact: WKHLRPMedknow_reprints@wolterskluwer.com

How to cite this article: Akimoto Y, Yanaka K, Onuma K, Nakamura K, Takahashi N, Ishikawa E. Spontaneous disappearance of an intracranial small unruptured aneurysm on magnetic resonance angiography: Report of two cases. *Asian J Neurosurg* 2020;15:1055-8.

Submitted: 07-Jun-2020

Revised: 03-Jul-2020

Accepted: 13-Jul-2020

Published: 19-Oct-2020

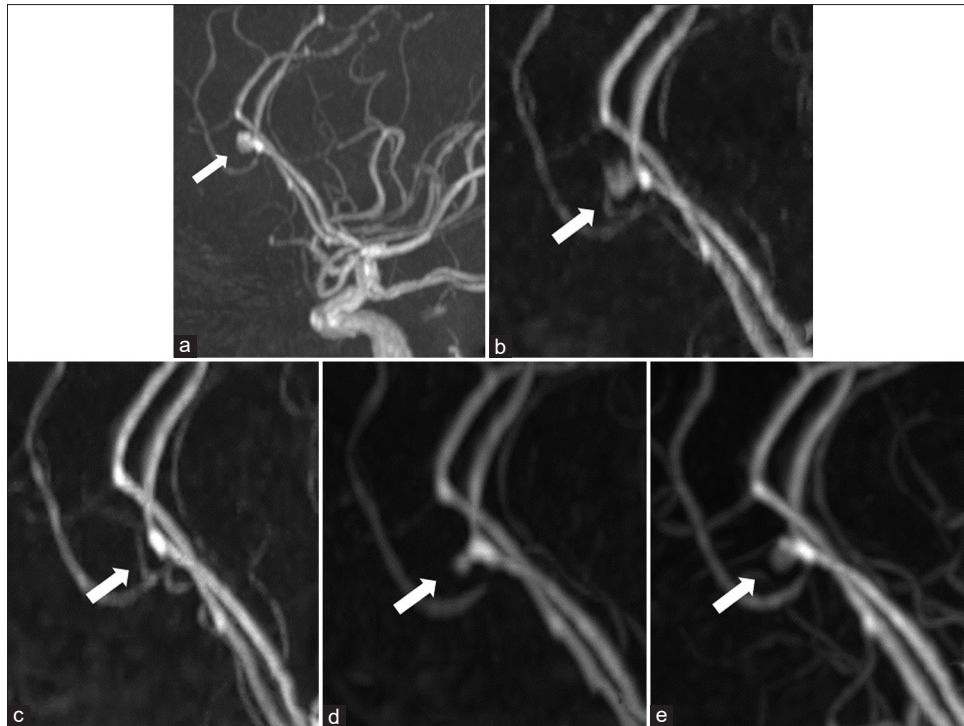


Figure 1: (a) Magnetic resonance imaging at first examination showing a small unruptured aneurysm (arrow) arising from the distal anterior cerebral artery. (b) Magnetic resonance imaging performed 4 years after the initial diagnosis showing a slight reduction in aneurysm size. (c) Magnetic resonance imaging performed 5 years after the initial diagnosis showing complete disappearance of the aneurysm. (d) Magnetic resonance imaging performed 2 years after disappearance showing spontaneous recanalization of the aneurysm. (e) Magnetic resonance imaging performed 1 year after recanalization showing a slight enlargement of the aneurysm

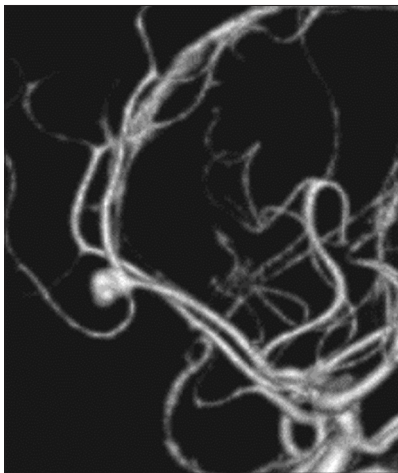


Figure 2: Three-dimensional computed tomography angiography performed at the initial diagnosis showing no vessel stenosis around the aneurysm

the aneurysm 13 years after the initial diagnosis [Figure 3c]. Further radiographic follow-up is planned.

Discussion

Spontaneous radiographic disappearance of intracranial aneurysms has been reported to occur under special conditions including postsubarachnoid hemorrhage aneurysms,^[7] giant/fusiform aneurysms,^[8] dissecting aneurysms,^[9] mycotic aneurysms,^[10] neoplastic aneurysms,^[11] traumatic aneurysms,^[12] aneurysms associated

with moyamoya disease^[13] or arteriovenous malformation,^[14] aneurysms associated with the parent artery occlusion,^[8] and aneurysms associated with surgical interventions.^[15] Intimal repair around the aneurysm can occur in a small number of cases,^[10,11,13,14] but the major etiology of this phenomenon is thought to be spontaneous intra-aneurysmal thrombosis. It is common in giant intracranial aneurysms, occurring in approximately 50% of cases.^[16] The natural history of intracranial aneurysms is a dynamic process thought to be governed by a delicate balance between thrombogenesis and thrombolysis. The exact mechanism behind the intra-aneurysmal thrombosis is unknown, but the turbulent blood flow within an aneurysm is a well-known fact, which can account for complete or partial thrombosis of the aneurysm, together with endothelial injury. Despite the fact that spontaneous thrombosis is more frequently associated with giant rather than nongiant aneurysms,^[3] the latter comprise the majority of cerebral ischemia cases related to unruptured aneurysms.^[17] Therefore, spontaneous thrombosis occurring in a small unruptured aneurysm may be tightly related with a radiologic disappearance.

Spontaneous radiologic disappearance or reduction in size of a small unruptured saccular aneurysm was reported to be rare. To the best of our knowledge, only five cases^[4-6] including ours have been reported previously [Table 1]. The average age at initial diagnosis was 62.6 years and all aneurysms were located in the anterior cerebral circulation.

Table 1: Summary of cases showing spontaneous disappearance of a small unruptured aneurysm

Author (year)	Age/Sex	Location	Size (mm)	Interval to disappearance (year)	Note
Yamada Y (2010)	70/F	ICA	3	2	
Choi CY (2012)	69/M	MCA	4.5	3	Partial disappearance
Yokota S (2020)	53/F	ICA	4	12	
Present Case 1	64/F	distal ACA	4.9	5	Recurrence
Present Case 2	57/F	MCA	2.4	13	

ACA - Anterior cerebral artery; F- Female; ICA- Internal cerebral artery; M- Male; MCA- Middle cerebral artery

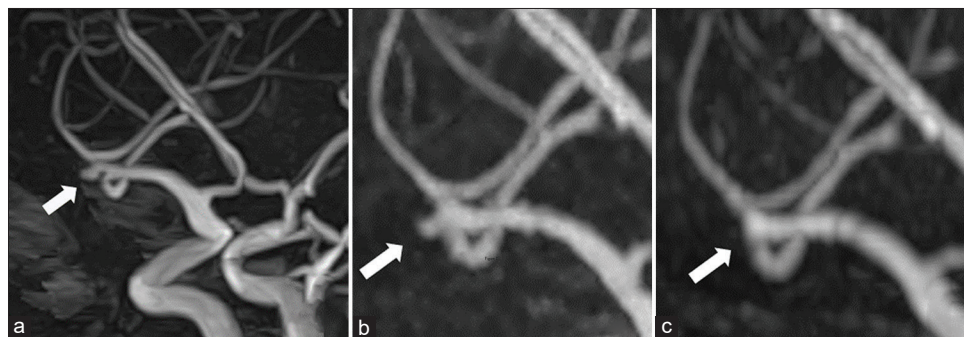


Figure 3: (a) Magnetic resonance imaging at first examination showing a small unruptured aneurysm (arrow) arising from the bifurcation of the middle cerebral artery. (b) Magnetic resonance imaging performed 11 years after the initial diagnosis showing unremarkable change of the aneurysm size. (c) Magnetic resonance imaging performed 13 years after the initial diagnosis showing complete disappearance of the aneurysm

The average size of the aneurysms was 3.8 mm in diameter. All cases showed a spontaneous disappearance or reduction in size on MRA or CT angiography without any intervention; the mean interval between the initial diagnosis and the radiographic disappearance was 7.0 years. The first case (case 1) of those presented is the initial case to show spontaneous radiographic disappearance and is also followed by spontaneous reappearance of a small unruptured saccular aneurysm.

In current clinical practice, most patients with small unruptured saccular aneurysms are managed conservatively. However, as in our first case, even radiologically occult aneurysms have a risk of recanalization and of possible future rupture. Therefore, this observation should be kept in mind, and strict and vigilant radiographic follow-up is essential, even in patients with small unruptured saccular aneurysms.

Conclusion

We report two cases of small unruptured saccular aneurysms showing spontaneous disappearance on MRA; one showed a spontaneous disappearance also followed by spontaneous reappearance on MRA. Therefore, even radiologically disappeared small unruptured aneurysms still have a risk of recanalization and of possible future rupture. Strict follow-up including serial imaging examinations is required.

Declaration of patient consent

The authors certify that they have obtained all appropriate patient consent forms. In the form, the legal guardian has

given his consent for images and other clinical information to be reported in the journal. The guardian understands that names and initials will not be published and due efforts will be made to conceal identity, but anonymity cannot be guaranteed.

Acknowledgments

The authors thank Dr. Alexander Zaboronok, Department of Neurosurgery, and Thomas Mayers of the Medical English Communications Center of the Faculty of Medicine, University of Tsukuba, for manuscript revision.

Financial support and sponsorship

Nil.

Conflicts of interest

There are no conflicts of interest.

References

- de Aguiar GB, Pagotto MV, Conti ML, Veiga JC. Spontaneous thrombosis of giant intracranial aneurysm and posterior cerebral artery followed by also spontaneous recanalization. *Surg Neurol Int* 2016;7:15.
- Atkinson JL, Lane JI, Colbassani HJ, Llewellyn DM. Spontaneous thrombosis of posterior cerebral artery aneurysm with angiographic reappearance. Case report. *J Neurosurg* 1993;79:434-7.
- Brownlee RD, Tranmer BI, Sevick RJ, Karmy G, Curry BJ. Spontaneous thrombosis of an unruptured anterior communicating artery aneurysm. An unusual cause of ischemic stroke. *Stroke* 1995;26:1945-9.
- Choi CY, Han SR, Yee GT, Lee CH. Spontaneous regression of an unruptured and non-giant intracranial aneurysm. *J Korean Neurosurg Soc* 2012;52:243-5.

5. Yamada Y, Kinjo T, Ohki M, Kayama T. Spontaneous thrombosis of an unruptured internal carotid artery aneurysm: A case report. *Surg Cereb Strok* 2010;38:114-8.
6. Yokoya S, Hino A, Oka H. Rare spontaneous disappearance of intracranial aneurysm. *World Neurosurg* 2020;134:452-3.
7. Little AS, Garrett M, Germain R, Farhataziz N, Albuquerque FC, McDougall CG, *et al.* Evaluation of patients with spontaneous subarachnoid hemorrhage and negative angiography. *Neurosurgery* 2007;61:1139-50.
8. Kondo A, Yasuhara T, Sugi K, Ohmoto T. Spontaneous thrombosis of a fusiform aneurysm arising from the distal posterior cerebral artery: Case report. *No Shinkei Geka* 2003;31:189-93.
9. Zhang YS, Wang S, Wang Y, Tian ZB, Liu J, Wang K, *et al.* Treatment for spontaneous intracranial dissecting aneurysms in childhood: A retrospective study of 26 cases. *Front Neurol* 2016;7:224.
10. Allen LM, Fowler AM, Walker C, Derdeyn CP, Nguyen BV, Hasso AN, *et al.* Retrospective review of cerebral mycotic aneurysms in 26 patients: Focus on treatment in strongly immunocompromised patients with a brief literature review. *AJNR Am J Neuroradiol* 2013;34:823-7.
11. Huang Y, Chen J, Wang J. Intracranial aneurysm disappeared after resection of a cardiac myxoma. *Int J Clin Exp Med* 2015;8:8214-7.
12. Morón F, Benndorf G, Akpek S, Dempsy R, Strother CM. Spontaneous thrombosis of a traumatic posterior cerebral artery aneurysm in a child. *AJNR Am J Neuroradiol* 2005;26:58-60.
13. Peltier J, Vinchon M, Soto-Ares G, Dhellemmes P. Disappearance of a middle cerebral artery aneurysm associated with Moyamoya syndrome after revascularization in a child: Case report. *Childs Nerv Syst* 2008;24:1483-7.
14. Hodozuka A, Sako K, Yonemasu Y, Suzuki N, Fujita T, Ohgami S. Spontaneous disappearance of aneurysm after total removal of accompanying intracranial arteriovenous malformation. Case report. *Neurol Med Chir (Tokyo)* 1991;31:966-71.
15. Pop R, Chibarro S, Manisor M, Proust F, Beaujeux R. Spontaneous thrombosis of a basilar tip aneurysm after ventriculoperitoneal shunting. *BMJ Case Rep* 2015;2015:bcr2015011841.
16. Whittle IR, Dorsch NW, Besser M. Spontaneous thrombosis in giant intracranial aneurysms. *J Neurol Neurosurg Psychiatry* 1982;45:1040-7.
17. Calviere L, Viguier A, Da Silva NA Jr., Cognard C, Larrue V. Unruptured intracranial aneurysm as a cause of cerebral ischemia. *Clin Neurol Neurosurg* 2011;113:28-33.