

## A 5-Year Follow-up of Intracranial Arterial Dolichoectasia: A Case Report and Review of Literature

### Abstract

A patient with multiple dolichoectasia of the intracranial cerebral artery was followed sequentially with clinical and radiological progression of disease in the past 5 years. The patient was treated in multiple stages in the past 5 years with the endovascular and microsurgical clipping method. The maximum diameter of each major intracranial artery segment was recorded and compared in the follow-up year. The progression in size of the dolichoectatic segment was observed in spite of surgical intervention. In review diagnostic criteria, etiopathogenesis and treatment options have been discussed.

**Keywords:** Follow-up, intracranial artery dolichoectasia, pathogenesis, rare, treatment option

### Introduction

The word dolichoectasia is derived from Greek words “dolicos” and “ectasis” which means abnormally long and dilate, respectively.<sup>[1]</sup> Many terms have been used to describe this arteriopathy (e.g., mega artery, mega dolichol artery, fusiform aneurysm, cirroid aneurysm, and serpentine aneurysm). The prevalence of intracranial dolichoectasia was reported 0.1%–6.5% in the general population<sup>[2]</sup> and about 12% among stroke patients.<sup>[3]</sup> The risk factors associated with dolichoectasia are old age, hypertension, and male gender.<sup>[4,5]</sup> The hereditary conditions including Marfan syndrome, Ehlers–Danlos syndrome Type IV, pseudoxanthoma elasticum, Fabry disease, Pompe diseases, neurofibromatosis Type I, tuberous sclerosis, moyamoya diseases, autosomal dominant polycystic kidney diseases, fibromuscular dysplasia, and acquired immune deficiency syndrome.<sup>[6,7]</sup> The dolichoectasia can cause a transient ischemic attack, ischemic or hemorrhagic stroke, and compressive symptoms of the surrounding structure.<sup>[5,8]</sup> An aortic aneurysm, saccular aneurysm, and coronary artery disease<sup>[9]</sup> may coexist with intracranial dolichoectasia. The dolichoectatic artery lack definite neck and this make it difficult to treat surgically. Till date, little is known about its natural

course and prognosis. In this article, we have been tried to present the radiological course, treatment options, and outcome of one dolichoectatic patient with a review of the literature.

### Case Report

A 40-year-old male patient came to our hospital in 2014 with multiple intracranial artery dolichoectasia. It was diagnosed as an incidental finding on radiological examination of the patient. The patient had a history of coiling of the left cavernous internal carotid artery (ICA) aneurysm, which was done outside of our hospital. The patient had a history of systemic hypertension, and he was a chronic smoker. The computed tomography (CT) angiography findings in the year 2014 were, dilated and tortuous right supraclinoid ICA, fusiform dilated M1 segment of right and left middle cerebral artery (MCA) [Figure 1a], fusiform dilated segment of the right posterior communicating artery (PCOM), P2 segment of right posterior cerebral artery (PCA) and left vertebral artery [Figure 2a]. On the left vertebral artery, two fusiform aneurysm was present, out of which one was located at the level of posterior inferior cerebellar artery origin and the second one just distal to its origin [Figure 2a]. The largest size of fusiform aneurysm segment was present in the right M1 MCA

**Lavlesh Rathore,  
Yashiro Yamada<sup>1</sup>,  
Tsukasa Kawase<sup>1</sup>,  
Yoko Kato<sup>1</sup>,  
Satya Bhusan  
Senapati<sup>2</sup>**

*Department of Neurosurgery,  
Shri Balaji Institute of Medical  
Sciences, Raipur, Chhattisgarh,  
<sup>2</sup>Department of Neurosurgery,  
SMIMS, Gangtok, Sikkim, India,  
<sup>1</sup>Department of Neurosurgery,  
Banbuntane Hotokukai Hospital,  
Fujita Health University,  
Nagoya, Japan*

**Address for correspondence:**  
Dr. Lavlesh Rathore,  
Shri Balaji Institute of Medical  
Sciences, Raipur - 492 001,  
Chhattisgarh, India.  
E-mail: lavleshrathore06@  
gmail.com

#### Access this article online

**Website:** www.asianjns.org

**DOI:** 10.4103/ajns.AJNS\_282\_18

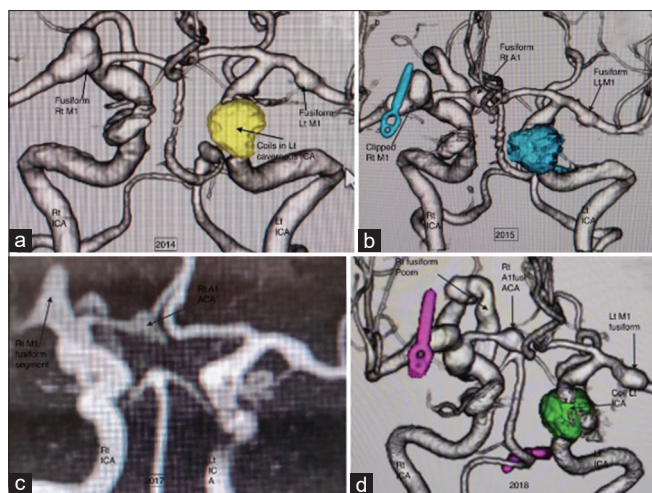
#### Quick Response Code:



**How to cite this article:** Rathore L, Yamada Y, Kawase T, Kato Y, Senapati SB. A 5-year follow-up of intracranial arterial dolichoectasia: A case report and review of literature. Asian J Neurosurg 2019;14:1302-7.

This is an open access journal, and articles are distributed under the terms of the Creative Commons Attribution-NonCommercial-ShareAlike 4.0 License, which allows others to remix, tweak, and build upon the work non-commercially, as long as appropriate credit is given and the new creations are licensed under the identical terms.

**For reprints contact:** reprints@medknow.com



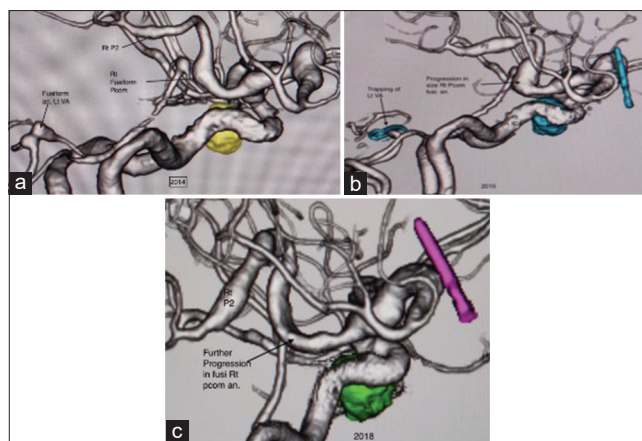
**Figure 1:** (a) 2014 computed tomography angiography anteroposterior view showing coiling in left cavernous internal carotid artery segment and fusiform aneurysm in the right and left M1 middle cerebral artery segment. (b) In 2015 new fusiform aneurysm segment in right A1 anterior cerebral artery. (c) Magnetic resonance imaging angiography in 2017 showing further progression in size of right M1 middle cerebral artery fusiform segment. (d) 2018 computed tomography angiography showing further progression in the fusiform segment of left M1 middle cerebral artery, right internal carotid artery, right posterior communicating artery, and P2 posterior cerebral artery

segment (size – 7.3 mm), so clipping of an aneurysm was done to prevent future risk of rupture on the year 2014. Then, on the next stage procedure, trapping of left vertebral artery fusiform aneurysm segment was done, as its morphology was not suitable for the endovascular procedure [Figure 2b]. The patient was advised to stop smoking and regular antihypertensive medicine.

On follow-up CT angiography of the patient in the year 2015, a new fusiform aneurysmal dilated segment was observed on the distal A1 segment of right anterior cerebral artery (ACA) [Figure 1b]. The maximum diameter of the fusiform segment of the right ICA, M1 segment of the right MCA, PCOM, and P2 segment of Posterior cerebral artery (PCA) had been increased from previous follow-up image [Table 1]. In the year 2016, the left cavernous ICA aneurysm refilling was observed, so again repacking of the coil was done. On CT head, no infarction and hemorrhage were observed and patient advice to continue follow-up.

In the year 2017, magnetic resonance imaging (MRI) angiography was done, which showed further increase in size of the fusiform dilated segment of right M1 MCA and right PCOM [Figure 1c] as compared to previous cerebral angiography in the year 2015 [Table 1]. The contrast enhancement was noted in the wall of fusiform aneurysm segment of the right A1 ACA on MRI examination, which may be due to increased dilated vasa vasorum on the wall of an aneurysm [Figure 3].

On the next follow-up CT angiography in the year 2018, size of the fusiform segment of right ICA,



**Figure 2:** (a) Lateral view computed tomography angiography 2014 showing fusiform right posterior communicating artery segment up to P2 posterior cerebral artery segment with fusiform left vertebral artery aneurysm. (b) 2015 computed tomography angiography showing trapped segment of left vertebral artery. (c) In 2018 showing a further increase in size and extent of the dolichoectatic segment of right posterior communicating artery

**Table 1: Measurement of right intracranial artery**

Right intracranial artery	2014	2015	2017	2018
ICA (mm)	5.7	6	6.6	7.5
M1 MCA (mm)	7.3	10	11.3	8.5
A1 ACA (mm)	2.6	5.4	5.4	5.7
PCOM (mm)	3.5	6.7	7	7.2
P1 PCA (mm)	0.7	1.7	2.1	2.2
P2 PCA (mm)	2.6	4.3	4.5	5.3
BA (mm)	2.2	2.3	2.3	2.4

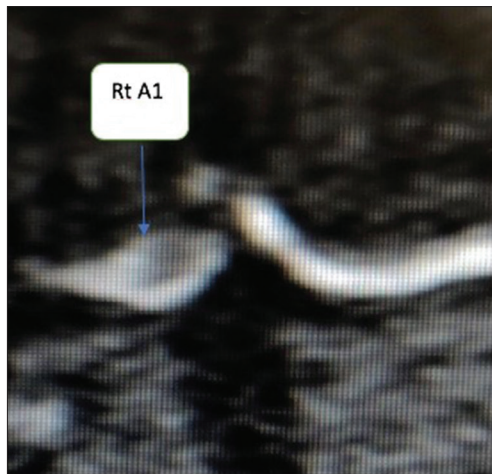ICA – Internal carotid artery; MCA – Middle cerebral artery; ACA – Anterior cerebral artery; PCOM – Posterior communicating artery; BA – Basilar artery; PCA – Posterior cerebral artery

**Table 2: Measurement of left intracranial artery**

Left intracranial artery	2014	2015	2017	2018
ICA (mm)	4.8	5.7	5.7	6
M1 MCA (mm)	3.3	3.6	4.7	5.4
A1 ACA (mm)	1.9	2.3	2.3	2.3
PCOM (mm)	1.3	1.3	2.4	2.4
P1 PCA (mm)	0.9	0.9	1	1
P2 PCA (mm)	1.5	2.4	2.4	2.5

ICA – Internal carotid artery; MCA – Middle cerebral artery; ACA – Anterior cerebral artery; PCOM – Posterior communicating artery; PCA – Posterior cerebral artery

PCOM and A1 ACA was further increased slightly from previous cerebral angiography in the year 2017 [Table 1, Figures 1d and 2c]. However, the right MCA fusiform aneurysmal segment size was decreased slightly on CT angiography, which may be due to thrombosis in the aneurysmal sac [Figure 1d]. On sequential follow-up cerebral angiography, size of the fusiform segment of left M1 MCA was increased from 3.3 mm in the year 2014 to 5.4 mm in the year 2018 [Table 2]. The computational fluid dynamic (CFD) study was done in the year 2018 on left M1 MCA fusiform aneurysm



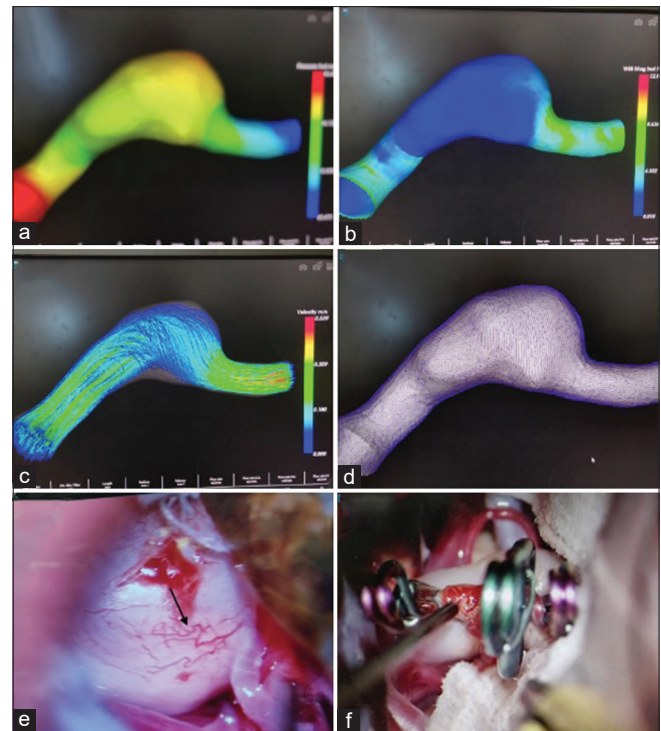
**Figure 3:** Contrast magnetic resonance imaging brain showing contrast enhancement on the wall of fusiform aneurysm segment of the right A1 anterior cerebral artery (blue arrow)

segment, which showed wall pressure high and wall shear stress low [Figure 4a and b]. The streamline was showing slow flow on the dome [Figure 4c], and the vector was convergent in proximal fusiform aneurysm segment of left M1 MCA [Figure 4d]. As CFD analysis was showing a risk of impending rupture on fusiform aneurysm segment of left M1 MCA, so clipping of an aneurysm was done in the year 2018 with preserving parent artery [Figure 4f]. Intraoperatively numerous dilated vasa vasorum was observed in the fusiform segment of left M1 MCA aneurysm [Figure 4e]. Till date, no hemorrhage and infarction were observed.

## Discussion

### Definition and diagnostic criteria

Intracranial arterial dolichoectasia describes the presence of at least one ectatic or enlarged artery in the cerebral vasculature.<sup>[10]</sup> The diffuse intracranial arterial dolichoectasia defined by the involvement of two or more cerebral vessel and had been suggested with poorer natural history.<sup>[11]</sup> A fusiform aneurysm is a form of nonsaccular arterial dilatation for short segment of the wall as compared to dolichoectasia which involve a long segment of the vessel wall.<sup>[12]</sup> The irregular arterial course in the supraclinoid segment of internal carotid artery, anterior cerebral artery, MCA and PCA is determined by a visual assessment based on compression of surrounding structure and tortuosity of the vessel when compared to the contralateral side.<sup>[13]</sup> The smoker and colleagues [Table 3] recommended a cutoff of 4.5 mm diameter at the level of mid pons to define basilar artery ectasia.<sup>[14]</sup> The Passero and Rossi have suggested cutoff's diameter for internal carotid ( $\geq 7$  mm), MCA ( $\geq 4$  mm), and vertebral artery ( $\geq 4$  mm) to indicate ectasia.<sup>[5]</sup>



**Figure 4:** (a) Showing wall pressure high on the fusiform segment. (b) Wall shear stress low. (c) Streamline showing slow flow on the dome of fusiform aneurysm. (d) Vectors are convergent in the proximal segment of fusiform aneurysm. (e) Numerous vasa vasorum observed in the dome of fusiform aneurysm (black arrow). (f) Showing a clipped portion of fusiform aneurysm

### Epidemiology

The prevalence of intracranial arterial dolichoectasia in stroke-free patients ranges from 0.8% to 18.8%.<sup>[4]</sup> The prevalence in series with stroke patients ranges from 3.1% to 17.1%.<sup>[15,16]</sup> The criteria used for the definition of dolichoectasia varied in the above series and diagnostic method used were CT angiography, MRI angiography, and autopsy findings. To date, no difference in prevalence has been found in a different race or ethnicity. The dolichoectasia is found to associated with hypertension, myocardial infarction,<sup>[3]</sup> cerebral small vessel diseases,<sup>[17]</sup> and smoking.<sup>[5]</sup> The series have shown dolichoectasia to associated with polycystic kidney disease,<sup>[18]</sup> moyamoya disease,<sup>[6]</sup> ectrodactyly, ectodermal dysplasia and cleft lip-palate syndrome,<sup>[19]</sup> Marfan syndrome,<sup>[20]</sup> Ehlers–Danlos syndrome,<sup>[21]</sup> Pompe disease,<sup>[22]</sup> PHACES syndrome,<sup>[23]</sup> tuberous sclerosis,<sup>[24]</sup> cavernous angioma,<sup>[25]</sup> craniocervical malformation,<sup>[26]</sup> head trauma,<sup>[27]</sup> pseudoxanthoma elasticum, Fabry disease, acquired immune deficiency syndrome.<sup>[6]</sup>

### Pathophysiology

In animal models acute increase in blood flow that causes dilatation of intracerebral artery has been shown to cause disruption of internal elastic lamina.<sup>[28]</sup> The anatomical, hemodynamic and biological factors probably trigger

dolichoectasia. Studies have shown that intracranial arterial diameter should be adjusted according to the circle of Willis, a reduction in a connection between anterior and posterior circulation lead to large increase in basilar artery diameter.<sup>[29]</sup> Hemodynamics may have an important role in dolichoectasia, similar to distal abdominal ectasia, the basilar artery has an obtuse angle at apex mimicking bifurcation of the abdominal aorta, which is known to generate reflection wave, with maximum shear stress in distal abdominal aorta.<sup>[30]</sup> Formation of CAs initiates in response to excessive hemodynamic stress to intracranial arterial wall of vascular bifurcation. The hemodynamic stress may lead to the endothelial dysfunction/injury, infiltration of inflammatory cells, phenotypic modulation and degeneration of smooth muscles, remodeling of extracellular matrix, and subsequent cell death and vessel wall degeneration. In this process, hemodynamic stress, an inflammatory reaction by activated macrophages, and vascular smooth muscle cell death are presumably crucial for the formation of a cerebral aneurysm.<sup>[31]</sup> The disruption of the internal elastic membrane is common in patients of dolichoectasia.<sup>[32]</sup> Marked increase in matrix metalloproteinase enzyme [Figure 5] has been associated with many arteriopathies such as an aortic aneurysm, vascular dementia, and cerebral microangiopathy. The association of dolichoectasia with an aortic aneurysm, multiple lacunar infarct, perivascular atrophy, and leukoaraiosis support probably common pathological process. The role of atherosclerosis in dolichoectasia is unclear. Recent experimental studies using animal models, several pro-inflammatory cascades seem to be activated during aneurysmal progression including NF-κB, tumor necrosis factor-α, prostaglandin, myeloperoxidase, and reactive oxygen species.<sup>[31]</sup> The other trophic factor such sympathetic innervation may have a role, such as in posterior circulation has less sympathetic innervation make susceptible to deformation with increase blood flow.<sup>[33]</sup>

**Clinical course**

The dolichoectasia may be symptomatic or with subclinical infarction to have diagnosed incidentally in radiology.<sup>[34]</sup> The patients may present with compressive symptoms or vascular event. The dolichoectasia of posterior circulation may present with cranial neuropathy; the eight nerve is primarily involved in posterior circulation dolichoectasia.<sup>[35]</sup> The posterior circulation dolichoectasia may manifest as ophthalmoplegia, hemifacial spasm, nystagmus, facial palsy, dizziness, tinnitus, hearing loss, dysarthria, trigeminal neuralgia, and diplopia.<sup>[36]</sup> The dolichoectasia of posterior and anterior circulation<sup>[37]</sup> may present with hydrocephalus. The mechanism may be from direct compression of the ventricle to water hammer effect from pulsation of the dolichoectatic artery. The infrequent presentations of dolichoectasia may be central apnea, cerebellar ataxia, normal-pressure hydrocephalus, and compressive symptoms contralateral to the affected site due to deformation of the brain stem.<sup>[38]</sup> The dolichoectasia of anterior circulation may

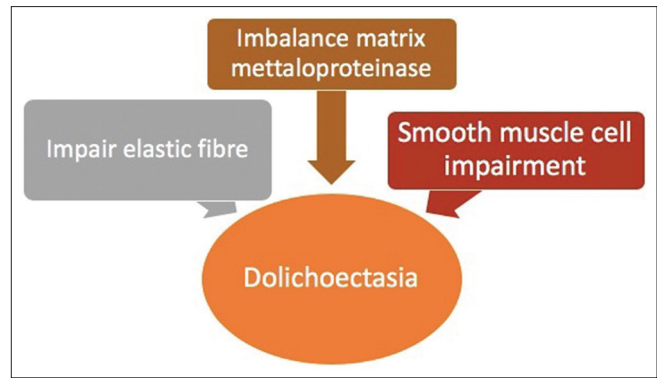


Figure 5: Pathogenesis of dolichoectasia

**Table 3: Diagnostic criteria and scores for basilar artery dolichoectasia based on computed tomography scan**

Basilar artery diameter at mid pons	Laterality	Height of bifurcation
0-1.9–4.5 mm (normal range)	0 - Midline throughout	0 - At or below dorsum sellae
1 - >4.5 mm (ectasia)	1 - Medial to lateral margin of clivus or dorsum sellae	1 - In suprasellar cistern
	2 - Lateral to lateral margin of clivus or dorsum sellae	2 - At third ventricle floor
	3 - At cerebellopontine angle	3 - Indentation and elevation of third ventricle floor

Value of 1-deemed abnormal. Value of 2 or more suggests an abnormality

**Table 4: Clinical presentation**

Asymptomatic	Compressive symptoms	Vascular events
	Cranial neuropathy	Brain infarction
	Hydrocephalus	Transient ischemic attack
	Cerebellar ataxia	Hemorrhagic stroke
	Central apnea	Subarachnoid hemorrhage
	Seizure	
	Pyramidal signs etc.	
	Visual defects	

present with seizure, visual field defect, retinal ischemia, Horner’s syndrome, and pyramidal sign [Table 4].<sup>[38]</sup>

The dolichoectasia may present with brain infarction, transient ischemic stroke, hemorrhagic stroke, and subarachnoid hemorrhage. A systemic review of 375 patients with vertebrobasilar dolichoectasia the 5 years risk of brain infarction (17.6%), brainstem compression (10.3%), transient ischemic attack (10.1%), hemorrhagic stroke (4.7%), and subarachnoid hemorrhage (2.3%).<sup>[39]</sup> The etiologies of stroke are generally due to an artery to artery embolism, traction, and occlusion of a small perforating

branch,<sup>[40]</sup> *in situ* thrombosis less commonly due to arterial dissection<sup>[41]</sup> and vasospasm following subarachnoid hemorrhage. The hemorrhage in dolichoectasia is quite rare with prevalence reported in different case series range from 0.0% to 6.6%.

### Treatment

At present, no specific treatment exists to prevent arterial dilatation or tortuosity. The antiplatelet is used to prevent cerebral ischemia. In a case series of 40 patients, good surgical outcome (Glasgow Outcome Scale scores 1–2) was observed in 78% of patients. The various surgical techniques have done including direct clipping, trapping with bypass, proximal occlusion, resection with re-anastomosis, transposition, aneurysmorrhaphy with thrombectomy, and wrapping. There was no surgical mortality in this series.<sup>[38]</sup>

The endovascular procedure like coils at the top and bottom of the widen artery has been proposed.<sup>[42]</sup> A combination of balloon and stent or use of several overlapping stents and coiling has been proposed.<sup>[43]</sup> The randomized controlled trial is lacking for management of dolichoectatic artery. Several studies continue on the development of the drug for the prevention of progression of an aneurysm is in primitive stage at present. The experiments support the use of hydroxymethylglutaryl-CoA reductase inhibitor (statins) presumably through their potent inhibitory action on NF-κB.<sup>[44]</sup>

### Conclusion

Intracranial arterial dolichoectasia may be associated with certain cardiovascular risk factors and acquired collagen vascular disorders. The exact pathogenesis in progression and risk of rupture of the dolichoectatic segment is not yet confirmed. It can present as asymptomatic incidental finding to local compressive symptoms. In our study, even with the best possible surgical modality, the disease was progressed in size and shape. The randomized controlled trial will be needed in future regarding the best possible management of such intracranial arterial disease. The new modality of treatment such as drug therapy to stop its progression and rupture risk will be required.

### Declaration of patient consent

The authors certify that they have obtained all appropriate patient consent forms. In the form the patient(s) has/have given his/her/their consent for his/her/their images and other clinical information to be reported in the journal. The patients understand that their names and initials will not be published and due efforts will be made to conceal their identity, but anonymity cannot be guaranteed.

### Financial support and sponsorship

Nil.

### Conflicts of interest

There are no conflicts of interest.

### References

- Halsey CS. An Etymology of Latin and Greek. Boston: Ginn & Company; 1889.
- Caplan LR. Dilatative arteriopathy (dolichoectasia): What is known and not known. *Ann Neurol* 2005;57:469-71.
- Pico F, Labreuche J, Touboul PJ, Amarenco P; GENIC Investigators. Intracranial arterial dolichoectasia and its relation with atherosclerosis and stroke subtype. *Neurology* 2003;61:1736-42.
- Gutierrez J, Bagci A, Gardener H, Rundek T, Ekind MS, Alperin N, *et al.* Dolichoectasia diagnostic methods in a multi-ethnic, stroke-free cohort: Results from the Northern Manhattan study. *J Neuroimaging* 2014;24:226-31.
- Passero SG, Rossi S. Natural history of vertebrobasilar dolichoectasia. *Neurology* 2008;70:66-72.
- Yamada K, Hayakawa T, Ushio Y, Mitomo M. Cerebral arterial dolichoectasia associated with moyamoya vessels. *Surg Neurol* 1985;23:19-24.
- Goldstein DA, Timpone J, Cupps TR. HIV-associated intracranial aneurysmal vasculopathy in adults. *J Rheumatol* 2010;37:226-33.
- Wolfe T, Ubogu EE, Fernandes-Filho JA, Zaidat OO. Predictors of clinical outcome and mortality in vertebrobasilar dolichoectasia diagnosed by magnetic resonance angiography. *J Stroke Cerebrovasc Dis* 2008;17:388-93.
- Pico F, Biron Y, Bousser MG, Amarenco P. Concurrent dolichoectasia of basilar and coronary arteries. *Neurology* 2005;65:1503-4.
- Vasović L, Trandafilović M, Jovanović I, Ugrenović S, Vlajković S. Vertebral and/or basilar dolichoectasia in human adult cadavers. *Acta Neurochir (Wien)* 2012;154:1477-88.
- Brinjikji W, Nasr DM, Flemming KD, Rouchaud A, Clo HJ, Lanzino G, *et al.* Clinical and imaging characteristics of di use intracranial dolichoectasia. *AJNR Am J Neuroradiol* 2017;38:915-22.
- Park SH, Yim MB, Lee CY, Kim E, Son EI. Intracranial fusiform aneurysms: It's pathogenesis, clinical characteristics and managements. *J Korean Neurosurg Soc* 2008;44:116-23.
- Tanaka M, Sakaguchi M, Miwa K, Okazaki S, Furukado S, Yagita Y, *et al.* Basilar artery diameter is an independent predictor of incident cardiovascular events. *Arterioscler Thromb Vasc Biol* 2013;33:2240-4.
- Smoker WR, Price MJ, Keyes WD, Corbett JJ, Gentry LR. High-resolution computed tomography of the basilar artery: 1. Normal size and position. *AJNR Am J Neuroradiol* 1986;7:55-60.
- Ince B, Petty GW, Brown RD Jr., Chu CP, Sicks JD, Whisnant JP, *et al.* Dolichoectasia of the intracranial arteries in patients with first ischemic stroke: A population-based study. *Neurology* 1998;50:1694-8.
- Bogousslavsky J, Regli F, Maeder P, Meuli R, Nader J. The etiology of posterior circulation infarcts: A prospective study using magnetic resonance imaging and magnetic resonance angiography. *Neurology* 1993;43:1528-33.
- Pico F, Labreuche J, Seilhean D, Duyckaerts C, Hauw JJ, Amarenco P, *et al.* Association of small-vessel disease with dilatative arteriopathy of the brain: Neuropathologic evidence. *Stroke* 2007;38:1197-202.
- Schievink WI, Torres VE, Wiebers DO, Huston J 3<sup>rd</sup>. Intracranial arterial dolichoectasia in autosomal dominant polycystic kidney disease. *J Am Soc Nephrol* 1997;8:1298-303.

19. Miner ME, Rea GL, Handel S, Bertz J. Trigeminal neuralgia due to dolichoectasia: Angiographic and CT findings in a patient with the EEC syndrome. *Neuroradiology* 1980;20:163-6.
20. Finney LH, Roberts TS, Anderson RE. Giant intracranial aneurysm associated with Marfan's syndrome. Case report. *J Neurosurg* 1976;45:342-7.
21. Mcfarland W, Fuller DE. Mortality in Ehlers-Danlos syndrome due to spontaneous rupture of large arteries. *N Engl J Med* 1964;271:1309-10.
22. Laforêt P, Petiot P, Nicolino M, Orlikowski D, Caillaud C, Pellegrini N, *et al.* Dilative arteriopathy and basilar artery dolichoectasia complicating late-onset Pompe disease. *Neurology* 2008;70:2063-6.
23. Baccin CE, Krings T, Alvarez H, Ozanne A, Lasjaunias PL. A report of two cases with dolichosegmental intracranial arteries as a new feature of PHACES syndrome. *Childs Nerv Syst* 2007;23:559-67.
24. Blumenkopf B, Huggins MJ. Tuberos sclerosi and multiple intracranial aneurysms: Case report. *Neurosurgery* 1985;17:797-800.
25. Kanemoto Y, Hisanaga M, Bessho H. Association of a dolichoectatic middle cerebral artery and an intracranial cavernous hemangioma – Case report. *Neurol Med Chir (Tokyo)* 1998;38:40-2.
26. Gutiérrez J, Sandoval L, Rivera C, Zamorano C, Santiago N, Martínez V, *et al.* A dangerous combination for stroke in young patient: Assimilation of the atlas and anti beta2-glycoprotein I antibodies. *Rev Med Inst Mex Seguro Soc* 2009;47:89-94.
27. Nakahara I, Taki W, Tanaka M, Matsumoto K, Kikuchi H. Dolichoectasia of the middle cerebral artery – Case report. *Neurol Med Chir (Tokyo)* 1995;35:822-4.
28. Mizutani T, Miki Y, Kojima H, Suzuki H. Proposed classification of nonatherosclerotic cerebral fusiform and dissecting aneurysms. *Neurosurgery* 1999;45:253-9.
29. Gutierrez J, Sultan S, Bagci A, Rundek T, Alperin N, Elkind MS, *et al.* Circle of Willis configuration as a determinant of intracranial dolichoectasia. *Cerebrovasc Dis* 2013;36:446-53.
30. Sho E, Sho M, Singh TM, Nanjo H, Komatsu M, Xu C, *et al.* Arterial enlargement in response to high flow requires early expression of matrix metalloproteinases to degrade extracellular matrix. *Exp Mol Pathol* 2002;73:142-53.
31. Aoki T. Inflammation mediates the pathogenesis of cerebral aneurysm and becomes therapeutic target. *Neuroimmunol Neuroinflammation* 2015;2:86-92.
32. Housepian EM, Pool JL. A systematic analysis of intracranial aneurysms from the autopsy file of the Presbyterian hospital, 1914 to 1956. *J Neuropathol Exp Neurol* 1958;17:409-23.
33. Edvinsson L, Hardebo JE, Owman C. Role of perivascular sympathetic nerves in autoregulation of cerebral blood flow and in blood-brain barrier functions. *Acta Neurol Scand Suppl* 1977;64:50-1.
34. Ubogu EE, Zaidat OO. Vertebrobasilar dolichoectasia diagnosed by magnetic resonance angiography and risk of stroke and death: A cohort study. *J Neurol Neurosurg Psychiatry* 2004;75:22-6.
35. Deeb ZL, Jannetta PJ, Rosenbaum AE, Kerber CW, Drayer BP. Tortuous vertebrobasilar arteries causing cranial nerve syndromes: Screening by computed tomography. *J Comput Assist Tomogr* 1979;3:774-8.
36. Resta M. Clinical-angiographic correlations in 132 patients with mega dolichol vertebrobasilar anomaly. *Neuroradiology* 1984;26:213-6.
37. Jagetia A, Patel K, Sachdeva D, Rathore L. Dolichoectatic internal carotid artery presenting as a sellar-suprasellar mass with symptomatic hydrocephalus. *Neurol India* 2017;65:681-2.
38. Anson JA, Lawton MT, Spetzler RF. Characteristics and surgical treatment of dolichoectatic and fusiform aneurysms. *J Neurosurg* 1996;84:185-93.
39. Wolters FJ, Rinkel GJ, Vergouwen MD. Clinical course and treatment of vertebrobasilar dolichoectasia: A systematic review of the literature. *Neurol Res* 2013;35:131-7.
40. Passero S, Filosomi G. Posterior circulation infarcts in patients with vertebrobasilar dolichoectasia. *Stroke* 1998;29:653-9.
41. Borota L, Jonasson P. Basilar and bilateral carotid dolichoectasia with spontaneous dissection of C2 segment of the internal carotid artery. *AJNR Am J Neuroradiol* 2006;27:1241-4.
42. Otsuka G, Miyachi S, Handa T, Negoro M, Okamoto T, Suzuki O, *et al.* Endovascular trapping of giant serpentine aneurysms by using Guglielmi detachable coils: Successful reduction of mass effect. Report of two cases. *J Neurosurg* 2001;94:836-40.
43. Suh SH, Kim BM, Chung TS, Kim DI, Kim DJ, Hong CK, *et al.* Reconstructive endovascular treatment of intracranial fusiform aneurysms: A 1-stage procedure with stent and balloon. *AJNR Am J Neuroradiol* 2010;31:155-60.
44. Aoki T, Kataoka H, Ishibashi R, Nozaki K, Hashimoto N. Simvastatin suppresses the progression of experimentally induced cerebral aneurysms in rats. *Stroke* 2008;39:1276-85.