

## Contrecoup Extradural Hematoma Without Fracture: A Case Report and Review of Literature

### Abstract

Extradural hemorrhages are commonly seen in coup head injuries, rarely seen in contrecoup head injuries. Acute extradural hemorrhage in the coup head injuries associated with a fracture is common, but the incidence of acute contrecoup extradural hemorrhage not associated with the fracture is extremely rare. Only 21 cases have been reported previously. A 28-year-old male patient presented to the emergency department with complaints of sustaining injuries in a road traffic accident by fall from a two-wheeler. No history of loss of consciousness, vomiting, seizures, and ear/nose bleed. On examination, the patient was conscious and coherent with a Glasgow Coma Scale score of 15/15 and a laceration on the right frontotemporal region which was sutured. Contrast tomography of the brain revealed an extradural hemorrhage of 10 mm thickness in the left parieto-occipital region with soft tissue swelling in the right temporoparietal region, without any evident fractures in the calvarium. The patient was managed conservatively. Contrecoup extradural hematoma is a rare entity, and those without fracture are extremely rare. Early diagnosis, careful observation, and management lead to a good outcome.

**Keywords:** *Contrecoup, extradural, hemorrhage, trauma, without fracture*

**Siddartha Reddy Musali, Srikrishnaditya Manne, Nagarjuna Butkuri, Prakash Rao Gollapudi, Thatikonda Satish Kumar**

*Department of Neurosurgery, Gandhi Medical College and Hospital, Secunderabad, Telangana, India*

### Introduction

An extradural hemorrhage is a collection of blood in the space between the inner table of calvarium and dura mater. It can occur in coup and countercoup injuries. Extradural hematomas (EDHs) due to coup type of head injuries are quite common and most often associated with overlying calvarium fractures, whereas contrecoup EDHs are very rare entities and are not associated with any overlying fractures. There are only a few reports of contrecoup EDHs published in the literature.

### Case Report

A 28-year-old male alleged to have sustained head injuries in a road traffic accident by fall from a two-wheeler under the influence of alcohol presented to the emergency department with no complaints of loss of consciousness, vomiting, seizures, and ear/nose bleed. A laceration was noted on the right temporoparietal region which was immediately sutured. On examination, the patient was conscious and coherent with a Glasgow Coma Scale Score of 15/15 without any focal neurological deficits; all

vitals were within normal limits. Computed tomography of the brain was done which revealed a 10 mm thick extradural hemorrhage in the left parieto-occipital region and soft tissue thickening in the right temporoparietal region [Figure 1]. No calvarial fractures were noted. A computed tomography scan of the brain was repeated after 24 h which revealed no increase in the thickness of extradural hemorrhage. The patient was managed conservatively, and the follow-up was uneventful.

### Discussion

At our center, we came across one such case where the patient had a contrecoup EDH without an overlying fracture of the calvarium, and a thorough review of literature reiterates the fact that this presentation is a rare variant and hence this case report. EDHs are one of the most common presentations in head injury. It accounts for 1%–3% of all the head injuries.<sup>[1]</sup> They are usually located at the site of impact and occur due to the rupture of a middle meningeal artery or calvarial fracture resulting in accumulation of blood in between the inner calvarium and dura mater due to the separation of dura mater

**Address for correspondence:**  
Dr. Siddartha Reddy Musali,  
Department of Neurosurgery,  
Gandhi Medical College and  
Hospital, Padmarao Nagar,  
Secunderabad - 500 003,  
Telangana, India.  
E-mail: [siddarthareddy123@gmail.com](mailto:siddarthareddy123@gmail.com)

#### Access this article online

**Website:** [www.asianjns.org](http://www.asianjns.org)

**DOI:** 10.4103/ajns.AJNS\_283\_18

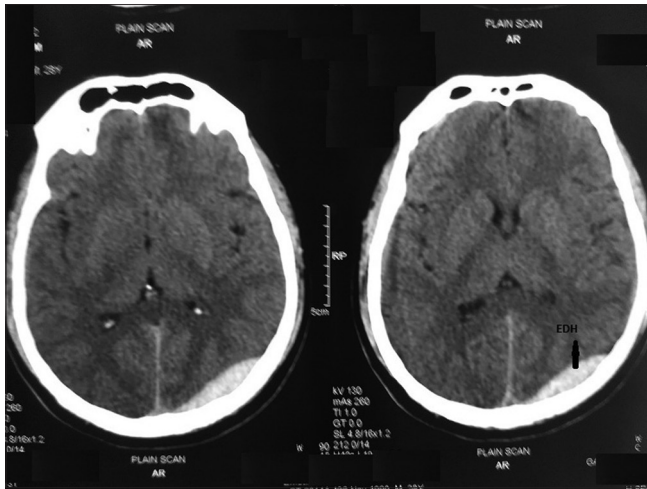
#### Quick Response Code:



**How to cite this article:** Musali SR, Manne S, Butkuri N, Gollapudi PR, Kumar TS. Contrecoup extradural hematoma without fracture: A case report and review of literature. *Asian J Neurosurg* 2019;14:322-4.

This is an open access journal, and articles are distributed under the terms of the Creative Commons Attribution-NonCommercial-ShareAlike 4.0 License, which allows others to remix, tweak, and build upon the work non-commercially, as long as appropriate credit is given and the new creations are licensed under the identical terms.

**For reprints contact:** [reprints@medknow.com](mailto:reprints@medknow.com)



**Figure 1:** Computed tomography scan of the brain shows a 10 mm thick hyperdense collection in the left parieto-occipital region with a subcutaneous swelling in the right temporoparietal region. No calvarial fracture noted

from the calvarium. These types of EDHs are referred to as coup EDHs and are more commonly noted.<sup>[2]</sup> They develop below the impact point and are accompanied by the linear fracture in most of the cases.<sup>[1,3,4]</sup>

Contrecoup EDHs, however, are a rare variant those not associated with a fracture are extremely rare, and only 21 cases have been previously reported in the literature.<sup>[5]</sup> They are not associated with any overlying fractures and are usually found at a location opposite to the site of impact. Contrecoup EDHs are more commonly seen in the females in the fifth to sixth decade.<sup>[6]</sup> They are more commonly seen in the frontal regions, which can be explained by the fact that the dura mater can easily be detached from the inner table of the lateral frontal region.<sup>[1]</sup>

Contrecoup acute epidural hemorrhage without fracture in the occipital region is considered due to the skull development. The occipital bone develops from two types of tissues membranous and cartilaginous tissues, and the transverse sinus is present in the boundary between these tissues. Thus, this region is easily deformed and reported to be a region with reduced resistance against external forces.<sup>[7]</sup>

Cavitation effect and inertia loading at the countercoup site may be the reason for countercoup hematomas.<sup>[8]</sup> The negative pressure created at the opposite site may cause the cavitation and the tensile strain in the angular movement of the head may cause vascular injury.<sup>[9]</sup> Both of these mechanisms explain the genesis of contrecoup intraparenchymal hematomas. However, mechanism of contrecoup EDH remains unclear.

Few have proposed that it might be generated by the buckling effect of the skull exactly opposite to the site of impact.<sup>[10]</sup> Others have proposed that compression wave from the site of impact produces a relative movement in between the dura

mater and skull bone resulting in the stripping of dura mater and collection of EDH at the diagonally opposite side.

Here, we report a case of the left parieto-occipital EDH in a 28-year-old male who was managed conservatively with a good outcome. Few other cases reported by others have been noted below.

Okamoto reported a case of the left frontal contrecoup hematoma in a 51-year-old female due to fall which was surgically treated.<sup>[11]</sup> Balasubramaniam and Ramesh reported a case of a 21-year-old male patient with a contrecoup EDH at the left frontal region which was managed surgically. Miyazaki *et al.* reported a case of right frontal contrecoup EDH in a 52-year-old female who was managed surgically.<sup>[3]</sup> Motohashi reported a case of a 59-year-old female patient with a left frontal contrecoup EDH who was managed conservatively.<sup>[4]</sup> Mitsuyama *et al.* reported a case of a 50-year-old female patient with right frontal contrecoup EDH who was managed conservatively.

## Conclusion

EDH is a neurosurgical emergency. Contrecoup variants of EDH are a rare entity, and those not associated with fracture are extremely rare. Hence, careful observation and timely management are required. Here, we report a case of contrecoup variant of EDH which is not associated with fracture.

## Declaration of patient consent

The authors certify that they have obtained all appropriate patient consent forms. In the form the patient(s) has/have given his/her/their consent for his/her/their images and other clinical information to be reported in the journal. The patients understand that their names and initials will not be published and due efforts will be made to conceal their identity, but anonymity cannot be guaranteed.

## Financial support and sponsorship

Nil.

## Conflicts of interest

There are no conflicts of interest.

## References

- Mitsuyama T, Ide M, Kawamura H. Acute epidural hematoma caused by contrecoup head injury – Case report. *Neurol Med Chir (Tokyo)* 2004;44:584-6.
- Bullock MR, Chesnut R, Ghajar J, Gordon D, Hartl R, Newell DW, *et al.* Surgical management of acute epidural hematomas. *Neurosurgery* 2006;58:S7-15.
- Miyazaki Y, Isojima A, Takekawa M, Abe S, Sakai H, Abe T, *et al.* Frontal acute extradural hematoma due to contrecoup injury: A case report. *No Shinkei Geka* 1995;23:917-20.
- Motohashi O, Tominaga T, Shimizu H, Koshu K, Yoshimoto T. Acute epidural hematoma caused by contrecoup injury. *No To Shinkei* 2000;52:833-6.

5. Andoh S, Matsuura C, Sakaeyama Y, Okonogi S, Node Y, Masuda H, *et al.* Acute contrecoup epidural hematoma that developed without skull fracture in two adults: Two case reports. *J Med Case Rep* 2018;12:166.
6. Takeuchi S, Takasato Y, Masaoka H, Otani N. Administration of recombinant tissue plasminogen activator to a case of cerebral infarction in the setting of painless aortic dissection. *Neurol India* 2009;57:808-9.
7. Shigemori M, Moriyama T, Eguchi G, Noguchi M, Kawasaki K, Kawaba T, *et al.* Acute epidural hematoma of the posterior fossa caused by Fronto-temporal impact. Case report. *Neurol Med Chir (Tokyo)* 1985;25:489-92.
8. Sahoo SK, Srivastava C, Vankipuram S. Revisiting the contrecoup extradural hematoma. *Med J DY Patil Univ* 2017;10:321-2.
9. Meaney DF, Olvey SE, Gennarelli TA. Biomechanical basis of traumatic brain injury. In: Winn HR, editor. *Youmans Neurological Surgery*. 6<sup>th</sup> ed., Vol. 4. Philadelphia: W.B. Saunders; 2011. p. 3284-5.
10. Balasubramaniam V, Ramesh VG. A case of coup and contrecoup extradural hematoma. *Surg Neurol* 1991;36:462-4.
11. Okamoto H, Harada K, Yoshimoto H, Uozumi T. Acute epidural hematoma caused by contrecoup injury. *Surg Neurol* 1983;20:461-3.