

Efficacy and Safety of a Modified Pigtail-Shaped Microguidewire during Endovascular Thrombectomy

Abstract

A 75-year-old man presented with right-sided hemiplegia and was diagnosed with a left middle cerebral artery occlusion. He underwent endovascular thrombectomy, and a bulge was found. A modified pigtail-shaped microguidewire (MPMGW) proved useful for diagnosis because it allowed differentiation between the occluded artery and a saccular aneurysm as the etiology. When a clot was partially retrieved, a previously unidentified vessel dilatation appeared. The dilatation origin was unclear and could have resulted from either the occluded artery or an unruptured saccular aneurysm. We tried to navigate the MPMGW into the bulging area. The patient showed unusual body movement attributed to pain and the dilatation was diagnosed as an aneurysm. Subsequent 3-dimensional angiography revealed a recanalized artery and the aneurysm. With no subarachnoid hemorrhage or extravasation of the contrast medium. The hemiplegia dramatically improved. An MPMGW may be useful in acute thrombectomy where the target vessel cannot be visualized during the procedure.

Keywords: Acute ischemic stroke, endovascular treatment, microguidewire, modified pigtail-shape, thrombectomy

Introduction

Mechanical thrombectomy for acute ischemic stroke has been widely used since its efficacy was proved.^[1] During the procedure, a physician guides the microcatheter into invisible vessels on fluoroscopy. To date, we use modified pigtail-shape microguidewires (MPMGWs) for thrombectomy as reported by Sato *et al.*^[2] MPMGW provides better vessel selectivity with torque and better microcatheter trackability due to working as an anchor compared to devices with a rectal-angled shape. Moreover, Ohshima *et al.*^[3,4] reported that it provides information about the quality of the clot during clot penetration, and enables effective penetration of an extremely hard clot via the corkscrew penetrating method. In our case, it was difficult to determine the origin of the occluded artery or unruptured aneurysm during the procedure. MPMGW had an important role in making this difficult judgment. We thought that this case is unique and important to prevent catastrophic complications.

This is an open access journal, and articles are distributed under the terms of the Creative Commons Attribution-NonCommercial-ShareAlike 4.0 License, which allows others to remix, tweak, and build upon the work non-commercially, as long as appropriate credit is given and the new creations are licensed under the identical terms.

For reprints contact: reprints@medknow.com

Case Report

A 75-year-old man was admitted to our emergency department with right-sided hemiplegia and aphasia 40 min after initial presentation. At admission, his National Institute of Health Stroke Scale score was 13.^[5] The 12-lead electrocardiogram revealed atrial fibrillation. Emergency diffusion-weighted imaging demonstrated a high-intensity area in the left insular gyrus. Magnetic resonance angiography showed left middle cerebral artery occlusion [Figure 1]. The Alberta Stroke Program Early Computed Tomography (CT) Score was 9.^[6] Intravenous recombinant tissue plasminogen activator (rt-PA) injection was initiated 35 min after his arrival. He was transferred into the angio-room for endovascular thrombectomy without confirming the efficacy of the rt-PA.

Under local anesthesia, a 9-F Optimo balloon guide catheter (Tokai Medical Products, Aichi, Japan) was advanced into the left internal carotid artery through the right common femoral artery. Because left carotid angiogram revealed partial occlusion of the middle cerebral artery with a shadow of the clot [Figure 2], we diagnosed as an

How to cite this article: Ato F, Ohshima T, Miyachi S, Matsuo N, Kawaguchi R, Takayasu M. Efficacy and safety of a modified pigtail-shaped microguidewire during endovascular thrombectomy. *Asian J Neurosurg* 2019;14:1040-3.

**Fuminori Ato,
Tomotaka
Ohshima¹,
Shigeru Miyachi¹,
Naoki Matsuo,
Reo Kawaguchi,
Masakazu Takayasu**

*Department of Neurosurgery,
Aichi Medical University,
¹Neuroendovascular Therapy
Center, Aichi Medical
University, Nagakute,
Aichi, Japan*

Address for correspondence:

*Dr. Tomotaka Ohshima,
1-1 Yazakokarimata, Nagakute,
Aichi 480-1195, Japan.
E-mail: tmtkoh@gmail.com*

Access this article online

Website: www.asianjns.org

DOI: 10.4103/ajns.AJNS_28_19

Quick Response Code:



embolism rather than a chronic stenosis. We attempt to recanalize through the Stent-Retrieving into an Aspiration Catheter with Proximal Balloon method.^[7] A Penumbra ACE 68 aspiration catheter (Medicos-Hirata, Osaka, Japan), Marksman microcatheter (Medtronic, Minneapolis, MN, USA), and a Chikai 14 microguidewire (Asahi Intecc Co. Ltd., Aichi, Japan) were coaxially navigated. The wire tip was shaped using the attached shaping mandrel as the modified pigtail shape. The round tip was approximately 2 mm in diameter [Figure 3]. After a Revive SE Thrombectomy Device (Codman, Raynham, MA, USA) was deployed and retrieved, the clot shadow totally disappeared. However, a bulge, which did not distinguish the origin of the artery or an unruptured aneurysm, was found [Figure 4a]. A lateral view of the left carotid angiogram revealed a nonvascularized area [Figure 4b]. Therefore, the Penumbra ACE 68, Marksman microcatheter, and Chikai 14 guidewire were advanced again. The round tip of the guidewire was navigated carefully into the bulge. We believed if there was an occlusion due to clot formation, the round tip of the wire could be advanced

while maintaining the shape. The wire tip was pushed into the bulge, and the patient showed unusual body movement. The road-mapping image suddenly deviated because of the patient's movement [Figure 5]. Because we judged that the patient felt pain due to stimulating the aneurysm by the wire, we decided to withdraw from the procedure.

Subsequent three-dimensional angiography demonstrated that the bulge was a small aneurysm and a recanalized branch appeared just beside it [Figure 6a]. Finally, complete spontaneous recanalization was achieved [Figure 6b]. Postprocedural brain CT revealed neither intracranial hemorrhage nor extravasation of contrast media. The hemiplegia and aphasia resolved just after the procedure. The patient discharged from our hospital without motor weakness on postoperative day 10.

Discussion

Endovascular thrombectomy in patients with acute ischemic stroke is different from other endovascular operations in terms of lack of preprocedural anatomic information. In addition, a microcatheter must be navigated into an invisible, small, and fragile intracranial artery on fluoroscopy. Reportedly, the prevalence of unruptured aneurysms in adults was 2.3%–6.0%,^[8] and the risk of

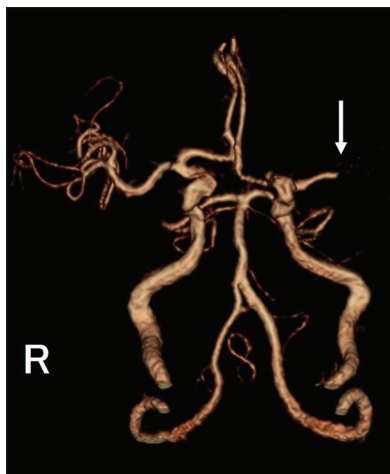

Figure 1: Initial magnetic resonance angiography shows disappearance of the M1 segment of the left middle cerebral artery (arrow) R: Right




Figure 3: Photographs of the modified pigtail-shaped microguidewire

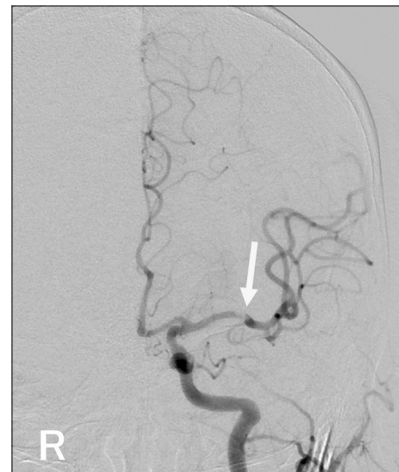


Figure 2: The left carotid angiography shows a partial occlusion of the middle cerebral artery with a shadow of the clot (arrow). R: Right

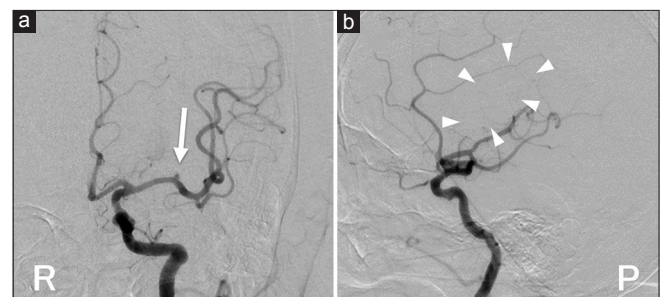


Figure 4: Angiographies after stent retrieval. (a) Anterior-posterior view; A white arrow indicates a small bulging. R: Right. (b) Lateral view; White arrowheads indicate nonvascularized area. P: Posterior

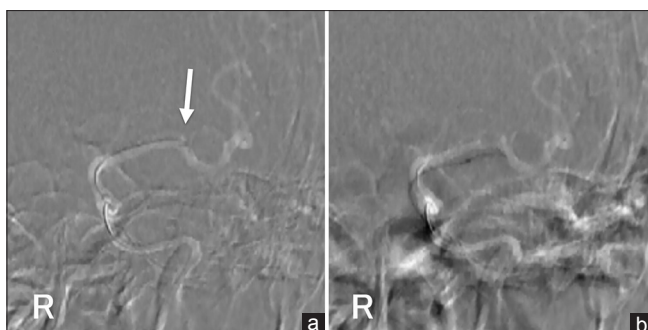


Figure 5: Intraprocedural road-mapping images. (a) Right before the wire navigates into the bulging. A white arrow indicates a small bulging. (b) After the wire insertion into the bulging. The road-mapping image is deviated due to the patient's abnormal movement. R: Right

permanent neurologic disability and death associated with intraprocedural aneurysm perforation was 29%–39%, even if treatment of the aneurysms was aimed at coiling.^[9] In cases undergoing rt-PA therapy, an intraprocedural unintended aneurysm rupture must be critical.

We used MPMGW, which had been reported by Sato *et al.*,^[2] for all acute thrombectomy procedures. MPMGW is safe because it prevents unexpected wire migration into perforators. The wire also provides better vessel selectivity with torque. When a guide catheter cannot be advanced up to the common carotid artery, the MPMGW allows selection into the internal carotid artery navigation into intracranial small arteries with the same tip shape. It also provides better microcatheter trackability because it acts like an anchor in the distal vessels compared to a conventional rectal-angled shape. Moreover, Ohshima *et al.*^[3] reported that it provides information about the quality of the clot during clot penetration. Devices were selected based on the evaluation of the clot, soft or hard, by the wire configuration and behavior. In cases with an extremely hard clot, their corkscrew penetrating method allowed for amazing en bloc clot retrieval.^[4]

In our case, when the arterial bulge was found, the possibility of an aneurysm was conceived early. However, because the angiogram showed a remaining nonvascularized area, we had to seek the occluded arterial branch considering the patient's severe symptom. When the round tip of the MPMGW was advanced gently into the bulge, the patient showed unusual body movement. Although some patients often complain of a headache when the microguidewire is passed in the normal vessels, the patient showed head deviation with a little stress against the vessel wall of the bulge. Therefore, we considered the presence of an abnormality and decided to withdraw the procedure. When the origin of the occluded vessel is undetectable, we usually obtain a three-dimensional angiogram to expose it. In our case, the occluded artery appeared spontaneously recanalized just before the three-dimensional angiogram according to the effectiveness of the intravenous rt-PA.

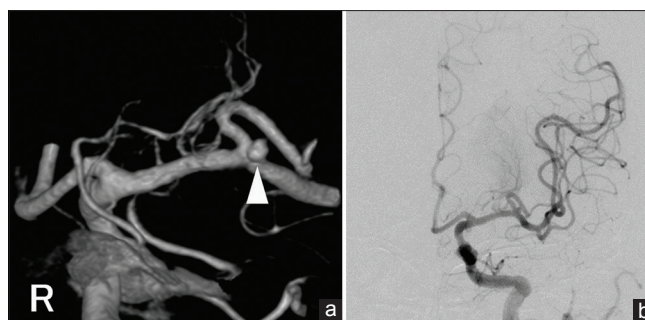

Figure 6: (a) A three-dimensional angiography shows a small aneurysm (white arrowhead) and recanalized branch. R: Right. (b) Postoperative angiography demonstrates complete recanalization to the peripheral area

Recently, Keulers *et al.*^[10] reported the wireless microcatheter passing the clot to prevent vessel perforation by microguidewire. In this report, the success rate of passing the clot was 71.8%, and there was no hemorrhagic complication. We think the direct pushing of the microcatheter may cause a devastating subarachnoid hemorrhage in our case due to the bolder movement than the microwire. We believe our round tip of microwire is safer than the tip of microcatheter.

This report has some limitations. First, physicians require skills and tips for manual shaping of the MPMGW. The shaping mandrel attached with Chikai microguidewire series (Asahi Intecc) provides better handling than others. If the round shape is memorized to the far tip, it becomes difficult to insert into microcatheters. Therefore, we recommend that the tip should remain straight for 2 mm. Second, the shapability of the wire is different for each product. The Tenrou microguidewire (Kaneka, Osaka, Japan) can be shaped into a modified pigtail as well as the Chikai 14 microguidewire. Whereas the Traxcess microguidewire (Terumo, Tokyo, Japan) cannot be shaped owing to its core wire structure in the tip. Third, in our case, we judged the dilatation to be an aneurysm according to the patient's unusual body movement. Complaints from patients are various, and it is impossible to establish a criteria. We believe a sign from patients during operation is very important. Despite these limitations, we believe our results will contribute significantly toward more secure endovascular thrombectomy than those currently in use.

Declaration of patient consent

The authors certify that they have obtained all appropriate patient consent forms. In the form the patient has given his consent for his images and other clinical information to be reported in the journal. The patient understands that his name and initial will not be published and due efforts will be made to conceal his identity, but anonymity cannot be guaranteed.

Financial support and sponsorship

Nil.

Conflicts of interest

There are no conflicts of interest.

References

1. Chen CJ, Ding D, Starke RM, Mehndiratta P, Crowley RW, Liu KC, *et al.* Endovascular vs. medical management of acute ischemic stroke. *Neurology* 2015;85:1980-90.
2. Sato M, Ohshima T, Ishikawa K, Goto S, Yamamoto T, Izumi T, *et al.* A novel technique of safe and versatile microguidewire shaping with neuroendovascular therapy: Modified pigtail method. *J Neuroendovasc Ther* 2017;11:266-71.
3. Ohshima T, Ishikawa K, Goto S, Yamamoto T. Relationship between clot quality and microguidewire configuration during endovascular thrombectomy for acute ischemic stroke. *World Neurosurg* 2017;107:657-62.
4. Ohshima T, Imai T, Sato M, Goto S, Yamamoto T, Nishizawa T, *et al.* A novel technique for higher success rates of recanalization with stent clot retriever: corkscrew penetrating method. *J Neuroendovasc Ther* 2017;11:94-8.
5. Lyden PD, Lu M, Levine SR, Brott TG, Broderick J; NINDS rtPA Stroke Study Group, *et al.* A modified national institutes of health stroke scale for use in stroke clinical trials: Preliminary reliability and validity. *Stroke* 2001;32:1310-7.
6. Barber PA, Demchuk AM, Zhang J, Buchan AM. Validity and reliability of a quantitative computed tomography score in predicting outcome of hyperacute stroke before thrombolytic therapy. ASPECTS study group. Alberta stroke programme early CT score. *Lancet* 2000;355:1670-4.
7. Goto S, Ohshima T, Ishikawa K, Yamamoto T, Shimato S, Nishizawa T, *et al.* A stent-retrieving into an aspiration catheter with proximal balloon (ASAP) technique: A technique of mechanical thrombectomy. *World Neurosurg* 2018;109:e468-e475.
8. Rinkel GJ, Djibuti M, Algra A, van Gijn J. Prevalence and risk of rupture of intracranial aneurysms: A systematic review. *Stroke* 1998;29:251-6.
9. Cloft HJ, Kallmes DF. Cerebral aneurysm perforations complicating therapy with Guglielmi detachable coils: A meta-analysis. *AJNR Am J Neuroradiol* 2002;23:1706-9.
10. Keulers A, Nikoubashman O, Mpotsaris A, Wilson SD, Wiesmann M. Preventing vessel perforations in endovascular thrombectomy: Feasibility and safety of passing the clot with a microcatheter without microwire: The wireless microcatheter technique. *J Neurointerv Surg* 2018. pii: neurintsurg-2018-014267.