

Surgical Management of Hirayama Disease: A Rare Entity with Unusual Clinical Features

Abstract

Hirayama disease (HD) is a rare type of cervical myelopathy in young males due to neck flexion causing cervical cord atrophy and asymmetric flattening with preferential involvement of anterior horn cells of the spinal cord. This is due to forward displacement of the cord during neck flexion getting compressed between the posterior part of the vertebral body and the posterior dura. The spinal cord involvement occurs due to repeated flexion and extension motion of the neck leading to selective spinal cells injury and atrophy. Most cases report an asymmetric lower motor neuron type of weakness predominantly involving the forearm and hand muscles. We report here a case of HD in an 18-year-old male who presented to us with weakness and wasting in the right hand. The patient was progressively symptomatic over a period of 1 year before presentation. The etiology and the exact cause of HD largely remain debatable and rely on the understanding of few theories which have been put forward. The natural history of this disease reaches a plateau in terms of neurological involvement after 2–5 years and is considered a self-remitting disorder. The patient was initially managed with a cervical collar immobilization but symptoms were largely not improving which was attributed to poor brace compliance. The patient was then managed surgically with a posterior lateral mass instrumentation without fusion in a lordotic alignment at the levels of maximal dural shift anteriorly. The patient improved neurologically following the surgery and maintained the intact status at the last follow-up.

Keywords: Cervical flexion myelopathy, Hirayama disease, instrumentation without fusion

Introduction

Hirayama disease (HD) is a sporadic juvenile muscular atrophy which affects muscles of forearm and hand. This rare entity was first described by Hirayama in the year 1959.^[1] HD is mainly seen in young males of Asian ethnicity^[2-4] in the second and third decades of life. There are sparse data regarding the exact incidence and prevalence of HD. According to a study by Tashiro *et al.*,^[4] they identified 333 cases based on two questionnaire-based surveys. The other data are still anecdotal and limited to case series and reports as the one described by Huang *et al.*,^[5] of 40 patients. The cases are not restricted only from Asia and there are reports from Europe and America too. It is an insidious onset slowly progressive disease which becomes self-limiting over a period. Sensory, autonomic system involvement and upper motor neuron signs are rare.^[6]

This is an open access journal, and articles are distributed under the terms of the Creative Commons Attribution-NonCommercial-ShareAlike 4.0 License, which allows others to remix, tweak, and build upon the work non-commercially, as long as appropriate credit is given and the new creations are licensed under the identical terms.

For reprints contact: reprints@medknow.com

Etiology and pathogenesis of HD mainly involve lower cervical cord damage due to stretching of tight cord in the spinal canal during neck flexion. Repeated neck flexion causes gradual cord changes which include ischemia of anterior horn cells (AHCs) and cord atrophy. This causes the persistence of symptoms such as handgrip weakness, difficulty in writing and other fine activities. Younger patients are easily disabled and notice their symptoms early in the course of the disease.

The treatment of HD involves cervical collar immobilization in neck extension; however, this requires compliance with collar for a prolonged duration. Surgical fixation to maintain neck extension without decompression or fusion is another treatment modality described.

Case Report

An 18-year-old male patient presented to our tertiary care hospital with complaints of weakness in the right hand and forearm

How to cite this article: Srivastava SK, Marathe N, Raj A, Bhosale S, Dhole K. Surgical management of hirayama disease: A rare entity with unusual clinical features. *Asian J Neurosurg* 2020;15:405-8.

Submitted: 18-Sep-2019 **Revised:** 30-Nov-2019
Accepted: 18-Feb-2020 **Published:** 29-May-2020

**Sudhir Kumar Srivastava,
Nandan Marathe,
Aditya Raj,
Sunil Bhosale,
Kiran Dhole¹**

*Department of Orthopedics, Seth G.S Medical College and King Edward Memorial Hospital,
¹Department of Orthopedics, LTMMC and General Hospital, Mumbai, Maharashtra, India*

Address for correspondence:

*Dr. Aditya Raj,
Department of Orthopedics, Seth G.S Medical College and King Edward Memorial Hospital,
6th Floor, Multistorey Building, Parel, Mumbai - 400 012,
Maharashtra, India.
E-mail: adityagmck@gmail.com*

Access this article online

Website: www.asianjns.org

DOI: 10.4103/ajns.AJNS_291_19

Quick Response Code:



and difficulty in performing fine activities such as writing and buttoning-unbuttoning. Symptoms were insidious in onset and gradually progressed over the period of 1 year. The patient did not have neck pain, tingling numbness in hand, difficulty in walking, dysphagia, or bowel bladder involvement. There was no history of trauma. He did not have any other medical comorbidities.

Clinical examination revealed painless neck movements. There was marked wasting of hand muscles with weakness of handgrip on the right side. There was weakness of finger abduction and adduction. Wrist flexion was Medical Research Council (MRC) Grade 3 on the right side. Power in the rest of the upper limb and both lower limbs was Grade 5. There was no history of involuntary movements. Bladder and bowel functions were intact. The posterior column, cerebellum, and cranial nerve functions were intact. Blood investigations did not reveal any significant abnormality. Radiological investigations in the form of cervical spine radiograph and magnetic resonance imaging (MRI) were done. Plain radiographs revealed loss of cervical lordosis. Dynamic MRI in the position of neck flexion, extension and neutral position was done. MRI in neutral position [Figure 1] showed doubtful intramedullary hyperintensity in T2-weighted sections. Flexion MRI [Figure 2] showed forward displacement of posterior dural sac and revealed a T2-weighted hypointense space posterior to the dural sac which was getting corrected on neck extension [Figure 3]. The posterior space likely revealed posterior dural venous plexus and disappeared on the neck extension. The nerve conduction studies/electromyography (EMG) findings were in synchronicity with the MRI report with signs of chronic motor axon denervation with likely site being the AHC [Figure 4]. Clinical and radiological examination confirmed the presumptive diagnosis of HD due to the typical site of involvement at the AHC and forward shift of posterior dural sac on flexion MRI. The differential diagnosis of peripheral nerve entrapment and thoracic outlet syndrome was ruled out clinically and EMG studies. The patient received conservative management for 6 months in the form of hard cervical collar. The patient did not improve symptomatically and a poor compliance to the collar was suspected. Conservative management has been the mainstay of treatment in HD. However, in this case, we highlight the importance of posterior fixation without an attempt for fusion.

Operative intervention was planned in the form of posterior fixation using lateral mass screws to ensure limitation of neck flexion. No fusion or posterior decompression was planned as the disease has a self-limiting course after reaching a plateau. Under general anesthesia, Gardner-Wells tongs were applied and the patient was kept in prone position. Weights were attached to the tongs and cervical lordosis was confirmed on fluoroscopy. In the absence of a Mayfield head holder, tongs with minimal traction

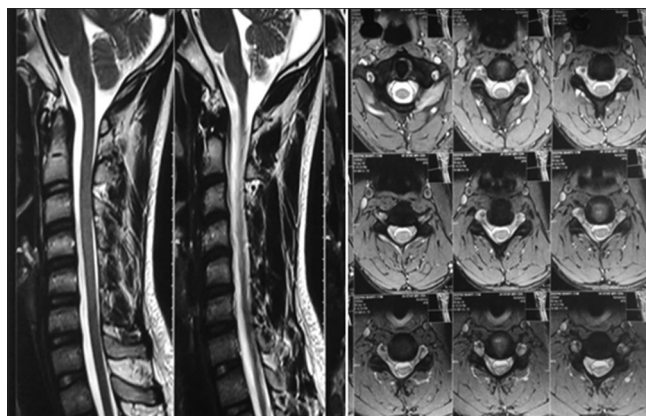


Figure 1: Magnetic resonance imaging in neutral position

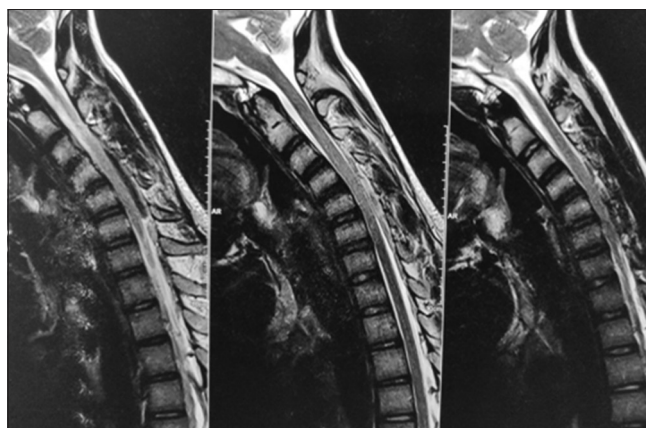


Figure 2: Posterior subdural sac is displaced forward on neck flexion, prominent epidural space noticed

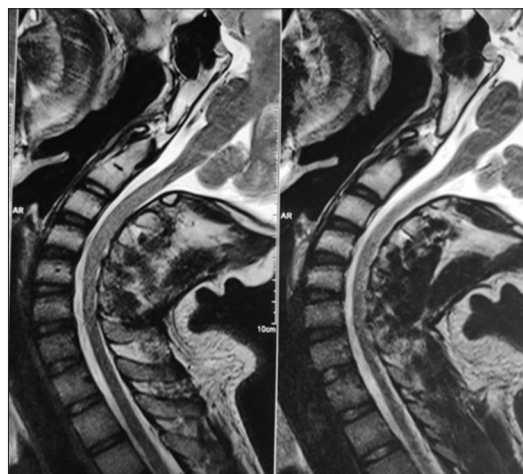


Figure 3: Correction of forward displacement of the posterior dural sac in extension magnetic resonance imaging

provide adequate stabilization of the head on the frame during surgical fixation. A midline posterior approach was taken. Skin, subcutaneous tissue, and fascia were incised; paraspinous muscles were lifted subperiosteally. Lateral mass screws were passed at C4, C5, and C6 vertebral levels. A contoured rod was passed to maintain neck position in lordosis [Figure 5]. Position, length of screws, and

neck alignment were confirmed on C-arm. The standard closure was done in layers over a negative suction drain. Postoperatively, the patient was given Philadelphia brace to maintain the neck position for 1 month [Figure 6]. Neurological improvement was noticed postoperatively and at 1 year follow-up patient has MRC Grade 5 motor power in wrist flexion and handgrip has improved along with maintained cervical lordosis.

Discussion

HD is a rare disease affecting primarily young men in second and third decades of life. It has been called differently as Juvenile atrophy of the distal upper extremity,^[1] monomelic amyotrophy,^[6] or juvenile asymmetric segmental spinal muscular atrophy. HD is characterized by the insidious onset of unilateral or asymmetric atrophy of hand and forearm with sparing of brachioradialis muscle giving a characteristic appearance of oblique amyotrophy^[7] involving C7, C8, and T1 myotomes. It is thought to be a kind of cervical myelopathy related to flexion movement of the neck.^[8] HD differs from classical types of motor neuron disease^[9] because of its nonprogressive course and pathologic finding of chronic microcirculatory changes in the territory of anterior spinal artery supplying the anterior horn cells of lower cervical cord.^[10] The etiopathogenesis of this disease is attributed to forward displacement of posterior wall of lower cervical dural canal in neck flexion causing marked and asymmetric flattening of lower cervical cord.^[8] Normal subjects may also show a forward shift of posterior dura in neck flexion however flattening or distortion of the cervical spinal cord does not occur and the average anterior displacement is <1 mm. The general course of the disease is benign with moderate-to-severe functional impairment. Patients with HD are not known to have abnormal anterior pathologies such as spondylotic spurs or disc herniations; therefore, removing any of these normal structures is not indicated in the management of these patients. The anterior shift of the posterior dura leads to engorgement of the posterior epidural plexus however an increased epidural pressure is not reported in these cases. The common presentation in these cases starts with a unilateral upper extremity involvement although bilateral involvement and lower limbs involvement is also rarely reported as anecdotal case reports. Some uncommonly reported symptoms are coarse irregular tremors in the affected hands (minipolymyoclonus) and transient worsening of symptoms on exposure to cold. There is absence of cranial nerve involvement or pyramidal tract involvement. Cerebellar involvement or bowel bladder dysfunction is not a typical finding in HD and should arouse suspicion to rule out other etiologies.

This patient presented to us with symptoms that were analogous to the diagnosis of HD which were confirmed with radiological imaging in the form of dynamic MRI. He already received treatment in the form of cervical

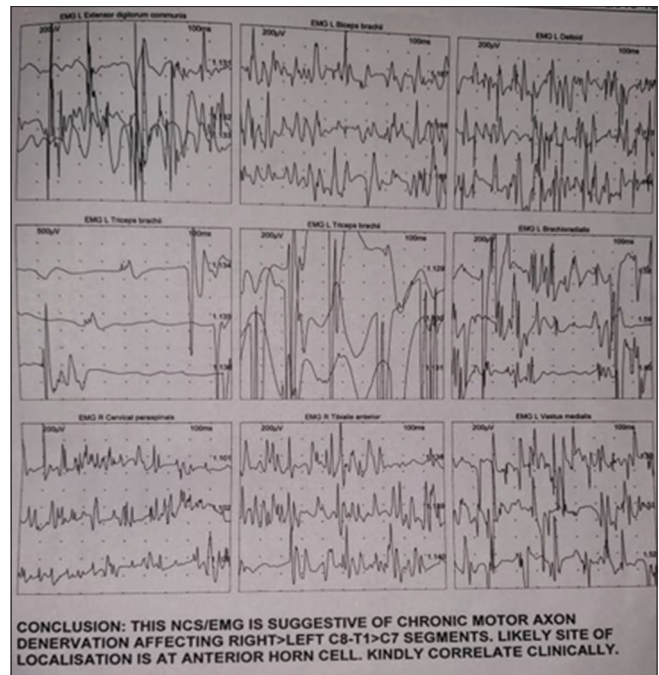


Figure 4: Nerve conduction studies/electromyography showing site of localization at the anterior horn cell

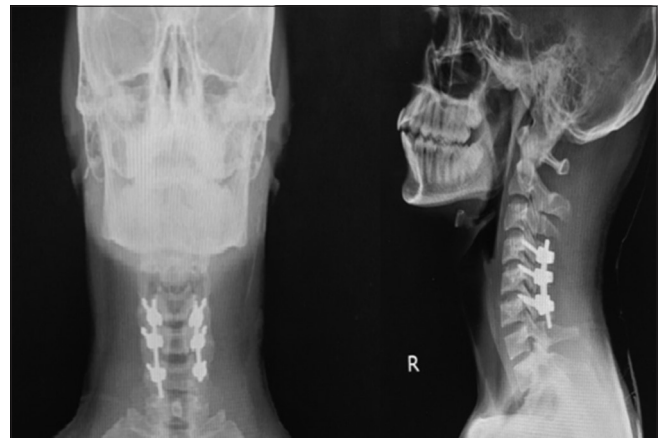


Figure 5: Postoperative plain radiograph

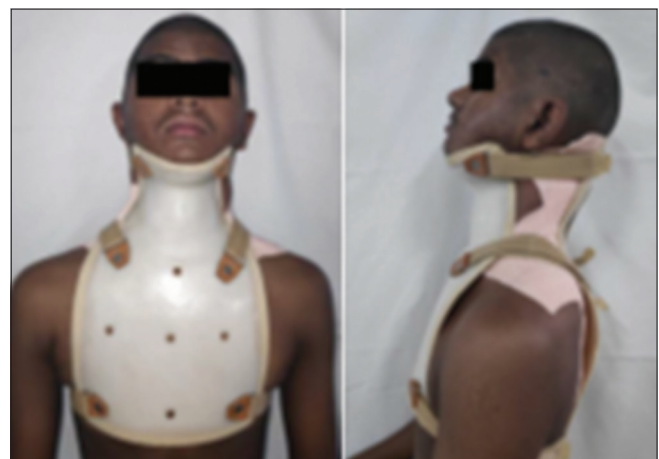

Figure 6: Postoperative brace wear to prevent neck flexion

collar which requires strict patient compliance with collar wear for a long duration. This allows continuation of microtrauma in case the patient is noncompliant leading to permanent cord damage.

Surgical intervention remains an option in patients who do not improve with cervical collar.^[11,12] Surgical treatment modalities include posterior cervical fixation without decompression and fusion, as described by Xu *et al.*^[13] To ensure limitation of neck flexion cervical spine fixation in lordotic position was done without decompression and fusion in our patient. It has a static course after an initial spurt of 2–5 years. Hence, it should be ensured that neck flexion is restricted to a minimum and surgical instrumentation without fusion may be an effective way to achieve the desired outcome. The instrumentation can later be reversed and hence adequate neck range of motion can be achieved once instrumentation is removed since there was no attempt of fusion during the surgery.

Cervical duraplasty with tenting sutures through laminoplasty^[14] is another described surgical technique. This technique leads to spinal cord decompression with the preservation of cervical alignment and local physiological motion in young patients with HD without major complications. Increased immunoglobulin E levels are often found associated with HD, which may lead to connective tissue changes partly explaining the clinical findings.

Conclusion

HD is a self-limited pathology, but it has to be differentiated early from other diseases that could determinate myelopathy and amyotrophy to establish a correct therapy and limit impairment of motor power. MRI is very important to confirm clinical suspect of HD, and a standardized MRI protocol using axial and sagittal images in both neutral and flexed position is needed to make diagnosis and to follow-up affected patients.

Declaration of patient consent

The authors certify that they have obtained all appropriate patient consent forms. In the form the patient(s) has/have given his/her/their consent for his/her/their images and other clinical information to be reported in the journal. The patients understand that their names and initials will not be published and due efforts will be made to conceal their identity, but anonymity cannot be guaranteed.

Financial support and sponsorship

Nil.

Conflicts of interest

There are no conflicts of interest.

References

- Hirayama K, Toyokura Y, Tsubaki T. Juvenile muscular atrophy of unilateral upper extremity; A new clinical entity. *Psychiatr Neurol Jpn.* 1959;61:2190-7.
- Chen CJ, Chen CM, Wu CL, Ro LS, Chen ST, Lee TH. Hirayama disease: MR diagnosis. *AJNR Am J Neuroradiol* 1998;19:365-8.
- Sonwalkar HA, Shah RS, Khan FK, Gupta AK, Bodhey NK, Vottath S, *et al.* Imaging features in Hirayama disease. *Neurol India* 2008;56:22-6.
- Tashiro K, Kikuchi S, Itoyama Y, Tokumaru Y, Sobue G, Mukai E, *et al.* Nationwide survey of juvenile muscular atrophy of distal upper extremity (Hirayama disease) in Japan. *Amyotroph Lateral Scler* 2006;7:38-45.
- Huang YC, Ro LS, Chang HS, Chen CM, Wu YR, Lee JD, *et al.* A clinical study of Hirayama disease in Taiwan. *Muscle Nerve* 2008;37:576-82.
- Yoo SD, Kim HS, Yun DH, Kim DH, Chon J, Lee SA, *et al.* Monomelic amyotrophy (Hirayama disease) with upper motor neuron signs: A case report. *Ann Rehabil Med* 2015;39:122-7.
- Hirayama K, Tokumaru Y. Cervical dural sac and spinal cord in juvenile muscular atrophy of distal upper extremity. *Neurology* 2000;54:1922-6.
- Kikuchi S, Shinpo K, Niino M, Higashi T, Tashiro K. Cervical myelopathy due to a “tight dural canal in flexion” with a posterior epidural cavity. *Intern Med* 2002;41:746-8.
- Anuradha S, Fanai V. Hirayama disease: A rare disease with unusual features. *Case Rep Neurol Med* 2016;2016:5839761.
- Hirayama K. Juvenile muscular atrophy of distal upper extremity (Hirayama disease): Focal cervical ischemic poliomyelopathy. *Neuropathology* 2000;20 Suppl:S91-4.
- Konno S, Goto S, Murakami M, Mochizuki M, Motegi H, Moriya H. Juvenile amyotrophy of the distal upper extremity: Pathologic findings of the dura mater and surgical management. *Spine (Phila Pa 1976)* 1997;22:486-92.
- Lin MS, Kung WM, Chiu WT, Lyu RK, Chen CJ, Chen TY. Hirayama disease. *J Neurosurg Spine* 2010;12:629-34.
- Xu Q, Gu R, Zhu Q, Suya D. A severe case of Hirayama disease successfully treated by posterior cervical fixation without decompression and fusion. *World Neurosurg* 2019;122:326-30.
- Ito H, Takai K, Taniguchi M. Cervical duraplasty with tenting sutures via laminoplasty for cervical flexion myelopathy in patients with Hirayama disease: Successful decompression of a “tight dural canal in flexion” without spinal fusion. *J Neurosurg Spine* 2014;21:743-52.