

Morphometric Evaluation of Craniocervical Junction by Magnetic Resonance Imaging Method

Abstract

Purpose: Morphometric evaluation of the craniocervical region using magnetic resonance imaging method in humans and determination of the reference values that could be used in various clinics were the aims of this study. **Materials and Methods:** In our study, 306 (95 males and 211 females) individuals who met the necessary criteria for anatomical structure were included and taken measurements afterward. Sagittal T1- and T2-weighted images were determined as a section thickness of 3 mm, an interval of 10 mm, a matrix of 352×224 , a field of view of 170–240 mm, and a number of excitations of 4. Measurements of anatomical structures in the craniocervical region were taken via these images. **Results:** Statistically significant differences were found among the findings of male and female individuals such as height of dens axis, anteroposterior distance of the dens axis (APDDA), anterosuperior distance of the dens axis (ASDDA), sagittal diameter of the foramen magnum (SDFM), total cervical vertebra length (TCVL), distance of spatium retropharyngeum, Pavlov ratio, and the ratio between sagittal diameter of canalis vertebralis (SDCV) to the APDDA. Dens axis height showed a positive correlation with ASDDA and TCVL, and a negative correlation was found between the APDDA and the spatium retropharyngeum. **Conclusion:** Age- and sex-related changes in the measurements of anatomical regions reveal that an increase and a decrease in the various parameters reveal that these are the normal changes presumably determined by the functional and physical demands varying on the columna vertebralis.

Keywords: Craniocervical junction, dens axis, foramen magnum, ligamentum apicis dentis, magnetic resonance imaging

Mukadder Sunar, Samet Kapakin¹

Department of Anatomy,
Faculty of Medicine, Erzincan
University, Erzincan,
¹Department of Anatomy,
Faculty of Medicine,
Atatürk University, Erzurum,
Turkey

Introduction

The craniocervical junction is a part of the columna vertebralis and is formed by the occipital bone, atlas, and axis. Cervical vertebrae are a problematical area in terms of instability and pain due to degenerative processes with increasing age, trauma, and some congenital anomalies. The anatomical features of the craniocervical region form the determinative structures of decompression and stabilization operations of this region.^[1] In recent years, more interventions in the pathologies of craniocervical junction have been possible in neurosurgical applications. A comprehensive understanding of the biomechanics of the craniocervical region is necessary for determining the strategy to correct the pathologies of the upper cervical spine. A better understanding of its biomechanics depends on the morphometric properties of the anatomical structures in this region.^[2,3]

The morphometry of this region should be well known to achieve success of the surgery and reduce the risk of complication because the anatomical structures in this region are vital and closely related to each other.

Materials and Methods

Subjects and image analysis

Individuals who were directed to the Radiology Department from different clinics for various reasons and required to be examined head and neck region by magnetic resonance imaging (MRI) were considered in our study. From this population, individuals who had normal imaging findings without any established diagnosis as stated within the patient file were accepted as healthy and included in the study. Individuals with a history of any chronic disease or operation were also not included in the study. Gender and age-related information of the cases were recorded and then proceeded with

Address for correspondence:
Dr. Mukadder Sunar,
Department of Anatomy,
Faculty of Medicine, Erzincan
University, Erzincan, Turkey.
E-mail: mukaddersunar@
hotmail.com

Access this article online

Website: www.asianjns.org

DOI: 10.4103/ajns.AJNS_293_17

Quick Response Code:



How to cite this article: Sunar M, Kapakin S. Morphometric evaluation of craniocervical junction by magnetic resonance imaging method. Asian J Neurosurg 2019;14:702-9.

This is an open access journal, and articles are distributed under the terms of the Creative Commons Attribution-NonCommercial-ShareAlike 4.0 License, which allows others to remix, tweak, and build upon the work non-commercially, as long as appropriate credit is given and the new creations are licensed under the identical terms.

For reprints contact: reprints@medknow.com

retrospective analysis. In our study, approximately 750 individuals' images obtained by MRI were evaluated at the Department of Radiology, which were incorporated in the archive system. Three hundred and six (95 males, 211 females) individuals who met the necessary criteria for anatomical structure were taken measurements afterward. While measurements were taken, care was taken to ensure that the anatomical formations were clear and the measurement points were formed by areas that would be unquestionable. Two different centers were utilized in our work. A total of 173 healthy individuals (47 males, 126 females) were measured at the Radiology Department of the Medical Faculty of Erzurum Atatürk University using MR scanner with magnetic field strength of 1.5 and 3 Tesla (T) (Avanto and Skyra, Siemens Healthcare, Enlargen, Germany). A total of 133 healthy individuals (48 males, 85 females) from the Radiology Unit of Niğde Public Hospital were measured using MR scanner (Gyrosan T5-NT Powertrak 1000; Philips, Best, Netherlands) with magnetic field strength of 1.5 T. Tesla is the unit of magnetic flux density or magnetic induction. It determines the density of the magnetic field. Of the 306 individuals selected from these two centers, 95 were male (20–79 age range, mean age is 45.3) and 211 were female (20–79 age range, mean age is 46.8). Individuals in the study were divided into five groups based on their age; 20–29, 30–39, 40–49, 50–59, and 60 and over [Table 1].

Images of the cervical region were obtained by scanners with a magnetic field strength of 3 and 1.5 T (Skyra and Avanto, Siemens Healthcare, Enlargen, Germany) in the first center and by a scanner with magnetic field strength 1.5 T (P Gyrosan T5-NT Powertrak 1000; Philips, Best, Netherlands) in the second center. Sagittal T1- and T2-weighted images were obtained. The section thickness, interval, matrix, field of view, and number of excitations were, respectively, determined 3 mm, 10 mm, 352 × 224, 170–240, and 4.

Anatomical parameters

The anatomical parameters were measured from the craniocervical region components [Figures 1-3]. The reference points defined during the measurements of the anatomical formations are determined as shown in Table 2. Then, distances between the determined points were measured via software that belongs to the central

computer Radiant DICOM Viewer 2.2.5 (64 bit, Medixant; Poznan/Poland) in the MRI system.

Statistical analysis

The results obtained at the end of the study were indicated as “mean ± standard deviation.” Calculations were made using the Windows-compatible IBM SPSS Statistics for Windows 20.0 (IBM Corp., Armonk, NY). Student's *t*-test was used in independent groups to compare male and female parameters according to sex. One-way analysis of variance (*post hoc* least significant difference test, if necessary) was used to compare the means for the five groups divided according to their age (20–29; 30–39; 40–49; 50–59; and 60 and over years). If $P < 0.05$, the difference was considered statistically significant.

Results

With the morphometric evaluation of these parameters, the height of the dens axis (HAD) of the male individuals was 33.8 ± 2.2 mm and the HAD of the female individuals was 30.9 ± 2.3 mm. The anteroposterior distance of the dens axis (APDDA) was 10.6 ± 1.1 mm in males and 9.8 ± 1.2 mm in females. When the anterosuperior distance of the dens axis (ASDDA) was measured, the anterosuperior distance was found to be 36.27 ± 2.9 mm in male and 35.97 ± 2.8 mm in female. The dens axis angle was $60.0^\circ \pm 4.2^\circ$ for males and $59.5^\circ \pm 3.9^\circ$ for females. The length of ligamentum apicis dentis was determined to be 9.5 ± 2.1 mm in males and 9.2 ± 2.0 mm in females. The sagittal diameter of medulla spinalis was found to be 7.8 ± 0.7 mm in males and 7.7 ± 0.6 mm in females. The sagittal diameter of canalis vertebralis (SDCV) was measured as 16.7 ± 2.0 mm for males and 16.4 ± 1.6 mm for females. The distance of spatium retropharyngeum (DSRP) was 3.1 ± 0.5 mm in male individuals and 2.9 ± 0.5 mm

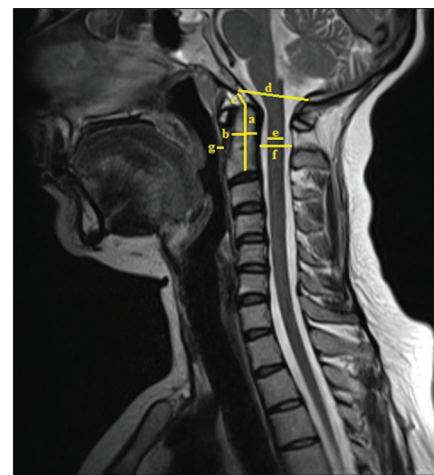


Figure 1: Sagittal image of the head and neck region obtained by magnetic resonance imaging, a: Dens axis height, b: Anteroposterior distance of the dens axis, c: The length of ligamentum apicis dentis, d: Sagittal diameter of the foramen magnum, e: Sagittal diameter of the medulla spinalis, f: Sagittal diameter of the canalis vertebralis, g: Distance of the spatium retropharyngeum

Table 1: Distribution of individuals based on age and genders

Age groups	Male	Female	Total
20-29	15	25	40
30-39	20	38	58
40-49	25	64	89
50-59	15	49	64
60 and over	20	35	55
Total	95	211	306

Table 2: The reference points defined during the measurements of the anatomical formations

Abbreviations	Anatomical formations	Reference points
DAH	Dens axis heighth	The distance between the center of the basis of the dens axis and the apex
APDDA	Anteroposterior distance of the dens axis	The distance measured anteroposteriorly from just above the remnant of intervertebral disc between C2 corpus and dens axis
ASDDA	Anterosuperior distance of the dens axis	The distance connecting the anterior end of the base of the body to the apex of the dens axis
DAA	Dens axis angle	The angle formed by the axis passing through the base of the body and the axis connecting the anterior end of the base to the apex of the dens axis
LLAD	The length of ligamentum apicis dentis	The section from the apex to basion of the dens
SDFM	Sagittal diameter of foramen magnum	The distance between opisthion and basion
SDCV	Sagittal diameter of canalis vertebralis	The widest part of the canalis vertebralis at the level of second cervical vertebra
SDMS	Sagittal diameter of medulla spinalis	The widest part of the medullary spinalis at the level of the second cervical vertebra
TLCV	Total length of cervical vertebrae	The distance from the apex of the dens to the basis of the corpus of the seventh cervical vertebra
DSRP	Distance of the spatium retropharyngeum	The distance between columna vertebralis and pharynx at the level of the second cervical vertebra
PR	Pavlov ratio	The ratio of the SDCV to the sagittal diameter of the corpus vertebra at the level of C3
	The ratio between SDCV and anteroposterior distance of dens axis	The ratio between SDCV and anteroposterior distance of dens axis
	The ratio between arches of atlas and anteroposterior distance of dens axis	Measurements were taken to determine the ratio between anterior and posterior arches of the atlas and the APDDA

in female individuals. Total length of the cervical vertebra was found to be 116.7 ± 7.3 mm in males and 106.6 ± 6.4 mm in females. The sagittal diameter of the foramen magnum (SDFM) was 38.0 ± 3 mm in males and 39.9 ± 2.9 mm in females. The Pavlov ratio was found to be 0.88 ± 0.1 for males and 0.94 ± 0.1 for females.

MRI measurements of female and male individuals revealed that differences between the dens axis height, the APDDA, the ASDDA, the SDFM, the total length of cervical vertebrae, the interval of spatium retropharyngeum, the Pavlov ratio, and the ratio of SDCV to the APDDA were statistically significant [Table 3].

As a result of the correlation analysis between the anatomical regions measured, dens axis height was found in a positive correlation with the ASDDA and the total cervical vertebra length. The ASDDA was also found in a positive correlation with the total length of cervical vertebrae [Table 4].

Discussion

In recent years, the craniocervical junction has become a region where neurosurgeons can be more interfered the pathologies. Anatomical studies, especially made in recent years, have made an important contribution to this situation. When we look at the previous studies, it is seen that certain populations were mainly taken aim and the radiological measurements made with advanced technology were repeated in the same populations. Measurements and variations of other populations may be overlooked. Thus, the risk of complications of different populations increases. Therefore, we believe that more comprehensive morphometric studies of different populations in today's world, where social mobility is increasing, may be effective in reducing the complication rates of surgical procedures. Important structures affected by lesions in this region include the muscles and ligaments that keep the axis and the occipital bone together, lower cranial nerves, upper spinal nerves, caudal part of the brainstem, rostral part of the spinal cord, vertebral arteries and branches, venules, dural sinuses, and atlas. When determining the surgical approach, the method that would uncover the lesion area and damage minimally the environmental structures should be preferred.^[4]

In our study, the HAD was measured and it showed a decrease in all decades except the increase in the fifth decade for men. It remained unchanged in almost all decades in females. It was determined that the values in male individuals were statistically significantly higher than female individuals. Kosif *et al.*^[5] reported that the HAD was 28.41 ± 4.9 mm for male individuals and 27.59 ± 4.2 mm for female individuals. Naderi *et al.*^[6] found that the HAD was 33.2 ± 2.9 mm. Grave *et al.*^[7] reported that the HAD was 33.8 ± 2.63 mm for Aboriginal males and 40.5 ± 2.13 mm for White males in their study,

comparing the cervicovertebral measurements between Austrian Aborigines and the White people. In the same study, the length was 31.8 ± 2.25 mm for Aboriginal

Table 3: Sex-based comparison of measurements of the structures in the craniocervical region

	Female (n=211)	Male (n=95)
DAH*	30.9±2.3	33.8±2.2
APDDA*	9.8±1.2	10.6±1.1
ASDDA*	35.0±2.1	38.5±2.6
DAA	59.5±3.9	60.0±4.2
LLAD	9.2±2.0	9.5±2.1
SDFM*	36.9±2.9	38.0±3.0
SDCV	16.4±1.6	16.7±2.0
SDMS	7.7±0.6	7.8±0.7
TLCV*	106.6±6.4	116.7±7.3
DSRP*	2.9±0.5	3.1±0.5
PR*	0.94±0.1	0.88±0.1
The ratio of the SDCV to the APDDA*	1.93±0.2	1.85±0.3
The ratio of arches of atlas to the APDDA	3.25±0.3	3.21±0.4

* $P < 0.05$. DAH – Dens axis height; APDDA – Anteroposterior distance of the dens axis; ASDDA – Anterosuperior distance of the dens axis; DAA – Dens axis angle; LLAD – The length of ligamentum apicis dentis; SDFM – Sagittal diameter of foramen magnum; SDCV – Sagittal diameter of canalis vertebralis; SDMS – Sagittal diameter of medulla spinalis; TLCV – Total length of cervical vertebrae; DSRP – Distance of the spatium retropharyngeum; PR – Pavlov ratio

women and 37.1 ± 2.14 mm for White women. Sengul and Kadioglu^[8] found the HAD to be 36.6 ± 2.3 mm. In this study, the HAD of the male individuals was 33.8 ± 2.2 mm and the HAD of the female individuals was 30.9 ± 2.3 mm. Differences between the HAD of previous studies and our study are due to technical differences using in anatomical and radiological measurements. The difference between our results and the results of Kosif *et al.*'s study can be explained by the fact that their lower image resolution owing to lower magnetic field (T) strength than ours.^[5]

When the APDDA was measured, the length in male individuals from the third decade to all other decades showed an increase. In female individuals, the APDDA increased except for the decrease in the fifth decade, and the difference between the both genders was statistically significant. Daher *et al.*^[9] found the APDDA to be 11.59 ± 0.76 mm in males and 10.20 ± 0.88 mm in females. Xu *et al.*^[10] reported the APDDA to be 10.3 ± 0.7 mm in males and 9.6 ± 0.9 mm in females. Sengul and Kadioglu^[8] determined the anteroposterior distance to be 11.02 ± 1.8 mm. Naderi *et al.*^[6] found the length to be 11.3 ± 1.0 mm. Tun *et al.*^[11] evaluated the measurements of the APDDA with both X-ray and computed tomography (CT). It was measured 11.8 ± 1.5 mm with X-ray and 11.3 ± 0.9 mm with CT and the difference was found to be statistically insignificant. Kandziora *et al.*^[12] reported an APDDA of 10.9 ± 0.81 mm in the study with 50 dry axis. In our study, the APDDA was 10.6 ± 1.1 mm

Table 4: Correlation between anatomical parameters in the craniocervical region

	DAH	APDDA	ASDDA	DAA	LLAD	SDMS	SDCV	DSRP	TLCV	SDFM
DAH	1									
APDDA	0.380 0.00*	1								
ASDDA	0.864 0.00*	0.386 0.00*	1							
DAA	0.130 0.02*	0.110 0.05*	-0.063 0.275	1						
LLAD	-0.080 0.160	0.010 0.830	-0.026 0.647	0.04 0.44	1					
SDMS	-0.010 0.870	-0.020 0.680	0.039 0.493	-0.08 0.16	-0.090 0.110	1				
SDCV	0.080 0.160	0.010 0.840	0.083 0.147	-0.08 0.16	0.020 0.750	0.140 0.02*	1			
DSRP	0.010 0.820	-0.130 0.02*	-0.008 0.891	-0.04 0.50	-0.100 0.090	0.070 0.220	0.040 0.470	1		
TLCV	0.740 0.00*	0.330 0.00*	0.644 0.00*	0.11 0.06	0.040 0.490	-0.020 0.780	0.040 0.500	0.07 0.21	1	
SDFM	0.150 0.01*	0.120 0.04*	0.200 0.00*	-0.06 0.32	0.440 0.00*	0.000 0.980	0.410 0.00*	-0.00 0.98	0.190 0.00*	1

* $P < 0.05$. DAH – Dens axis height; APDDA – Anteroposterior distance of the dens axis; ASDDA – Anterosuperior distance of the dens axis; DAA – Dens axis angle; LLAD – The length of ligamentum apicis dentis; SDFM – Sagittal diameter of foramen magnum; SDCV – Sagittal diameter of canalis vertebralis; SDMS – Sagittal diameter of medulla spinalis; TLCV – Total length of cervical vertebrae; DSRP – Distance of the spatium retropharyngeum

in males and 9.8 ± 1.2 mm in females. The mean APDDA of 306 individuals who were measured without sex discrimination was 10.06 ± 0.72 mm. According to these results, the APDDA in our study was found to be paralleled with the study of Xu *et al.*^[10] but lower than the measurements taken by Daher *et al.*^[9] with CT. It was determined that when the average was taken, the result was in line with the findings of Kandziora *et al.*^[12] and lower than the findings of Naderi *et al.*, Sengul and Kadioglu, and Tun *et al.*^[6,8,11]

When the ASDDA was measured, the anterosuperior distance was found to be 36.27 ± 2.9 mm in male and 35.97 ± 2.8 mm in female. Decreases in the ASDDA were found while age was going up in both genders. The HAD showed a decrease in all other decades except the increase in the fifth decade in males. It remained unchanged in nearly all decades in females. The values in male individuals were statistically significantly higher than those of female individuals. Tun *et al.*^[11] found that the ASDDA was 39.9 ± 5.1 mm with the X-ray, 38.0 ± 4.0 mm with the CT, and 37.6 ± 3.3 mm anatomically in the study performed on 20 dry C2 vertebrae. The values that Tun *et al.*^[11] reported were seen to be higher than the values we found in our study.

Another parameter measured in our study was the dens axis angle. Dens axis angle did not differ in age groups and both genders. Xu *et al.*^[10] found that the vertical angle of the dens axis was $64.2^\circ \pm 3.9^\circ$ as a result of measurements taken from 50 dry axis of 30 males and 20 females. Puchwein *et al.*^[13] reported an angle of $59.45^\circ \pm 3.45^\circ$ for the screw entry in odontoid fractures. Tun *et al.*^[11] evaluated the angle of the dens axis on X-ray and CT, and the difference between these two measurements, $64.2^\circ \pm 4.1^\circ$ in X-ray and $62.4^\circ \pm 4.7^\circ$ in CT, was found to be statistically significant. In our study, the dens axis angle was $60.0^\circ \pm 4.2^\circ$ for males and $59.5^\circ \pm 3.9^\circ$ for females. It was determined that this result is parallel to the studies of Puchwein *et al.*^[13] and lower than the angle values of the other studies.

Axis fracture involving odontoids which are responsible for 10%–18% of all cervical vertebra fractures is one of the most common causes of spinal injuries. This region is in charge of the segmental axial rotation of the neck region. This region which is injury prone has a huge importance in terms of biomechanics.^[14] Odontoid fractures are classified by Anderson and D'Alonzo^[15] in 1974 and separated into three groups. About 60% of the odontoid fractures that are separated into three subgroups are Type II fractures. Type II and superficial Type III fractures are accepted as unstable, and approximately 6% of them have a risk of disability and death.^[14] Anterior odontoid screw fixation is an important technique used in cases of odontoid fractures. With this technique, the broken odontoid part is pulled toward the corpus, and so, stabilization is obtained. Screw

length is very important for operation. Short screws are insufficient to pass the fracture line and cannot penetrate the tip of odontoid. The broken part of odontoid cannot be pulled till the corpus. Likewise, if the screw is long, it may damage vertebral artery and the neural tissue by drilling the odontoid tip. Therefore, to determine the HAD in genders and populations is important to reduce the risk of complications during surgical operations.^[11]

In odontoid fractures, the parameters such as HAD, angle of dens axis, anteroposterior distance, and anterosuperior distance are used to determine the length and number of the screw and the angle in the screwing technique with the lateral anterior approach. To designate these measurements in the Turkish population and to determine the reference points will be very important in the surgical operation before the operation. One of the important factors in the anterior odontoid screwing which is one of the surgical approaches used in cases of odontoid fractures is the APDDA. Although there are different considerations, such as using one or two screws for screwing, the high fusion ratio is not associated with the number of screws used.^[16] For the two-screw method, the external diameter of the odontoid should not be <9 mm^[11] so that two 3.5 mm screws can be inserted in the cortical direction. In our measurements, this value was determined as 10.6 ± 1.1 mm for males and 9.8 ± 1.2 mm for females and the mean was 10.06 ± 0.72 mm. It is important to know the APDDA to determine the number and width of the screws in cases of odontoid screw that will need to be performed in Turkish individuals.

In our study, the length of ligamentum apicis dentis was measured and the results were evaluated. Length measurements were higher in males than females and no age-related changes were detected in both genders. Panjabi *et al.*^[17] found the length of the apical ligament to be 23.5 mm. Tubbs *et al.*^[18] reported that the length of ligament was 7.5 mm in recent researches. Studies have also shown that this ligament is found in 80% of cadavers. In our study, the length of ligamentum apicis dentis was determined to be 9.5 ± 2.1 mm in males and 9.2 ± 2.0 mm in females. It was observed that these values in our study were higher than those of Tubbs *et al.*^[18] and lower than those found by Panjabi *et al.*^[17] When considering the correlation of the length of ligamentum apicis dentis with other anatomical parameters, a positive correlation between the SDFM and the length of ligamentum apicis dentis can be explained by the prolongation or shortening of the ligamentum apicis dentis which hold on to the basion depending on the growth or shrinkage of the foramen magnum.

The sagittal diameter of medulla spinalis was measured. In our study, sagittal diameter of the medulla spinalis was found to be 7.8 ± 0.7 mm in males and 7.7 ± 0.6 mm in females. Kosif *et al.*^[5] found that the sagittal diameter

of medulla spinalis was 8.25 ± 0.95 mm in females and 8.41 ± 1.18 mm in males at the level of C3 vertebra. The results of the study were found to be lower than those demonstrated by Kosif *et al.*^[5]

The sizes of the canalis vertebralis and corpus vertebralis are important in the treatment, prognosis, and diagnosis of medulla spinalis and cervical spinal diseases such as intraspinal tumors and spinal stenosis. Lindgren first emphasized the importance of the SDCV.^[19] The narrowness or wideness of the spinal canal is important for some pathological processes. Spinal stenosis is detected by narrowing of the spinal canal. Spinal stenosis can occur in two forms, congenital and degenerative. Congenital stenosis of the cervical vertebrae is caused by short peduncles. The primary underlying causes of this situation may be achondroplasia or Down syndrome. The cause of degenerative spinal stenosis is severe degenerative disc disease. Cervical spinal stenosis causes myelopathic symptoms. These symptoms include weakness in the extremities, gait abnormalities, reflex changes, and muscle atrophy. Spinal stenosis is usually characterized by a canal diameter of <13 mm. Patients with canal stenosis between 10 mm and 13 mm can be symptomatic; in other words, they are borderline. Spinal stenosis is certainly observed in patients with canal stenosis <10 mm. Patients with cervical spinal stenosis are prone to traumatic spinal cord injury and more severe degenerative changes. For this reason, to know the normal size of the SDCV and to determine for each population are very important for the surgical approaches of this region.^[19]

In our study which we evaluated the SDCV, the diameter was measured as 16.7 ± 2.0 mm for males and 16.4 ± 1.6 mm for females. While a rapid decline was observed in the sixth decade in male individuals, the decline in the fourth decade followed by an increase top to bottom in all groups in general in female individuals was observed. There are many studies examining the variation of the SDCV according to genders and populations. Kathole *et al.*^[20] found the sagittal diameter of the cervical spinal canal to be 16.93 ± 2.45 mm in males and 15.8 ± 1.81 mm in females in a study which conducted to measure the sizes of spinal canal and vertebrae via lateral cervical radiographic images of 100 individuals (50 males, 50 females). Gour *et al.*^[21] compared 100 radiographic images with 100 dry bones in a study which be conducted to compare the cervical vertebral canals via lateral cervical radiographs in dry bones. They found the diameter to be 16.69 ± 1.67 in radiological image of the cervical spinal canal and 14.38 ± 1.43 mm in dry bone. It was determined that our study was parallel to these studies.^[20,21]

One of the measured parameters is spatium retropharyngeum. In this study, the DSRP was 3.1 ± 0.5 mm in male individuals and 2.9 ± 0.5 mm in female individuals.

It was determined that this difference between male and female individuals was statistically significant. The width of this space varies from 3 to 7 mm. Stephen and Arthur^[22] stated that the width of this area should be approximately 2–5 mm. The retropharyngeal space enlarges in the cases of spinous fractures of the cervical vertebrae. However, normal values match up with abnormal values significantly. Retropharyngeal swelling (6 mm in C2, 22 mm and over in C6) is specific in cases of spinous fractures of the vertebrae. Soft tissue swelling in symptomatic patients should be considered as an indicator for further radiological evaluation.^[22]

Total length of the cervical vertebra was measured. As a result of the measurements, total length of the cervical vertebra was found to be 116.7 ± 7.3 mm in males and 106.6 ± 6.4 mm in females. The length of the cervical vertebrae of male individuals was found to be statistically significantly higher than that of female individuals. Kosif *et al.*^[5] measured the total length of the cervical vertebrae of 93 male and 101 female individuals and found that the length was 104.46 ± 8.03 mm in males and 96.71 ± 6.97 mm in females. They found that this difference was statistically significant.

Decrease in the height of the cervical vertebrae leads to flattening of the cervical lordosis with age and thus kyphosis. The risk of spinal stenosis and the effort of the extensor muscles also increase as a result of the increase in kyphosis. It has also been found that the cervical vertebra flattened in a clear majority of patients with headache. Therefore, the risk of flattening the cervical lordosis and kyphosis is expected to be higher in women than in men.^[5]

The SDFM has clinically importance due to compressing the vital organs passing through it and the life-threatening situation in cases of brain hernias and achondroplasia. Significant structures affected by lesions in this region include the lower cranial nerves, upper spinal nerves, caudal part of brainstem, rostral part of spinal cord, vertebral arteries and branches, venules, dural sinuses, and muscles and ligaments that hold atlas, axis, and occipital bone together.^[23] Another parameter used in our study is the SDFM. In general, a decline in SDFM was seen in females in all decades. In females, the diameter decreased continuously, except for the fifth decade with increasing age. Similarly, in males, a decrease in the SDFM was observed in all groups including the individuals in the seventh decade and over.

There are studies reported that the sex has an effect on the SDFM. Galdames *et al.*^[24] made anteroposterior measurements of 215 dry craniums in 144 male and 71 female individuals. They found that the diameter of foramen magnum was 36.5 ± 2.6 mm in males and 35.6 ± 2.5 mm in females. Gruber *et al.*^[25] measured the SDFM as 37.1 ± 2.7 mm for males and 35.8 ± 3.5 mm for females in a study examining the sex-related

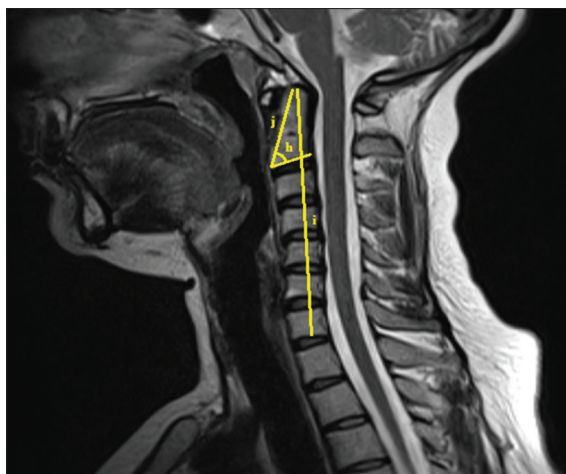


Figure 2: Sagittal Image Of The Head And Neck Region Obtained By Magnetic Resonance Imaging, h: Dens Axis Angle, i: Total Length Of Cervical Vertebrae, j: Anterosuperior Distance Of The Dens Axis

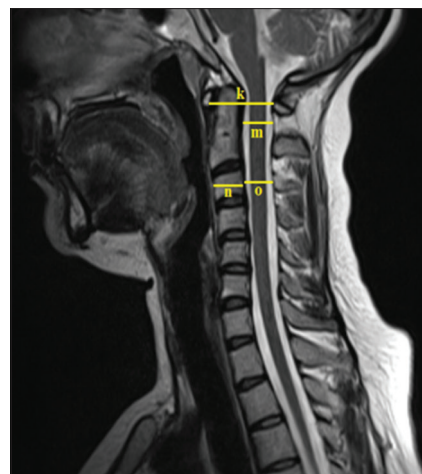


Figure 3: Sagittal Image Of The Head And Neck Region Obtained By Magnetic Resonance Imaging, k: The Distance Between Arches Of Atlas, m: Sagittal Diameter Of C2 Canalis Vertebralis, n: Sagittal Diameter Of C3 Corpus, o: Diameter Of C3 Canalis Vertebralis

changes of the SDFM with dry craniums of 28 male and 21 female individuals. Radhakrishna *et al.*^[26] measured the anteroposterior diameter of foramen magnum on 100 dry craniums which belong to 55 male and 45 female individuals from South Indian populations. The anteroposterior diameter of foramen magnum was 34.04 ± 2.36 mm in males and 31.72 ± 2.14 mm in females. The results of all these studies show parallelism with our results. It has been found that the SDFM is significantly higher in males than female individuals. Manoel *et al.*^[27] found that the anteroposterior diameter of foramen magnum was 35.1 ± 0.33 mm in females and 35.7 ± 0.29 mm in males as a result of examinations on 215 craniums of 76 females and 139 males in another study. The results of this study indicated that although the sagittal diameter was larger in males than in females, the effect of the gender factor was not statistically significant.

There are some studies that investigate the differences of the SDFM between various populations. Osunwoke *et al.*^[28] determined the sagittal diameter measurements of foramen magnum and measured 120 dry craniums from the Southern Nigerian population. As a result of this study, the diameter of foramen magnum was found to be 36.1 ± 2.60 mm for this population. In another study, Chethan *et al.*^[23] found the anteroposterior distance of foramen magnum to be 31.0 ± 2.4 mm as a result of measurements on 53 craniums from Indian population.

Differences between radiological and anatomical measurements, or even differences between radiological images, may be due to the differences in the shape of the foramen magnum between races and genders as well as the techniques used in the studies.^[23]

Another parameter used in our study is the Pavlov rate. The Pavlov ratio was found to be 0.88 ± 0.1 for males and 0.94 ± 0.1 for females as a result of calculations made. Tosse^[29] has calculated the Pavlov ratio using

55 CT images of 27 males and 28 females and found that the ratio was 0.83 ± 0.13 in males and 0.92 ± 0.14 in females. Kathole *et al.*^[20] have determined the Pavlov ratio of the Indian population in their study. As a result of this study, the ratio was 0.95 ± 0.06 for males and 1.06 ± 0.06 for females. Measurement of the sagittal diameter of the spinal canal in this region has been determined to be a reliable method for the detection of medulla spinalis injuries or cervical spinal stenosis. It can be said that the data obtained from this study have paralleled with other studies and that the risk of stenosis is higher in males than in females. The sex-related differences in the shape of the cervical spinal canal may be acknowledged among the causes of this situation.^[20] The Pavlov ratio leading to cervical spinal stenosis is lower than 0.77 in males and 0.88 in females. If this ratio is higher than 1.13 in males and 1.24 in females, it causes space-occupying lesions.^[20]

As we have observed that in our study, the changes in the measurements of anatomical regions in relation of age and gender, the increase and decrease in the various parameters reveal that these are the normal changes presumably determined by the functional and physical demands varying on the columna vertebralis.^[30]

Using these parameters, it may be possible to facilitate diagnosis, to increase the success of the surgical interventions to be performed, and to reduce the risk of complications in pathologies of the craniocervical junction.

Acknowledgment

We confirm that we have read the Journal's position on issues involved in ethical publication and affirm that this report is consistent with those guidelines.

Financial support and sponsorship

Nil.

Conflicts of interest

There are no conflicts of interest.

References

- Ovalioglu C. Morphometric properties of craniocervical compound. Bakırköy Prof. Dr. Mahzar Osman Mental Health and Neurological Disorders Education and Research Hospital. İstanbul, Turkey; 2005.
- Birgili B. Surgical Anatomic Evaluation of Human Cervical Vertebra Pedicles: A Cadaveric Study. Edirne, Turkey: Trakya University Faculty of Medicine; 2007.
- Clark JG, Abdullah KG, Mroz TE, Steinmetz MP. Biomechanics of the Craniovertebral Junction, Biomechanics in Applications; 2013. Available from: <https://www.intechopen.com/books/biomechanics-in-applications/biomechanics-of-the-craniovertebral-junction>. [Last accessed 2018 Mar 15].
- Rhoton LA. Rhoton: Cranial Anatomy and Surgical Approaches. 1st ed. Philadelphia: Lippincott Williams & Wilkins; 2007. p. 165-6.
- Kosif R, Huvaj S, Abanonu HE. Morphometric analysis of occipitocervical region and cervical height in the female and male. *Gulhane Med J* 2007;49:173-7.
- Naderi S, Arman C, Güvencer M, Korman E, Senoğlu M, Tetik S, *et al.* Morphometric analysis of the C2 body and the odontoid process. *Turk Neurosurg* 2006;16:14-8.
- Grave B, Brown T, Townsend G. Comparison of cervicovertebral dimensions in Australian aborigines and caucasians. *Eur J Orthod* 1999;21:127-35.
- Sengul G, Kadioglu HH. Morphometric anatomy of atlas and axis vertebra. *Turk Neurosurg* 2006;16:69-76.
- Daher MT, Daher S, Nogueira-Barbosa MH, Defino HL. Computed tomographic evaluation of odontoid process: Implications for anterior screw fixation of odontoid fractures in an adult population. *Eur Spine J* 2011;20:1908-14.
- Xu R, Nadaud MC, Ebraheim NA, Yeasting RA. Morphology of the second cervical vertebra and the posterior projection of the C2 pedicle axis. *Spine (Phila Pa 1976)* 1995;20:259-63.
- Tun K, Kaptanoglu E, Cemil B, Yorubulut M, Karahan ST, Tekdemir I, *et al.* Anatomical study of axis for odontoid screw thickness, length, and angle. *Eur Spine J* 2009;18:271-5.
- Kandziora F, Schulze-Stahl N, Khodadadyan-Klostermann C, Schröder R, Mittlmeier T. Screw placement in transoral atlantoaxial plate systems: An anatomical study. *J Neurosurg* 2001;95:80-7.
- Puchwein P, Jester B, Freytag B, Tanzer K, Maizen C, Gumpert R, *et al.* The three-dimensional morphometry of the odontoid peg and its impact on ventral screw osteosynthesis. *Bone Joint J* 2013;95-B:536-42.
- Ozer AF, Cosar M, Oktenoglu TB, Sasani M, Iplikcioglu AC, Bozkus H, *et al.* A new transodontoid fixation technique for delayed type II odontoid fracture: Technical note. *Surg Neurol* 2009;71:121-5.
- Anderson LD, D'Alonzo RT. Fractures of the odontoid process of the axis. *J Bone Joint Surg Am* 1974;56:1663-74.
- Jenkins JD, Coric D, Branch CL Jr. A clinical comparison of one- and two-screw odontoid fixation. *J Neurosurg* 1998;89:366-70.
- Panjabi M, Dvorak J, Crisco J 3rd, Oda T, Hilibrand A, Grob D, *et al.* Flexion, extension, and lateral bending of the upper cervical spine in response to alar ligament transections. *J Spinal Disord* 1991;4:157-67.
- Tubbs RS, Grabb P, Spooner A, Wilson W, Oakes WJ. The apical ligament: Anatomy and functional significance. *J Neurosurg* 2000;92:197-200.
- Lindgren E. The importance of the sagittal diameter of the spinal canal in the cervical region. *Nervenarzt* 1937;10:240-52.
- Kathole MA, Joshi RA, Herekar NG, Jadhav SS. Dimensions of cervical spinal canal and vertebrae and their relevance in clinical practice. *Int J Resent Sci Res* 2012;3:54-8.
- Gour KK, Shrivastava SK, Thakare AE. Size of cervical vertebral canal-measurements in lateral cervical radiographs & dried bones. *Int J Biol Med Res* 2011;2:778-80.
- Stephen MF, Arthur CC. Whiplash Injuries: The Cervical Acceleration/Deceleration Syndrome. 3th ed. Philadelphia: Lippincott Williams & Wilkins; 2002. p. 219-21.
- Chethan P, Prakash KG, Murlimanju BV, Prashanth KU, Prabhu LV, Saralaya VV, *et al.* Morphological analysis and morphometry of the foramen magnum: An anatomical investigation. *Turk Neurosurg* 2012;22:416-9.
- Galdames IC, Russo PP, Matamala DA, Smith RL. Sexual dimorphism in the foramen magnum dimensions. *Int J Morphol* 2009;27:21-3.
- Gruber P, Henneberg M, Böni T, Rühli FJ. Variability of human foramen magnum size. *Anat Rec (Hoboken)* 2009;292:1713-9.
- Radhakrishna SK, Shivarama CH, Ramakrishna A, Bhagya B. Morphometric analysis of foramen magnum for sex determination in South Indian population. *Nitte Univ J Health Sci* 2012;2:20-2.
- Manoel C, Prado FB, Caria PH, Groppo FC. Morphometric analysis of the foramen magnum in human skulls of Brazilian individuals: Its relation to gender. *Braz J Morphol Sci* 2009;26:104-8.
- Osunwoke EA, Oladipo GS, Gwunireama IU, Ngaokere JO. Morphometric analysis of the foramen magnum and jugular foramen in adult skulls in Southern Nigerian population. *J Sci Ind Res* 2012;3:446-8.
- Tossel G. Dimensions of the Cervical Spinal Canal in the South African Negroid Population. South Africa: University of Pretoria School of Medicine, Faculty of Health Science, Pretoria; 2007.
- Amonoo-Kuofi HS. Morphometric changes in the heights and anteroposterior diameters of the lumbar intervertebral discs with age. *J Anat* 1991;175:159-68.