

Single Stage 360° Correction of Fixed Cervical Deformity with Anterior and Posterior Ankyloses

Sir,

A 69-year-old female with significant past medical history of polio and neuromuscular scoliosis status post noninstrumented thoracolumbar fusion presented with gradually progressive severe cervical spinal kyphosis to the extent that she had difficulty maintaining upright gaze. She had subtle signs of myelopathy but was otherwise neurologically intact. Imaging with upright cervical spine X-rays, magnetic resonance imaging (MRI) and computed tomography demonstrated fixed cervical kyphotic deformity with the presence of ankyloses both anteriorly and posteriorly [Figure 1]. She underwent surgery through a single stage 360° approach with anterior osteotomy and release with the placement of standalone intervertebral polyetheretherketone cages with integrated fixation followed by posterior release and instrumented fusion [Figure 2]. The standalone device was secured with only a single screw after anterior osteotomy to allow further lordosing the spine after posterior release of the fused facet joints. An excellent restoration of cervical spine alignment with correction of deformity was achieved [Figure 2].

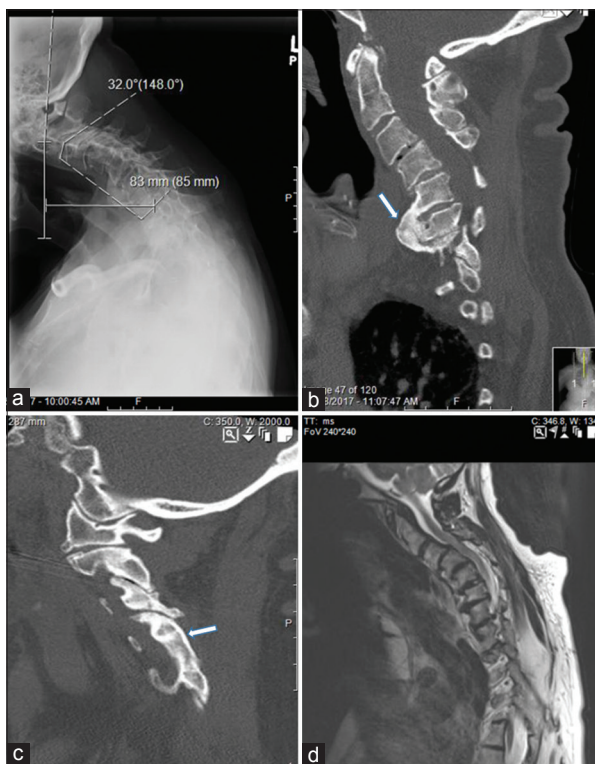


Figure 1: Upright lateral cervical spine X-ray (a) sagittal computed tomography (b and c) and sagittal T2-weighted magnetic resonance imaging (d) demonstrating fixed cervical kyphotic deformity with presence of ankyloses both anteriorly and posteriorly. (arrows in image b and c) and cervical spinal cord compression (d) There is presence of 32° of cervical kyphosis between C2–C7 and about 8 cm C2–C7 sagittal vertical axis

Adult spinal deformity has become an increasingly common pathology encountered and treated by spine surgeons secondary to the increasing life expectancy and expectations of elderly patients to remain functional so as to maintain a reasonably active lifestyle and quality of life (QOL). There has been an outburst of advancement in the management of thoracolumbar adult spinal deformity in the past decade or so. In contrast to thoracolumbar deformities, considerably less progress has been made in the study of adult cervical deformity. Recent studies have shown that symptomatic cervical deformity impacts QOL to a degree comparable to or more than a number of chronic diseases.^[1] The most common forms result from degenerative spondylotic and inflammatory arthropathies or iatrogenic conditions and can produce “chin-on-chest” deformities that can substantially impact fundamental functions, including horizontal gaze, swallowing, and breathing often necessitating surgical treatment. The surgery for adult cervical spine deformity remains challenging with no major advances involving the principles of corrective surgery. A number of the algorithm have been proposed in the past with the main distinction being between flexible and rigid deformity leading to the selection of either anterior alone, posterior alone, combined anteroposterior or posterior-anterior-posterior approach based mainly on the presence or absence of ankyloses and its location.^[2] It has been fairly agreed on that a fixed deformity with a posterior ankylosis needs a posterior release first thus requiring a 540° approach with posterior osteotomy followed by anterior release with interbody grafting followed by posterior instrumentation and fusion thus requiring two flips during surgery and increased

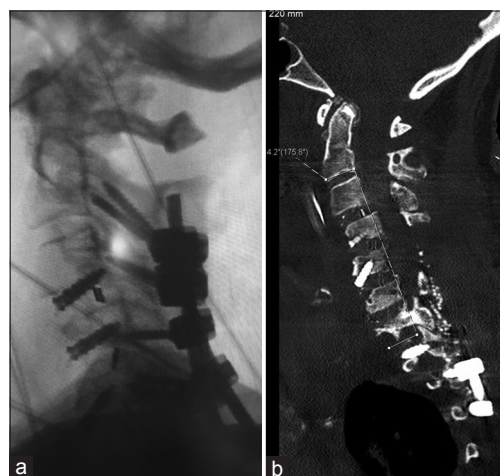


Figure 2: Lateral X-ray (a) and sagittal computed tomography (b) of the cervical spine showing restoration of cervical lordosis and C2–C7 sagittal vertical axis

overall operative time with its associated morbidity and remains the most common approach for treated cervical deformity with posterior ankylosis.^[2] Kim *et al.* have popularized and have described in great detail the anterior osteotomy techniques to allow correction of complex cervical fixed deformity that when appropriately combined with posterior release can be utilized to treat fixed cervical deformity with even posterior ankylosis through a 360° approach.^[3] This cases have been reported mainly from the same author questioning the wider applicability of the technique. This case illustrates a patient with severe cervical deformity with the presence of ankyloses both anteriorly and posteriorly treated via a standard 360° approach. While the details of the surgery can be read elsewhere,^[3] the key intraoperative steps involved anterior osteotomy followed by placement of wider interbody cage or graft with a smaller height and univertebral fixation followed by posterior release and instrumented fusion. Implants with slightly less height and univertebral fixation help maintain slight flexibility in the spine thus allowing further lordosis after the posterior release. The importance of utilizing open Jackson table with head supported in the Gardner wells tongs with bivectoral traction cannot be overemphasized.

Declaration of patient consent

The authors certify that they have obtained all appropriate patient consent forms. In the form the patient(s) has/have given his/her/their consent for his/her/their images and other clinical information to be reported in the journal. The patients understand that their names and initials will not be published and due efforts will be made to conceal their identity, but anonymity cannot be guaranteed.

Financial support and sponsorship

Nil.

Conflicts of interest

There are no conflicts of interest.

Manish Kumar Kasliwal

Department of Neurosurgery, University Hospitals Cleveland Medical Center, Case Western Reserve University School of Medicine, Cleveland, OH, USA

Address for correspondence: Dr. Manish Kumar Kasliwal, Department of Neurosurgery, University Hospitals Cleveland Medical Center, Case Western Reserve University School of Medicine, Euclid Avenue, 11100, Cleveland, OH, USA.
E-mail: manish.kasliwal@uhhospitals.org

References

1. Passias PG, Jalai CM, Smith JS, Lafage V, Diebo BG, Protosaltis T, *et al.* Characterizing adult cervical deformity and disability based on existing cervical and adult deformity classification schemes at presentation and following correction. *Neurosurgery* 2018;82:192-201.
2. Hann S, Chalouhi N, Madineni R, Vaccaro AR, Albert TJ, Harrop J, *et al.* An algorithmic strategy for selecting a surgical approach in cervical deformity correction. *Neurosurg Focus* 2014;36:E5.
3. Kim HJ, Piyaskulkaew C, Riew KD. Anterior cervical osteotomy for fixed cervical deformities. *Spine (Phila Pa 1976)* 2014;39:1751-7.

This is an open access journal, and articles are distributed under the terms of the Creative Commons Attribution-NonCommercial-ShareAlike 4.0 License, which allows others to remix, tweak, and build upon the work non-commercially, as long as appropriate credit is given and the new creations are licensed under the identical terms.

Access this article online	
Quick Response Code: 	Website: www.asianjns.org
	DOI: 10.4103/ajns.AJNS_2_18

How to cite this article: Kasliwal MK. Single stage 360° correction of fixed cervical deformity with anterior and posterior ankyloses. *Asian J Neurosurg* 2019;14:612-3.

© 2019 Asian Journal of Neurosurgery | Published by Wolters Kluwer - Medknow