

Modified Inside-outside Occipito-Cervical Plate System: Preliminary Results

Abstract

Context: Internal rigid fixation provides immediate stability of the occipito-cervical (OC) junction for treatment of instability; however, in current practice, the optimal OC junction stabilization method is debatable. **Aims:** The aim of this study to test the safety and efficacy of a newly designed modified inside-outside occipito-cervical (MIOOC) plate system for the treatment of instability. **Settings and Design:** This was a feasibility study of MIOOC plate system. **Subjects and Methods:** Five male and four female patients with OC instability were treated using MIOOC plate system. Stabilization rate, safety, and efficacy were evaluated radiologically and clinically. **Results:** Mean age of the patients was 35 ± 11 (range: 22–58) years. Etiology of OC instability included trauma, neoplasm, congenital abnormalities, and iatrogenic. The fusion levels ranged from occiput-C3 to occiput-C6. Mean follow-up duration was 22 ± 10 (range: 6–46) months. There were neither complication nor was there any need for plate revision or screw pullout. Mortality occurred in one patient due to primary malignancy at 6 months; otherwise, no morbidity was observed. During the follow-up, no recurrent subluxation or newly developed instability at adjacent levels occurred. All patients showed a satisfactory union at the most recent follow-up examination. **Conclusions:** These preliminary results suggest that the MIOOC plate system is a useful and safe method for providing immediate internal stability of the OC junction. Using a multi-piece plate design in this plate system provided easy implantation and a better interface between plate and OC bones. Further, clinical studies and long-term results are needed to determine the reliability of the MIOOC plate system.

Keywords: Biomechanical system, C1–C2 fixation, craniovertebral junction, inside-outside, multi-piece plate, occipito-cervical

Introduction

Occipito-cervical (OC) anatomy consists of a complex biomechanical system which encases vital structures. Many pathological conditions such as neoplasm, rheumatic diseases, trauma, infection, and congenital disorders may lead to neural compression with or without OC instability.^[1-3] In such occurrences, fusion is almost always needed as a part of surgical interventions on the craniovertebral junction.^[1,4-11] Since the first description of posterior OC fusion in 1927 by Foerster, only the technique of OC fusion with autograft has been reported effective for fixation of OC instability.^[4,8,9,11-13] Many techniques have been suggested for stabilization and instrumentation of OC fusion. However, weak biomedical strength and lack of immediate rigid fixation on OC fusion have challenged surgeons to develop new device systems for successful stabilization. The

This is an open access journal, and articles are distributed under the terms of the Creative Commons Attribution-NonCommercial-ShareAlike 4.0 License, which allows others to remix, tweak, and build upon the work non-commercially, as long as appropriate credit is given and the new creations are licensed under the identical terms.

For reprints contact: reprints@medknow.com

development of plate and screw systems has done much to enhance the stability of internal fixation.^[1,4-14] However, there is still no consensus on the optimal method of OC fusion. This study presents a new modified plate system with a combined inside-outside occipital screwing technique for OC fusion.^[13,15] The authors discuss the usefulness of this novel designed plate system and review their preliminary clinical results. One of the main strengths of the method is its compatibility with current screw and rod fixation systems.

Subjects and Methods

Nine consecutive patients with OC instability due to trauma, malignancy, or congenital malformation were enrolled into this study; Informed consent was obtained from all patients. A novel modified inside-outside occipito-cervical (MIOOC) plate system was used for OC arthrodesis on each of the nine cases. Stabilization

How to cite this article: Caglar S, Turkoglu E, Kertmen H, Gurer B, Bozkurt H, Ozay R, *et al.* Modified inside-outside occipito-cervical plate system: Preliminary results. *Asian J Neurosurg* 2019;14:148-53.

**Sukru Caglar,
Erhan Turkoglu¹,
Hayri Kertmen¹,
Bora Gurer²,
Huseyin Bozkurt³,
Rafet Ozay¹,
Sahin Hanalioglu¹,
Efkan Colpan⁴**

Department of Neurosurgery, Ankara University, School of Medicine, ¹Department of Neurosurgery, University of Health Sciences, Diskapi Yildirim Beyazit Training and Research Hospital, Neurosurgery Clinic, Ankara, ²Department of Neurosurgery, Ministry of Health, University of Health Sciences, Fatih Sultan Mehmet Training and Research Hospital, Neurosurgery Clinic, Istanbul, ³Department of Neurosurgery, Cumhuriyet University, School of Medicine, Sivas, Turkey, ⁴Department of Neurological Surgery, UPMC Hamot, Erie, PA, USA

Address for correspondence:
Prof. Erhan Turkoglu,
Cukuramber Mah. Ogretmenler
Cad. Kardelen Apt. No. 5/6,
Cankaya 06290, Ankara, Turkey.
E-mail: drmet122@yahoo.com

Access this article online

Website: www.asianjns.org

DOI: 10.4103/ajns.AJNS_305_17

Quick Response Code:



rate and usefulness of this plate system were evaluated radiologically and clinically. Patients' history, neurological examinations, X-ray evaluations (lateral, anteroposterior, hyperflexion, and hyperextension), Frankel grades, computed tomography (CT) or MRI scans were included in data collection. Fusion levels were ranged from occiput-C3 to occiput-C6. During the postoperative courses, all patients were routinely evaluated both clinically and radiologically at the 1st month, 3rd month, and 1 year after surgery.

Definition of the modified plate system

The MIOOC plate system was designed for posterior internal fixation. The design was aimed for easy implantation and better interfacing between the plate and bone surfaces. The classic single piece plate is divided into two pieces. The separate occipital and cervical plates in this design are connected with small adjustable size rod allowing fixation without rod bending [Figure 1a-c]. The occipital connection was curved to fit the occipital outer surface for making increased contact surface between bone and plate [Figure 1a, d and e]. Multiple screw holes were created on both occipital and cervical pieces of the plate system which allow easy screw insertion and/or wire securing to the spine [Figure 1a and c]. The connection between occipital and cervical plate pieces was made using a 3 mm diameter rod connection [Figure 1b]. Bolts were used for securing rod attachments between plate pieces allowing appropriate and adjustable connections [Figure 1d and e]. The occipital portion of the plate was anchored onto the occipital bone using inside-outside screwing technique, and the cervical piece of the plate system was placed by lateral mass screw fixation. Occipital bone was decorticated around the midline to provide a wide fusion bed. Biomechanical analysis of the plate system revealed axial force on the rod and plate to be approximately 2285 N, and the force required for the plate rotation on the rod was approximately 28 N.




Figure 1: The figure shows modified inside-outside occipito-cervical plate system. (a) Occipital piece of the plate system. (b) Connector rod for occipito-cervical connection. (c) Cervical piece of the plate system. (d) Lateral view of the plate system. (e) The rod connector system provides adjustable plate length

Surgical procedure

The patients were positioned prone using cushions under the chest. The head was fixed with a Mayfield head holder in the natural anatomical position by fluoroscopic guidance. The surgical area was cleaned and draped. A vertical midline incision was performed between the occipital protuberance and fusion level. The nuchal ligament was dissected by linear incision. Occipital and cervical muscles were reflected by subperiosteal dissection and retracted laterally to expose the bony structures. Surgical dissection was extended laterally for further exploration of the lateral masses and visualization of the horizontal segment of the vertebral artery. Instrumentation was performed in three steps after occipital and cervical dissections:

Inside-outside screw placement and insertion of the occipital piece of the plate system

Appropriate plate size was chosen to allow for a firm connection with the occipital surface. Inside-outside screw locations were chosen on thicker parts of the occipital bone,^[14,16,17] and two entry holes were created in the occipital skull by the high-speed drill. Dura mater was identified and keyways were made by Kerrison rongeur and high-speed drill [Figure 2a]. The inside-outside screws were placed carefully in the epidural space, and the occipital piece of the plate system was firmly fixed onto the occipital bone by inside-outside screw placement [Figure 2a].

Insertion of the cervical piece of the plate system

The cervical piece of the plate was fitted to ensure the levels of the stabilization. Lateral masses were identified, and transarticular screw holes were created in the superior lateral quadrants of the lateral mass bodies by the high-speed drill. The drill trajectory was checked by fluoroscopy. Screw length was determined by tapping. The cervical piece of the plate was fixed onto cervical bones by transarticular facet screw placement technique.

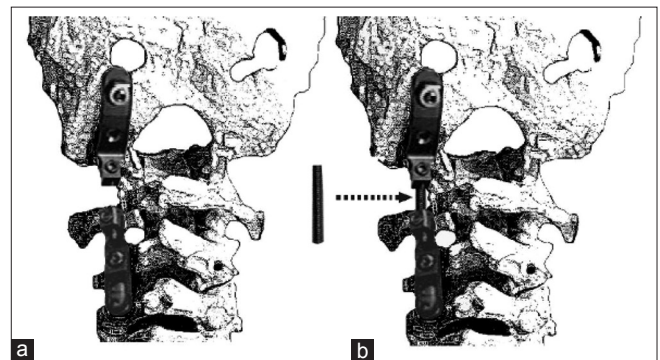


Figure 2: Illustration depicts implantation of the modified inside-outside occipito-cervical plate system. (a) Occipital piece of the plate system is fixed onto the occipital bone by inside-outside occipital screw technique. (b) At the second step of the plate insertion, cervical piece of the plate system is fixed onto the cervical vertebra by lateral mass screws. (c) In the third step of the plate system implantation, occipital and cervical pieces of the plate system are connected by rod connector

If necessary, cables or wires are used to secure the stabilization [Figure 2a].

Connection of the occipital and cervical pieces of the plate using rod connector

To achieve OC stabilization in normal anatomical position, the appropriate size rod was inserted between occipital and cervical pieces of the plate system [Figure 2b]. Strong rigid fixation was accomplished by the rod-plate connection. Allograft bone substitutes were used in all cases for better arthrodesis.

Results

There were five male (56%) and four female (44%) patients with OC instability. The patients' age was ranged between 22 and 58 years (mean: 35 ± 11). Three patients had suffered from traumatic dislocation, and three patients had malignancy-associated dislocation, two patients had the congenital basilar impression, and one patient had iatrogenic dislocation. The etiologies that led to the OC instability of patients and their clinical outcomes are summarized in Table 1. Duration of operation ranged between 2 and 7 h (mean: 4.6 ± 1.6).

Patients with a minimum follow-up of 6 months were included in the study. Frankel Grading on admission and at the most recent follow-up examination of the patients are presented in Table 1. Neck pain was observed preoperatively in six cases and improved in all cases within 3 months after surgical procedures. There were no complications, including dural tear or cerebrospinal fluid (CSF) fistula. No patient needed plate revision.

Mortality occurred in one patient due to primary malignancy at the 6 months of follow-up. Morbidity was not observed. Flexion and extension cervical spine X-rays during the follow-up were used to assess fusions. When the occurrence of fusion was in question, computed tomography scans were obtained for visualization of the fusion mass. There was no recurrent subluxation or newly developed instability at adjacent levels during the follow-up period. All patients received dynamic cervical X-rays during their last follow-up that showed no motion across the craniovertebral junction.

Case illustration

A 21-year-old female patient presented with weakness and sensation complaints after 6 months history of a motor vehicle accident. Neurological examination revealed tetraparesis, bilateral positive Hoffmann's and Babinski's sign, loss of the touch sensation below the T4 level, and generalized hyperreflexia. Magnetic resonance imaging (MRI) examination demonstrated C1–C2 dislocation and spinal cord compression [Figure 3]. The patient underwent surgery, and the MIOOC plate system was placed through posterior approach for OC stabilization between the occiput to C3 levels. Allograft bone substitutes were used to increase fusion rate. The postoperative course was uneventful. The patient was discharged 2 days postoperatively with a philadelphia cervical collar. The patient gradually improved in conjunction with a physical rehabilitation program within 1 year. Dynamic cervical X-rays and CT scans 1 year after the surgery demonstrated arthrodesis of the OC junction [Figure 4].

Table 1: The table summarizes patient's characteristics

Case number	Age/sex	Diagnosis and surgical approach	Follow-up (months)	Frankel grade	
				Preoperative	Most recent
1	44 male	Basilar invagination; transoral odontoidectomy and posterior stabilization, halo traction	46	D	D
2	28 female	Traumatic occipito-cervical instability; posterior stabilization	24	D	E
3	24 male	Chiari malformation and syringomyelia; posterior fossa decompression, syringe-subarachnoid shunting, posterior stabilization	16	D	E
4	36 male	Chordoma; transoral-gross total tumor resection, posterior stabilization, halo traction	22	C	D
5	37 female	Traumatic occipito-cervical instability; posterior stabilization	18	E	E
6	58 male	Lung cancer Metastasis to C2; C2 vertebrectomy through anterior and posterior approaches, posterior stabilization, halo traction; mortality due to exacerbation of primary malignancy	6	C	D
7	32 female	Basilar invagination; transoral-odontoidectomy, posterior stabilization, halo traction	24	D	E
8	42 male	Chordoma; transoral-total tumor resection, posterior stabilization, halo traction	20	C	D
9	21 female	Traumatic occipito-cervical instability; posterior stabilization	22	C	D

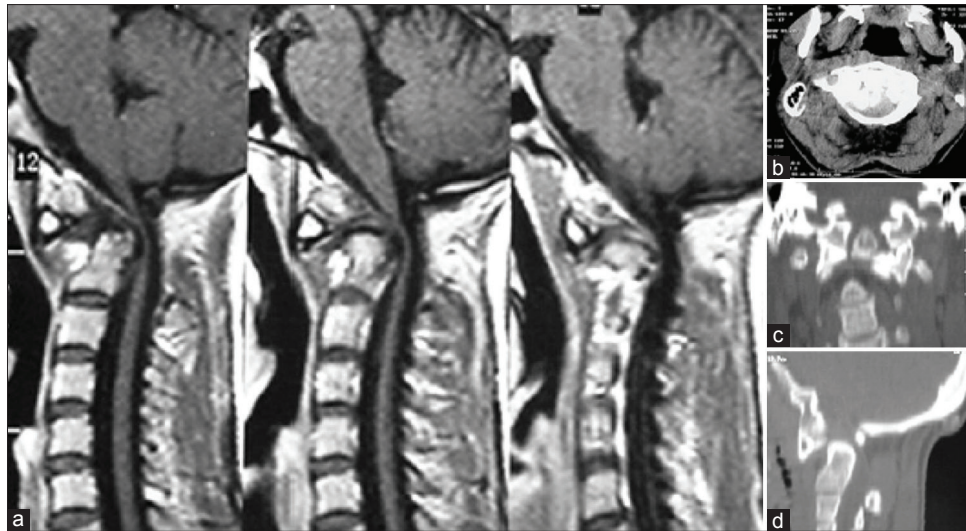


Figure 3: The patient with a C2 type III fracture presented with symptoms of upper spinal cord compression. (a) Sagittal T2 weighted magnetic resonance imaging scans depicted C2 fracture and spinal cord compression at the same level. (b) Axial computed tomography scan depicted bone fragments into the spinal canal with spinal cord compression. (c) Coronal reconstruction of the computed tomography scans depicted C1–C2 dislocation and C2 Type III fracture. (d) Sagittal reconstruction of the computed tomography scans depicted C1–C2 dislocation

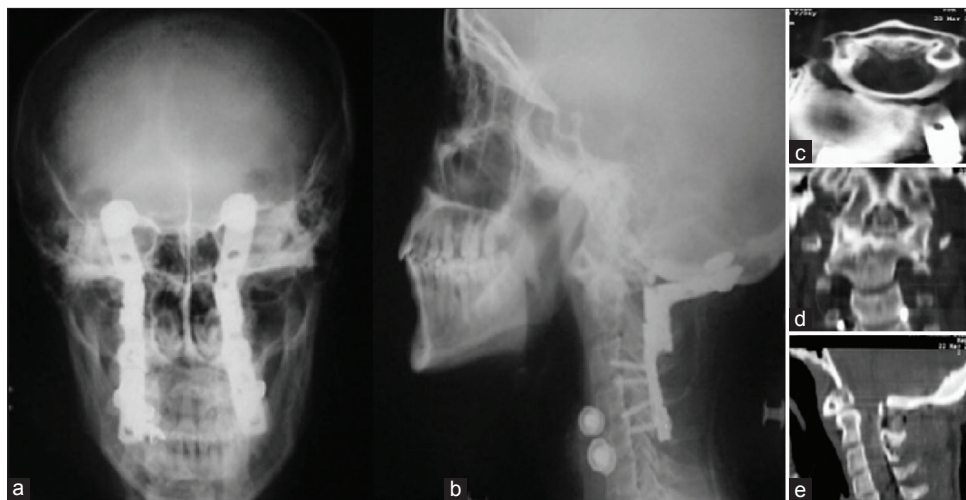


Figure 4: Postoperative radiographs of the patient who underwent surgery for occiput to C3 internal fixation by modified inside-outside occipito-cervical plate system. (a) Anteroposterior X-ray revealed stabilization with plate system (b) Lateral X-ray revealed appropriate anatomical contour of the plate system at the occipito-cervical junction. Occipital IO screws and lateral mass screws on cervical fusion levels are depicted. (c) Poststabilization axial computed tomography scans clearly depicted fixation of the occipito-cervical junction and decompression of the spinal cord. (d) Coronal reconstruction of the computed tomography scans depicted reduction of the dislocation after stabilization. (e) Sagittal reconstruction of the computed tomography scans depicted intact spinal canal with reduction at the level of C1–C2 after stabilization

Discussion

Many clinical studies on OC stabilization with different techniques and devices have reported satisfactory clinical outcomes.^[1-10,12-15,18,19] The use of plate, screw, and rod system has been shown to be superior to traditional semirigid fixation methods.^[20] However, the optimal technique is still debatable in current medical practice. To accomplish optimal OC internal fixation, a strong occipital connection, appropriate plate and rod design, and satisfactory cervical connection of the plate are necessary. Plates and rods should typically be bended to accommodate the craniovertebral angle if the bends

are not sufficient this potentially invites implant fatigue, failure, and screw pull-out.^[21] Rods and plate shaping intraoperatively are a time-consuming procedure; but inappropriately shaped plates may cause additional problems such as inconvenient interfacing of OC bone and plate system which may change the biomechanical forces and plate system stability. To solve these challenges, our novel MIOOC system is very helpful for more anatomical rod-plate reconstruction due to the multi-piece feature. The illustration depicts the importance of plate contour in biomechanical forces distribution on the craniovertebral junction. The acquisition represents pressure force and contact surface relation [Left down-Figure 2a]. The graph

illustrates the negative correlation between pressure force and contact surface area [Right down-Figure 2b]. According to the well-known correlation between surface and pressure forces on plate connection sites, when the contact surfaces of the plate increase, the pressure forces decrease. In fact, the convenient shape of the MIOCC plate system and wide contact surface construction between the plate and OC bony structures may distribute biomechanical forces on OC region which decreases pressure forces on both sides of the plate. Decreased pressure forces on OC bone may increase biomechanical stability [Figure 4a]. Reduced contact surfaces cause an increase in pressure and pull-out forces onto the both sides of the classic single piece plate. In addition, the placement of inconveniently shaped plate system or insufficient surgical positioning may cause cosmetic problems such as sagittal curvature abnormalities [Figure 5]. In this study, the authors suggest that a multi-piece plate system allows for more flexibility in optimizing the interface between plate and OC bones while also allowing for a more effective distribution of forces.

A major problem in surgical screw placement into the occipital bone is the difficulty in visualizing internal occipital anatomy during surgery. In addition, the thickest part of the occipital bone is situated immediately beneath the superior nuchal line which is closely associated with dural venous sinuses around the midline.^[16,17,22] There could be a possibility of postsurgical epidural hematoma or dural tear due to blind insertion of the screws. Unfortunately, the close anatomical relation between dural venous sinuses and thick parts of the occipital bone limits the screw placement on biomechanically superior regions of the occipital bone. Hence, the surgeons need to identify dura mater and venous sinuses to avoid dural and venous sinus penetration during the screw placement on the thicker portions of the occipital bone. A recently reported and relatively new

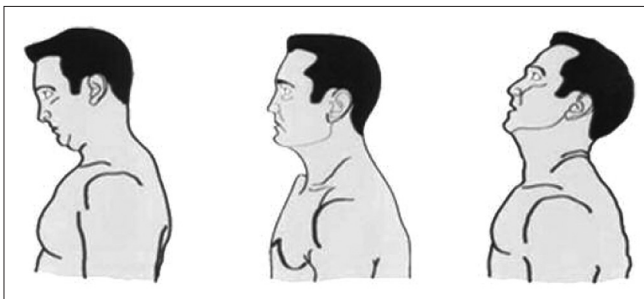


Figure 5: Illustrations reveal possible sagittal curvature abnormalities of the head with inappropriate occipito-cervical stabilization. Inconvenient surgical positioning and inappropriate plate implantation can cause permanent sagittal contour abnormalities. The patient positioning within hyperflexion posture in the surgery or inappropriate shaped plate may cause permanent hyperflexed sagittal curvature abnormality of the head posture (Left). Abnormal positioning of the head within side rotation or using inappropriate plates may cause rotational postural anomalies of the head posture (Middle). Hyperextended head positioning during the surgery or using too much curved plates may cause hyperextension abnormality of the head posture (Right)

technique referred to as “inside-outside technique,” offers several advantages for occipital screw placement.^[13] In our technique, the dissection was performed between the dura and tapered part of occipital bone for screw insertion rather than working in a blind fashion; this technique allows for clearer visualization and more controlled surgical screw placement into the occipital bone without dural and venous injury. Furthermore, the surgeon can identify the thicker portions of the occipital bone during the creation of an entry site, as well as a route for the screw. Placement of the larger screw head on the inner cortical surface of the occipital bone has been reported to provide better biomechanical pull-out forces.^[15] However, there are a few drawbacks to this technique; for example, the creation of an appropriately sized entry site and keyway for screw placement is time-consuming, and extended dural dissection for screw placement may increase epidural hematoma risk. Nonetheless, reported results of cases using the inside-outside technique indicate that it is both safe and useful.^[13,15] In this study, neither epidural hematoma formation nor dural penetration was experienced by inside-outside screw placement technique.

It is well known that incorporating allograft bone substance around the internal fixation increases fusion rate. In current practice, wiring, outside-inside and inside-outside screw techniques are typically used for accomplishing strong occipital anchoring of plate systems.^[1,4-10,12,13] Biomechanical evaluation of the inside-outside screw technique has revealed superior results compared to traditional outside-inside technique.^[15] Hence, the authors preferred to use the inside-outside technique for occipital screw insertion. Lateral mass screws in the cervical region and inside-outside screwing technique on the occipital bone with supplementary bone grafting ensured strong fixation.^[8,10,12,13,15,19,23-25] Occipital bone is thickest around the midline and decortication of this area provide more quality and wider bone fusion bed when compared to midline keel plate-screw constructs. Wider bone fusion bed and convenient shape of the MIOCC plate system provide wide contact surface, prevent micro motion between bone and fixation system which provides more fusion rates. Furthermore, the absence of adverse events such as dural tear and CSF fistula related to midline keel-plate screw instrumentation accelerate bone fusion in MIOCC technique.

Conclusion

The preliminary results of this clinical study show that newly designed MIOCC plate system holds promise as a useful and safe method for providing immediate internal stability to the OC junction. This novel system is also compatible with current classical OC fixation system. Further clinical studies and biomechanical evaluations are needed to establish the long-term reliability of the MIOCC plate system.

Declaration of patient consent

The authors certify that they have obtained all appropriate patient consent forms. In the form the patient(s) has/have given his/her/their consent for his/her/their images and other clinical information to be reported in the journal. The patients understand that their names and initials will not be published and due efforts will be made to conceal their identity, but anonymity cannot be guaranteed.

Financial support and sponsorship

Nil.

Conflicts of interest

There are no conflicts of interest.

References

1. Abumi K, Takada T, Shono Y, Kaneda K, Fujiya M. Posterior occipitocervical reconstruction using cervical pedicle screws and plate-rod systems. *Spine (Phila Pa 1976)* 1999;24:1425-34.
2. Crockard HA, Stevens JM. Craniovertebral junction anomalies in inherited disorders: Part of the syndrome or caused by the disorder? *Eur J Pediatr* 1995;154:504-12.
3. Dickman CA, Papadopoulos SM, Sonntag VK, Spetzler RF, Rekatte HL, Drabier J, *et al.* Traumatic occipitotlantal dislocations. *J Spinal Disord* 1993;6:300-13.
4. Fehlings MG, Errico T, Cooper P, Benjamin V, DiBartolo T. Occipitocervical fusion with a five-millimeter malleable rod and segmental fixation. *Neurosurgery* 1993;32:198-207.
5. Grob D, Dvorak J, Panjabi M, Froehlich M, Hayek J. Posterior occipitocervical fusion. A preliminary report of a new technique. *Spine (Phila Pa 1976)* 1991;16:S17-24.
6. Grob D, Dvorak J, Panjabi MM, Antinnes JA. The role of plate and screw fixation in occipitocervical fusion in rheumatoid arthritis. *Spine (Phila Pa 1976)* 1994;19:2545-51.
7. Jain VK, Mittal P, Banerji D, Behari S, Acharya R, Chhabra DK, *et al.* Posterior occipitoaxial fusion for atlantoaxial dislocation associated with occipitalized atlas. *J Neurosurg* 1996;84:559-64.
8. Sasso RC, Jeanneret B, Fischer K, Magerl F. Occipitocervical fusion with posterior plate and screw instrumentation. A long-term follow-up study. *Spine (Phila Pa 1976)* 1994;19:2364-8.
9. Smith MD, Anderson P, Grady MS. Occipitocervical arthrodesis using contoured plate fixation. An early report on a versatile fixation technique. *Spine (Phila Pa 1976)* 1993;18:1984-90.
10. Vale FL, Oliver M, Cahill DW. Rigid occipitocervical fusion. *J Neurosurg* 1999;91:144-50.
11. Zimmermann M, Wolff R, Raabe A, Stolke D, Seifert V. Palliative occipito-cervical stabilization in patients with malignant tumors of the occipito-cervical junction and the upper cervical spine. *Acta Neurochir (Wien)* 2002;144:783-90.
12. Elia M, Mazzara JT, Fielding JW. Onlay technique for occipitocervical fusion. *Clin Orthop Relat Res* 1992;280:170-4.
13. Pait TG, Al-Mefty O, Boop FA, Arnautovic KI, Rahman S, Ceola W, *et al.* Inside-outside technique for posterior occipitocervical spine instrumentation and stabilization: Preliminary results. *J Neurosurg* 1999;90:1-7.
14. Roberts DA, Doherty BJ, Heggeness MH. Quantitative anatomy of the occiput and the biomechanics of occipital screw fixation. *Spine (Phila Pa 1976)* 1998;23:1100-7.
15. Caglar YS, Torun F, Pait TG, Hogue W, Bozkurt M, Ozgen S, *et al.* Biomechanical comparison of inside-outside screws, cables, and regular screws, using a sawbone model. *Neurosurg Rev* 2005;28:53-8.
16. Naderi S, Usal C, Tural AN, Korman E, Mertol T, Arda MN, *et al.* Morphologic and radiologic anatomy of the occipital bone. *J Spinal Disord* 2001;14:500-3.
17. Zipnick RI, Merola AA, Gorup J, Kunkle K, Shin T, Caruso SA, *et al.* Occipital morphology. An anatomic guide to internal fixation. *Spine (Phila Pa 1976)* 1996;21:1719-24.
18. Hafer TR, Yeung AW, Caruso SA, Merola AA, Shin T, Zipnick RI, *et al.* Occipital screw pullout strength. A biomechanical investigation of occipital morphology. *Spine (Phila Pa 1976)* 1999;24:5-9.
19. Huckell CB, Buchowski JM, Richardson WJ, Williams D, Kostuik JP. Functional outcome of plate fusions for disorders of the occipitocervical junction. *Clin Orthop Relat Res* 1999;359:136-45.
20. Abode-Iyamah KO, Dlouhy BJ, Lopez AJ, Menezes AH, Hitchon PW, Dahdaleh NS, *et al.* Comparison of hinged and contoured rods for occipitocervical arthrodesis in adults: A clinical study. *J Craniovertebr Junction Spine* 2016;7:171-5.
21. Steinmetz MP, Mroz TE, Benzel EC. Craniovertebral junction: Biomechanical considerations. *Neurosurgery* 2010;66:7-12.
22. Ebraheim NA, Lu J, Biyani A, Brown JA, Yeasting RA. An anatomic study of the thickness of the occipital bone. Implications for occipitocervical instrumentation. *Spine (Phila Pa 1976)* 1996;21:1725-9.
23. Barrey C, Mertens P, Jund J, Cotton F, Perrin G. Quantitative anatomic evaluation of cervical lateral mass fixation with a comparison of the Roy-Camille and the Magerl screw techniques. *Spine (Phila Pa 1976)* 2005;30:E140-7.
24. Hott JS, Lynch JJ, Chamberlain RH, Sonntag VK, Crawford NR. Biomechanical comparison of C1-2 posterior fixation techniques. *J Neurosurg Spine* 2005;2:175-81.
25. Zhao XL, Zhao HB, Wang B, Zhu XS, Li LZ, Zhang CQ, *et al.* Lower cervical spine injury treated with lateral mass plates and pedicle screws through posterior approach. *Chin J Traumatol* 2005;8:160-4.