

## Congenital Skull Anomaly with Multiple Brain Stones and Symptomatic Meningioma of Medial Sphenoid Wing

### Abstract

Intracranial calcifications are not uncommon and are mostly seen with intracerebral hematomas, tuberculomas, and brain tumors. These lesions may be intra- or extra-axial and occasionally pose challenge in the diagnosis. We report a case of multiple intracranial extra-axial calcifications with congenital skull anomaly and multiple meningiomas. Authors could not find similar case reported in the literature and present their findings and discuss relevant literature.

**Keywords:** Brain stone, congenital skull anomaly, intracranial calcification

### Introduction

Intracranial solid calcified lesions result most commonly due to intracerebral hematomas, tuberculomas, and brain tumors.<sup>[1]</sup> These lesions have been classified based on their locations such as intra- or extra-axial and based on their etiopathogeneses.<sup>[1]</sup> We report a case of multiple intracranial extra-axial solid calcified lesions in a case of congenital skull anomaly with symptomatic meningiomas. We could not find similar case reported in the literature and present its findings along with relevant literature review.

### Case Report

A 40-year-old female presented with hard swelling over the left side of her forehead and vertex since birth. She had progressively increasing headache for the past 12 years, diminished vision of the left eye, and tingling of the left arm for the past 1½ months. Clinical examination revealed diffuse bony swelling over the left side of the forehead right up to the midline and extending up to coronal suture posteriorly and up to superior temporal line laterally [Figure 1a and b]. Her visual acuity on the left side was 6/36 with normal acuity (6/6) on the right side with optic atrophy on the left side. There were no other motor or sensory deficits. Other systemic examinations, birth and family histories were noncontributory.

This is an open access journal, and articles are distributed under the terms of the Creative Commons Attribution-NonCommercial-ShareAlike 4.0 License, which allows others to remix, tweak, and build upon the work non-commercially, as long as appropriate credit is given and the new creations are licensed under the identical terms.

For reprints contact: reprints@medknow.com

Computed tomography (CT) of the head revealed irregular partially calcified hyperdense extra-axial lesion measuring 26 mm × 18 mm × 18 mm along the left sphenoid wing [Figure 2a-d]. Multiple calcified hyperdense extra-axial dural-based masses were also seen along the left frontoparietal convexity, interhemispheric fissure, and over the superior surface of the left tentorial leaflet. In addition, there was hyperostosis of the overlying left frontal and parietal bones [Figure 2a-d]. Contrast-enhanced magnetic resonance imaging (CEMRI) of the brain revealed a heterogeneously enhancing lesion with moderate perilesional edema of the left medial sphenoid wing and adjacent basi-frontal region, encroaching upon the left optic canal [Figure 3a-e] with another rounded homogeneously enhancing lesion along the superior surface of the left tentorial leaflet, causing buckling of the underlying gray-white matter [Figure 3c and e]. There were no abnormalities of calcium metabolism or any other hormonal function. A provisional diagnosis of the left medial sphenoid wing and left tentorial meningioma in a case of congenital skull anomaly was considered. Diffuse meningiomatosis was considered as differential diagnosis.

She was subjected to skull base approach (left pterional craniotomy with orbito-zygomatic osteotomy) with the aim of removal of soft tissue component of the

**How to cite this article:** Chaturvedi M, Janu V, Kumari R, Chaturvedi S, Jain MK, Jha DK. Congenital skull anomaly with multiple brain stones and symptomatic meningioma of medial sphenoid wing. *Asian J Neurosurg* 2018;13:822-5.

**Monali Chaturvedi,  
Vikas Janu<sup>1</sup>,  
Rima Kumari,  
Sujata Chaturvedi<sup>2</sup>,  
Mukul Kumar Jain<sup>3</sup>,  
Deepak Kumar Jha<sup>1</sup>**

*Departments of Neuroradiology,*

*<sup>1</sup>Neurosurgery and*

*<sup>2</sup>Neuropathology, Institute  
of Human Behavior and*

*Allied Sciences, New Delhi,*

*<sup>3</sup>Department of Pediatric  
Anesthesia, Super Speciality  
Paediatric Hospital and Post  
Graduate Teaching Institute  
Noida, Gautam Budh Nagar,  
UP, India*

### Address for correspondence:

*Dr. Deepak Kumar Jha,  
Department of Neurosurgery,  
All India Institute of  
Medical Sciences, Jodhpur,  
Rajasthan- 342005, India.  
E-mail: jhadeepak2@rediffmail.  
com*

### Access this article online

**Website:** www.asianjns.org

**DOI:** 10.4103/ajns.AJNS\_314\_16

### Quick Response Code:



lesion, decompression of bony lesion around optic foramen, and decompression of the left optic nerve.

Intraoperatively, craniotomy was difficult due to uneven inner surface of the cranium, and a high-speed drill was used to perform the craniotomy. Dura was found adherent to uneven inner surface of the bone along with multiple intradural [Figure 4a-d] calcifications adherent to the underlying surface of dura along with irregular knobby

calcifications projecting from the underlying surface of the pterional osteoplastic bone flap [Figure 4a], making way through the dura, covered with thin flimsy innermost layer of dura with no attachment to the underlying pia mater of the brain. Removal of soft tissue component and decompression of the bony components of the medial sphenoid wing lesion were achieved along with cauterizing its dural attachments (Simpson's Grade II excision). The patient showed significant improvement in her headache and vision postoperatively. She is under regular follow-up, and close monitoring by serial CEMRI brain has been

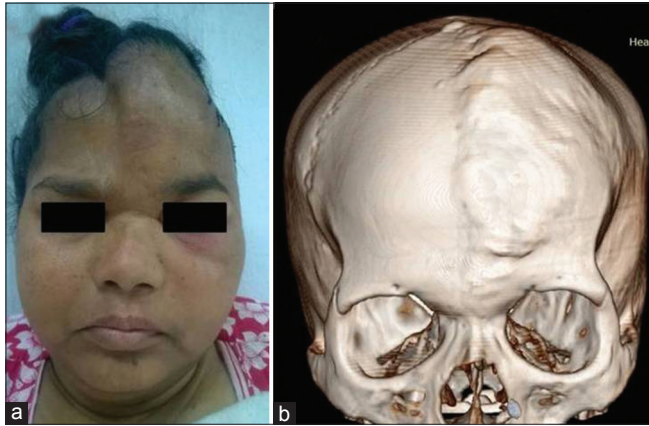

Figure 1: (a) Picture of the patient on third postoperative day showing swelling over the left side of her forehead and vertex with postoperative periorbital swelling. (b) Volume-rendered computed tomography image of the head showing abnormal thickening of the left frontal bone extending from midline to the left of the nasal bridge anteriorly, coronal suture posteriorly, and superior temporal line laterally

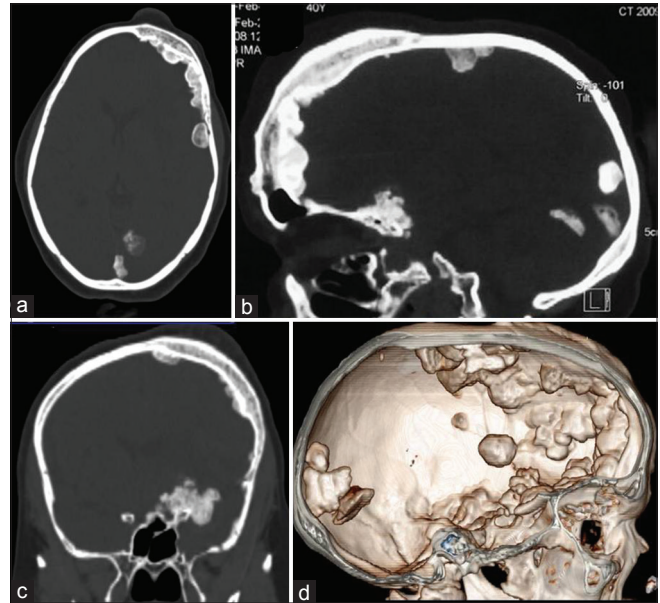


Figure 2: Multiplanar computed tomography images (a-c) with volume-rendered computed tomography images (d) partially calcified extra-axial lesion along the left sphenoid wing and multiple calcified extra-axial dural-based masses along the left frontoparietal convexity, interhemispheric fissure, and over the superior surface of the left tentorial leaflet with hyperostosis of the overlying left frontal and parietal bones

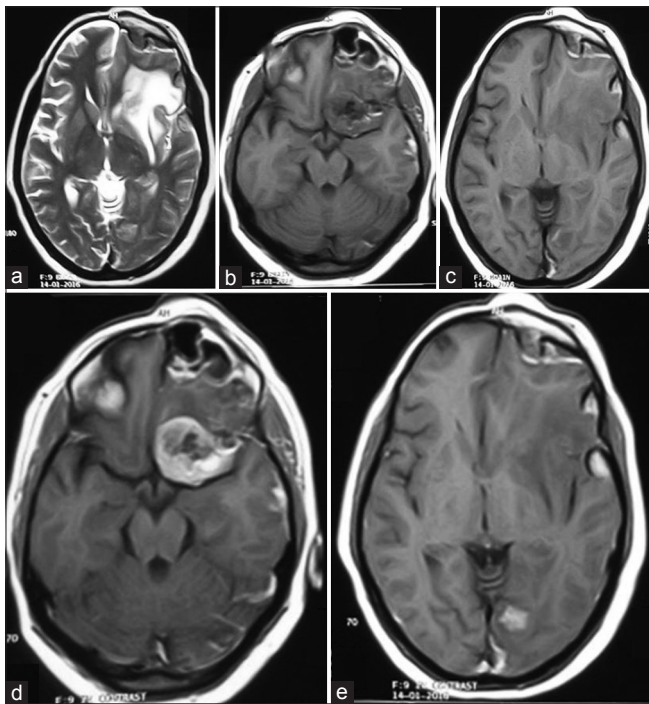


Figure 3: Magnetic resonance images of brain: T2 axial (a) T1 axial (b and c) with contrast (d and e) images revealing a heterogeneously enhancing lesion with moderate perilesional edema of the left medial sphenoid wing and adjacent basi-frontal region with another rounded homogeneously enhancing lesion (c and e) along the superior surface of the left tentorial leaflet

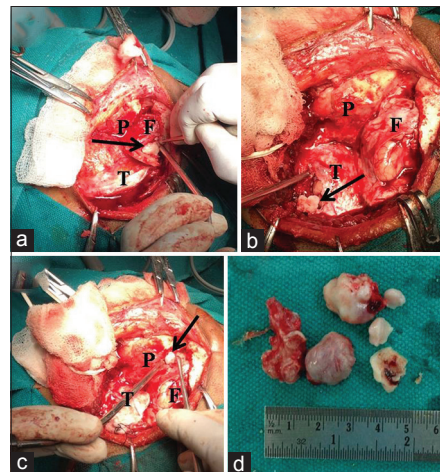


Figure 4: Intraoperative images showing discrete calcifications (arrow) at inner dural surfaces of frontal (a) and temporal lobes (b) and inner cortex of pterional osteoplastic bone flap (c). Multiple calcified pieces removed during surgery (d). P – Drilled sphenoid ridge; F – Frontal lobe; T – Temporal lobe



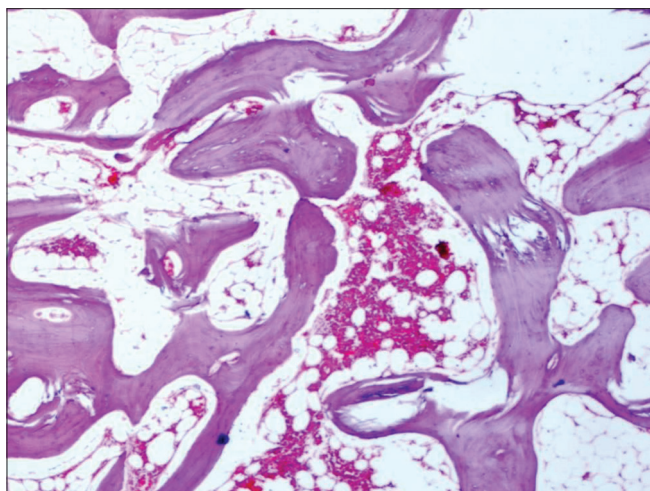
planned so that further surgery or radiosurgery may be considered if recurrence in the operated lesion or growth in the residual lesion is seen.

Histopathological examination of the soft tissue lesion was consistent with transitional meningioma (WHO Grade I), and bony lesion revealed lamellar bone architecture with marrow elements without tumor cells [Figure 5].

## Discussion

The presence of brain stones or cerebral calculi is not an uncommon occurrence on routine imaging. They were defined by Tiberin and Beller as large, solitary/multiple, well-defined, circumscribed bony hard areas of pathological intracerebral calcification.<sup>[2]</sup> They can be classified as intra- or extra-axial based on their location. These lesions have also been classified based on their etiopathogenesis into neoplastic, vascular, infectious, congenital, and endocrine/metabolic categories.<sup>[1]</sup>

Our case had extra-axial calcified lesions, causes of which include dural osteomas, craniopharyngiomas, calcifying pseudoneoplasms of the neuraxis (CAPNON), exaggerated physiological calcifications, dural calcifications and ossifications, lipomas and congenital calcifications, fibrous dysplasia, and hyperostosis frontalis interna. Dural osteomas do not possess a laminated bony architecture, but present as a solid mass of calcification.<sup>[1-3]</sup> Craniopharyngiomas are located in the suprasellar region and present with hemorrhage and calcification mainly in an amorphous or lobulated pattern with distinct histopathological features. CAPNON are composed of a pathognomonic chondromyxoid matrix in an amorphous or nodular pattern as well as palisading spindle or epithelioid cells and varying proportions of fibrous stroma, which encase cranial nerves.<sup>[3]</sup> Dural calcifications and ossifications, especially of the falx cerebri, can also appear as “brain stones.” They generally do not have any clinical



**Figure 5:** Photomicrograph showing normal trabeculae of bone with hematopoietic marrow elements (H and E, x200)

significance and are often incidental findings during CT scans of the brain.<sup>[4]</sup> Dural calcifications are a result of calcium salt deposition, whereas dural ossifications actually involve new bone formation.<sup>[4]</sup> Despite similarities in CT appearance of dural osteomas, our case had normal bony architecture in pathological examination, which is found in dural ossifications. The causes of congenital calcifications include Sturge–Weber syndrome (SWS), tuberous sclerosis as well as lipomas, and neurofibromatosis type 2 (NF-2).<sup>[1]</sup> There was no associated cutaneous manifestations seen in tuberous sclerosis and SWS or family history of similar lesions in the family of our patient, which is seen in NF-2 lesions. Swelling in fibrous dysplasia is not present since birth, whereas hyperostosis frontalis interna does not present as a swelling over the cranium and both have characteristic pathological features which were absent in our case.<sup>[5,6]</sup>

The reported case had never undergone any radiological investigation for her hard swelling over her face and head before she reported to our outpatient clinic. The cause of her bony swelling since birth is not known and it cannot be claimed that intracranial calcifications seen on the imaging studies were present since birth. Intrauterine infection due to TORCH agents causes intra-axial calcifications present at birth along with neurological consequences which are present at birth and in neonatal period, which were not present in our case.<sup>[1,7]</sup> Various types of craniosynostosis do result in abnormal shape of the head since birth or early childhood and may cause various symptoms including raised intracranial pressure.<sup>[1,8]</sup> There are reports of intracranial calcifications in celiac disease, Fahr disease, and dysfunctions of thyroid and parathyroid hormones, which were not observed in our case.<sup>[7]</sup>

Meningiomas are the most common intracranial tumors, and macroscopic calcifications are seen in 60% of meningiomas.<sup>[7]</sup> The term “multiple meningiomas” is coined by Cushing and is defined as at least two spatially separated meningiomas occurring simultaneously or more than two meningiomas arising sequentially from two clearly distinct regions.<sup>[8]</sup> Diffuse meningiomatosis is considered to be an extreme form of multiple meningioma.<sup>[8,9]</sup> CEMRI brain revealed two enhancing lesions in our patient and both were located on the abnormal calcifications of the left medial sphenoid wing and superior surface of the left leaf of the tentorium. Multiple meningiomas are prevalent in females as in our case.<sup>[9]</sup> The prevalence of meningiomatosis unrelated to NF-2 is, however, very seldom.<sup>[10]</sup>

Based on size and locations of these tumors, total resection might not be possible though it is the ideal approach, and in such cases, only the symptomatic mass may be removed, which was done in our case. The patient is under regular follow-up and may need additional surgery or radiosurgery for any further growth of the lesion.

### Acknowledgment

The authors acknowledge radiological data acquisition by Mr. Narendra K Sharma, Technician, Department of Neuroradiology, Institute of Human Behavior and Allied Sciences, New Delhi, India.

### Declaration of patient consent

The authors certify that they have obtained all appropriate patient consent forms. In the form the patient(s) has/have given his/her/their consent for his/her/their images and other clinical information to be reported in the journal. The patients understand that their names and initials will not be published and due efforts will be made to conceal their identity, but anonymity cannot be guaranteed.

### Financial support and sponsorship

Nil.

### Conflicts of interest

There are no conflicts of interest.

### References

1. Celzo FG, Venstermans C, De Belder F, Van Goethem J, van den Hauwe L, van der Zijden T, *et al.* Brain stones revisited – Between a rock and a hard place. *Insights Imaging* 2013;4:625-35.
2. Tiberin P, Beller AJ. Observations on so-called brain stones or cerebral calculi. *Neurology* 1963;13:464-76.
3. Aiken AH, Akgun H, Tihan T, Barbaro N, Glastonbury C. Calcifying pseudoneoplasms of the neuraxis: CT, MR imaging, and histologic features. *AJNR Am J Neuroradiol* 2009;30:1256-60.
4. Halstead AE, Christopher F. Calcification and ossification of the meninges. *Arch Surg* 1923;6:847-57.
5. Hakim DN, Pelly T, Kulendran M, Caris JA. Benign tumours of the bone: A review. *J Bone Oncol* 2015;4:37-41.
6. Devriendt W, Piercecchi-Marti MD, Adalian P, Sanvoisin A, Dutour O, Leonetti G. Hyperostosis frontalis interna: Forensic issues. *J Forensic Sci* 2005;50:143-6.
7. Kiroglu Y, Calli C, Karabulut N, Oncel C. Intracranial calcifications on CT. *Diagn Interv Radiol* 2010;16:263-9.
8. Cushing H. *Meningiomas: Their Classification, Regional Behaviour, Life History, and Surgical end Results.* Springfield, Illinois: Charles C Thomas; 1938. p. 785.
9. Sheehy JP, Crockard HA. Multiple meningiomas: A long-term review. *J Neurosurg* 1983;59:1-5.
10. Zhu JJ, Maruyama T, Jacoby LB, Herman JG, Gusella JF, Black PM, *et al.* Clonal analysis of a case of multiple meningiomas using multiple molecular genetic approaches: Pathology case report. *Neurosurgery* 1999;45:409-16.