

## Acute Spontaneous Cervical Spinal Epidural Haematoma a Very Rare Presentation Mimicking of Carotid Dissection during Sleep

### Abstract

Acute spontaneous spinal epidural hematoma without any identified etiology is a rare phenomenon and an uncommon cause of acute spinal cord compression. We report a case of acute spontaneous cervical spinal epidural hematoma, with sudden onset of acute neck pain and left-side body weakness during sleep which resembling of cervicle carotid dissection. The pain commenced suddenly, early in the morning while the patient was asleep. He had no previous history of any relevant medical disorder. Cervical Spine MRI revealed a cervical epidural haematoma at C3/C4, mainly on the left side, with spinal cord compression. Therefore, an emergent C3/C6 hemilaminectomy and evacuation of hematoma were carried out within 24 h of presentation. The patient's neck pain resolved after surgery and he was able to walk, though he required bladder catheterization on discharge after 1 week. He has nearly intact motor neurological examination in the second month of the operation.

**Keywords:** *Acute, cervical, carotid, dissection, epidural hematoma, magnetic resonance imaging, sleep, spinal, spontaneous, stroke*

### Introduction

Acute spontaneous cervical spinal epidural hematoma (ASSEDH) is a well-recognized but rare condition. Spontaneous spinal epidural hematoma has been reported to be associated with vascular malformations, tumors, infections, pregnancy, rheumatoid arthritis, atherosclerosis, and hypertension. The term “spontaneous” has been defined here as “no identified etiology.” First described by Jackson in 1869,<sup>[1]</sup> 119 cases have thus far been reported, using “spontaneous spinal epidural hematoma during sleep” as keywords. Out of 119, we found only one English and two Japanese pieces of literature, indexed in Medline, that reported with a similar presentation but different etiologies.<sup>[2-15]</sup>

### Case Presentation

A 42-year-old army officer with no previous medical illness presented to the emergency department with acute onset of neck pain that woke him up from sleep, progressing to left-sided body weakness. He was not on any anticoagulants or traditional medication. He denied any spinal trauma or prior cervical spondylosis. On admission,

he was fully conscious (Glasgow coma scale 15/15), with stable hemodynamic. He had no contusion or swelling of the head, neck, or back but was tender to palpation from the level C3–C6. The pupils were equal and reactive bilaterally. He had normal cranial nerve function. The motor examination showed muscle strength of (5/5) on the right upper and lower extremities, whereas the left side had hemiparesis (3/5). The sensory examination showed pinprick and light touch sensation reduced on upper limb C5/C6/C7-T2/T3 level on the right side. The left side had normal sensation. Deep tendon reflexes were absent at the biceps C5/C6 bilaterally, whereas patella and ankle reflexes were normal bilaterally. Simultaneously, he developed urinary retention (1500 cc) on urinary bag past-urethral catheterization. The anal sphincter tone was normal. The cerebellar examination seemed normal given the strength limitation. After obtaining a negative doppler ultrasonography and cranial CT scan result, an emergent magnetic resonance imaging (MRI) study revealed a cervical hematoma extending from C3/C4 [Figures 1 and 2], mainly on the

**Mohammad Jaweed,  
D. Ganesan<sup>1</sup>,  
Mohammad Ajmal  
Yasin<sup>2</sup>,  
Boon Seng Liew<sup>3</sup>,  
Azmin Kass Bin  
Rosman<sup>3</sup>**

*Department of Neurosurgery, School of Medicine, Faculty of Health and Medical Sciences, Hospital Sungai Buloh, Taylor's University, Selangor; <sup>1</sup>Department of Surgery, University of Malaya Medical Centre, Kuala Lumpur; <sup>3</sup>Department of Neurosurgery, Hospital Sungai Buloh, Selangor, Malaysia, <sup>2</sup>Jamaica Hospital Medical Centre, New York, USA*

**Address for correspondence:**  
*Dr. Mohammad Jaweed,  
Department of Neurosurgery,  
School of Medicine, Faculty of  
Health and Medical Sciences,  
Hospital Sungai Buloh, Taylor's  
University, Selangor, Malaysia.  
E-mail: surgeon.j@gmail.com*

#### Access this article online

**Website:** [www.asianjns.org](http://www.asianjns.org)

**DOI:** 10.4103/ajns.AJNS\_318\_19

#### Quick Response Code:



This is an open access journal, and articles are distributed under the terms of the Creative Commons Attribution-NonCommercial-ShareAlike 4.0 License, which allows others to remix, tweak, and build upon the work non-commercially, as long as appropriate credit is given and the new creations are licensed under the identical terms.

For reprints contact: [reprints@medknow.com](mailto:reprints@medknow.com)

**How to cite this article:** Jaweed M, Ganesan D, Yasin MA, Liew BS, Bin Rosman AK. Acute spontaneous cervical spinal epidural haematoma a very rare presentation mimicking of carotid dissection during sleep. *Asian J Neurosurg* 2020;15:455-7.

**Submitted:** 27-Oct-2019

**Revised:** 13-Dec-2019

**Accepted:** 20-Feb-2020

**Published:** 29-May-2020

left side. The patient underwent C3/C6 hemilaminectomy [Figure 3], and evacuation of hematoma was carried out within 24 h of presentation. Pathological examination of the ablated fragments revealed fibrinous and hemorrhagic material, but there was no histological evidence of tissue. There was a significant improvement in the weakness on the left side when the patient was discharged from the hospital at the 12<sup>th</sup> day of the operation. He had complete functional recovery at the 2 weeks of follow-up.

## Discussion

Spontaneous cervical epidural hematoma was first described in 1869 by Jackson<sup>[1]</sup> and the first surgical approach was performed in 1946 by ver Brugghen.<sup>[3]</sup> Vascular malformation,<sup>[4,15]</sup> anticoagulant therapy,<sup>[5,15]</sup> and neoplasm or systemic disease<sup>[16,2-8]</sup> are well-known causes. However, the cause of the bleeding remains unknown in 40% of the cases and these are called an idiopathic spontaneous cervical epidural hematoma.<sup>[5,15]</sup> It is still debatable whether the etiology of spontaneous epidural hematoma is arterial or venous. Those who support the theory of venous origin claim that epidural veins have thin walls and no valves. As a result of a sudden increase of intrathoracic and intra-abdominal pressure after Valsalva maneuvers such as coughing, sneezing, straining, swimming, defecation, micturition, vomiting and coitus, and lacerations may occur in the venous plexus causing epidural hemorrhage. However, as seen in our case, ASSEDH occurred during sleep without any predisposing factor as mentioned earlier, our patient was at complete rest. Nevertheless, there is some relationship that exists between sleep and hemodynamic instabilities that can cause end-organ damage such as morning stroke, acute myocardial infarct, and sudden cardiac death.<sup>[7]</sup> Beatty and Winston analyzed the arterial circulation of the cervical region and considered the hypothesis that the arterial structures located posteriorly and posterolaterally in the epidural space were responsible for the hemorrhage.<sup>[6]</sup> ASSEDH generally presents with a sudden onset of acute neck pain. Pain radiation alters according to the localization of the hematoma on the spinal cord and the nerve roots. The second most common symptom is the weakness of the limbs, seen below the compressed spinal cord. Paresis can increase within minutes or days or rarely reoccur. Spontaneous cervical epidural hematomas need emergent surgical decompression, especially in cases with neurological deterioration although some cases with spontaneous remission without any surgical treatment have been reported.<sup>[17-19,16,9]</sup> Total laminectomy is the best choice as a surgical approach, but hemilaminectomy can be preferred according to the location of the hematoma.<sup>[17,18,14]</sup> In our case, the patient with left-sided hemiparesis presented to the emergency room 6 h after the event. It was initially evaluated as a cerebrovascular accident. After obtaining a negative result of cranial computed tomography scan, detailed neurological

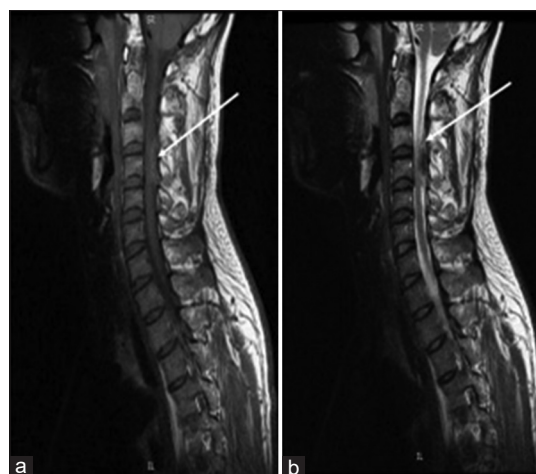


Figure 1: (a) The T1-weighted images showed an isointense, dorsolaterally situated epidural collection on the left side extending from C4 to C6. (b) The T2-weighted images displayed a heterogeneous signal within the lesion

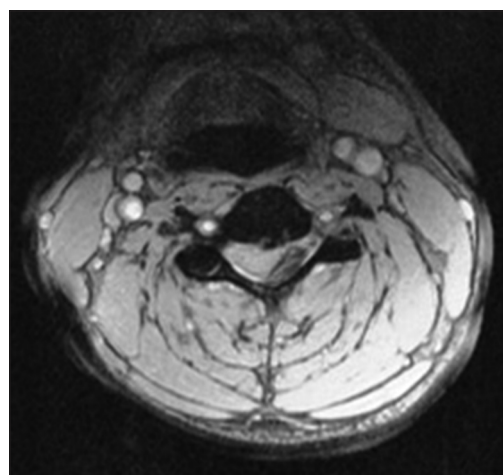


Figure 2: Axial T2-weighted scan of the cervical spine revealed a left dorsolateral hypointense epidural collection with compression of the spinal cord suggestive of acute epidural hematoma

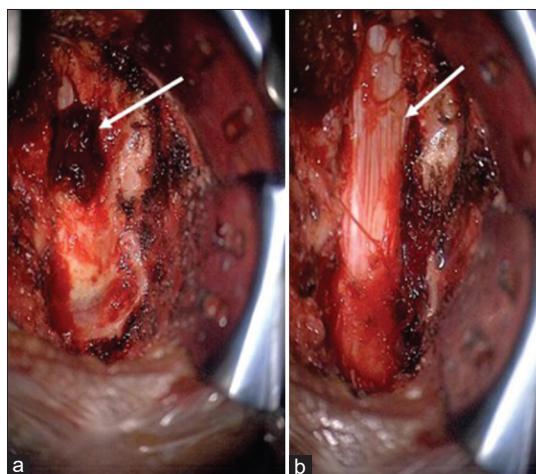


Figure 3: (a) C4/C6 hemilaminectomy performed, left paramedian localized hematoma. (b) Post evacuation of hematoma, there is no other abnormality seen under a microscope

examination was carried out. Cervical pathology was considered and it was supported by MRI. The patient was operated within 10 h of his presentation and he has nearly intact motor neurological examination in the 2<sup>nd</sup> month of the operation.

## Conclusion

Acute spontaneous cervical spinal epidural hematoma is a clinical condition with a wide variety of initial presentations and is thus easily misdiagnosed. ASCEDH has a fatal progressive behavior in cases when the diagnosis is delayed. Clinicians should keep in mind that the clinical presentation of the cervical epidural hematomas can be acute hemiparesis and it can be misdiagnosed as an ischemic stroke, for which intravenous thrombolysis is contraindicated in the emergency room. Patients must therefore be evaluated from this perspective. Surgical decompression must be preferred in patients presenting with neurological deterioration. However, the author presents a unique case of ASCEDH that occurred while the patient was asleep with the absence of significant precipitating factors mentioned in the literature.

## Declaration of patient consent

The authors confirmed that all appropriate patient consent forms have obtained. In the form, the patient has given consent for his images and other clinical information to be reported in the journal. The patient understands that his names and initials will not be published and due efforts will be made to conceal their identity.

## Financial support and sponsorship

Nil.

## Conflicts of interest

There are no conflicts of interest.

## References

1. Jackson R. Case of spinal apoplexy. *Lancet* 1869;2:538-539.
2. Miyagi Y, Miyazono M, Kamikaseda K. Spinal epidural vascular malformation presenting in association with spontaneously resolved acute epidural hematoma. *J Neurosurg* 1998;88:909-11.
3. Ver Bruggen A. Extradural spinal hemorrhage. *Ann Surg* 1946;123:154-9.
4. Awada A, Russell N, Fayez NA, Naufal R, Kohlani HA. Spontaneous cervical epidural hematoma. *Spinal Cord* 1998;36:71-2.
5. Foo D, Rossier AB. Preoperative neurological status in predicting surgical outcome of spinal epidural hematomas. *Surg Neurol* 1981;15:389-401.
6. Beatty RM, Winston KR. Spontaneous cervical epidural hematoma. A consideration of etiology. *J Neurosurg* 1984;61:143-8.
7. Smolensky MH, Hermida RC, Castriotta RJ, Portaluppi F. Role of sleep-wake cycle on blood pressure circadian rhythms and hypertension. *Sleep Med* 2007;8:668-80.
8. Ravid S, Schneider S, Maytal J. Spontaneous spinal epidural hematoma: An uncommon presentation of a rare disease. *Childs Nerv Syst* 2002;18:345-7.
9. Brawn LA, Bergval UE, Davies-Jones GA. Spontaneous spinal epidural haematoma with spontaneous resolution. *Postgrad Med J* 1986;62:885-7.
10. Lee SS, Lui TT, Lee ST. Spontaneous cervical spinal epidural hematoma: A case report. *Acta Neurol Taiwan* 2003;12:34-37.
11. Lannum S, Stratton J. Spontaneous epidural hematoma of the thoracic spine in a 17-year-old adolescent boy: A case report. *Am J Emerg Med* 2009;27:628.e5-6.
12. Mishima K, Aritake K, Morita A, Miyagawa N, Segawa H, Sano K. A case of acute spinal epidural hematoma in a patient with antiplatelet therapy. *No Shinkei Geka* 1989;17:849-53.
13. Murata T, Ohhata K, Tsujikawa S, Sumimoto T, Kitano S, Shirahata N, *et al.* A case of spontaneous spinal epidural hematoma presenting Brown-Séquard syndrome. *No Shinkei Geka* 1984;12:1195-200.
14. Ito H, Takai K, Taniguchi M. Spontaneous cervical epidural hematomas with acute hemiparesis should be considered a contraindication for intravenous thrombolysis: A case report with a literature review of 50 cases. *Intern Med* 2014;53:57-62.
15. Shima H, Yasuda M, Nomura M, Mori K, Miyashita K, Tamase A, *et al.* A spinal epidural hematoma with symptoms mimicking cerebral stroke. *Nagoya J Med Sci* 2012;74:207-10.
16. Harris DJ, Fornasier VL, Livingston KE. Hemangiopericytoma of the spinal canal. Report of three cases. *J Neurosurg* 1978;49:914-20.
17. Hentschel SJ, Woolfenden AR, Fairholm DJ. Resolution of spontaneous spinal epidural hematoma without surgery: Report of two cases. *Spine (Phila Pa 1976)* 2001;26:E525-7.
18. Groen RJ. Non-operative treatment of spontaneous spinal epidural hematomas: A review of the literature and a comparison with operative cases. *Acta Neurochir (Wien)* 2004;146:103-10.
19. Adamson DC, Bulsara K, Bronec PR. Spontaneous cervical epidural hematoma: Case report and literature review. *Surg Neurol* 2004;62:156-9.