

Evisceration of Brain: An Unusual Case Report of Bear Mauling from Eastern India

Abstract

Even if human beings are the most intelligent among all living beings, they are still not immune to attack from wild animals. Human contact with bears has become more frequent as their habitat is being endangered by frequent deforestation. The sloth bear is one of the few bear species found in India, especially in the hilly areas of Southern Odisha. Bears are highly intelligent and omnivorous animals with long claws coupled with powerful shoulder. Here, we describe the tale of a poor tribal male's encounter with a sloth bear resulting in critical injuries to face, scalp, skull bone, with brain matter fungating-out of the skull. We immediately went for debridement of the, bulged-out contused brain matter and opted for delayed repair of scalp defect with antero-lateral thigh free-flap to save him from fatality along with an acceptable cosmetic repair of the defect.

Keywords: Bear mauling, eviscerating brain, polymicrobial infection

Introduction

Bear attacks are rare, and still rare are the brain injuries due to bear mauling. Most of the bear attacks are accidental in nature. A search in scientific literature reveals only a few articles dealing with case reports of traumatic brain injury due to bear mauling.^[1]

Here, we discuss the presentation and subsequent management of a tribal male from Southern Odisha, presented to us, after being assaulted by a sloth bear, leading to avulsion of his left frontal and parietal scalp with the loss of left frontal skull bone and protrusion of contused brain matter out of the skull defect.

Case Report

A 40-year-old tribal male reported to our emergency department 3 days after being assaulted by a bear attack. He belonged to the tribal area of interior Koraput district of Odisha which is around 700 km away from our hospital. Interestingly, he suffered from this injury in course of saving his little child from bear attack. Eventually, he was successful in saving the life of his kid but ended up in a devastating head injury with eviscerating brain mater [Figure 1a].

On examination, he was conscious, drowsy, with Glasgow Coma Scale (GCS)

- E4V4M5, pupil-B/L - normal size equally reacting to light, with features of hypovolemic shock. BP-100/60 mmHg, pulse-130/min with severe pallor. No other signs of systemic injuries were present. Chest was clear bilaterally.

Immediately, patient was resuscitated with normal saline and ringer lactate. Two units of whole blood were arranged and transfused. Broad spectrum antibiotics, in the form of piperacillin – tazobactam along with metronidazole and amikacin were started. Anti-rabies and anti-tetanus vaccines were given. With little improvement in general condition, the patient was shifted to minor OT for wound inspection [Figure 1a]. On local examination, there was an avulsed scalp injury in left fronto-parietal region with skin loss of size 15 cm × 13 cm and eviscerated mud like contused brain mater seen protruding from the skull defect with foul smelling discharge [Figure 1d]. With this picture in mind, we wanted to know the extent of brain injury, and sent the patient to our radiology department for noncontrast computed tomography (NCCT) brain to plan our future management.

NCCT brain revealed the loss of skull bone in left fronto-parietal region above the supra-orbital ridge with eviscerating brain mass, having no intradural or intra-parenchymal pathology [Figure 1b and c].

This is an open access article distributed under the terms of the Creative Commons Attribution-NonCommercial-ShareAlike 3.0 License, which allows others to remix, tweak, and build upon the work non-commercially, as long as the author is credited and the new creations are licensed under the identical terms.

For reprints contact: reprints@medknow.com

How to cite this article: Behera BR, Mishra S, Das D, Gantayat R. Evisceration of brain: An unusual case report of bear mauling from eastern India. Asian J Neurosurg 2017;12:724-6.

**Bikash Ranjan Behera,
Sanjib Mishra,
Deepak Das,
Rajesh Gantayat¹**

Departments of Neurosurgery and ¹Plastic Surgery, SCB Medical College, Cuttack, Odisha, India

Address for correspondence:

*Dr. Bikash Ranjan Behera,
B/L 29, VSS Nagar, Post
Office Sahid Nagar,
Bhubaneswar - 751 007,
Odisha, India.
E-mail: drtinku007@gmail.com*

Access this article online

Website: www.asianjns.org

DOI: 10.4103/ajns.AJNS_31_15

Quick Response Code:



With this information we shifted the patient to emergency OT and explored the lacerated scalp wound. Excision and debridement of dead devitalized tissue was done. Through irrigation with hydrogen peroxide, povidone-iodine solution, and normal saline was done. Skull margin was delineated. Mud like brain mass seen protruding through dural defect. Contused and dead brain tissue was excised till normal brain mass seen. Dural margin was delineated. Dural loss of size (4 cm × 3 cm) was repaired with pericranium [Figure 1e]. Scalp wound was kept for secondary free flap repair in next stage after 7 days [Figure 1f]. With this primary surgery, patient's general condition improved, fever subsided. Culture report of debrided tissue suggested mixed aerobic, anaerobic and Gram-negative organisms sensitive to piperacillin and tazobactam.

In second stage operation after 1 week, the scalp defect was repaired by our plastic surgery team with antero-lateral thigh free flap [Figure 2a-d]. Patient was improved but due to aspiration pneumonia he was sent to neurosurgery Intensive Care Unit. With further improvement [Figure 2e], he was discharged on day 20 of admission with a GCS score of - E4V4M6 along with paresis of right upper extremity and cognitive dysfunction. He is yet to come for first follow-up.

Discussion

Injuries due to encounter with wild animals are mostly a combination of cutting, penetrating, and crushing type.^[2,3-5] Recent decrease in forest area has increased the chances of bear-human interaction, and hence resulting in fatal encounters.^[4,5] These injuries involve substantial struggle on the part of the victim over the ground resulting in injuries contaminated with all debris, mud, and grass.^[4,5] So, vigorous irrigation and debridement of all foreign bodies is of paramount importance.^[2,6]

Case of bear mauling with eviscerating brain mass is very rare in world literature.^[1] Injury to brain presents with still challenging medical and surgical expertise with proper assessment, meticulous documentation, through wound cleaning and debridement for saving the life of the victim. Head injuries with scalp and skull defect needs greater attention, as dural tear along with parenchymal injuries are not uncommon. NCCT of brain with three-dimensional reconstruction of skull bone is very useful for surgical planning. The importance of swab culture from wound site should never be underestimated as meningitis and brain abscess are the two most common causes of mortality in brain injuries during animal encounters.^[7] As the bacteriology is polymicrobial, with mixed aerobic and anaerobic species along with Gram-positive and Gram-negative flora, broad spectrum antibiotics are worth giving empirically.^[7] Our culture reports revealed mixed flora with predominantly *Escherichia coli*, staph. Epidermidis and pseudomonas similar to previous literature.^[7] We started with piperacillin-tazobactam, metronidazole and amikacin, which responded nicely. Tetanus and anti-rabies prophylaxis should be considered for animal all bite wounds.^[8]

Although surgical management in animal bite injuries remains controversial, wound debridement still enjoys paramount importance.^[6] Now surgical opinion is swinging in the favor of early repair.^[9] The definitive treatment depends on the type of wound, depth of the wound, location of the wound and tissue loss, if any. In our case, we went for early debridement of protruding brain mass with pericranial augmentation duraplasty in same setting, and deferred the free flap repair of scalp wound to a later date, which resulted in dramatic recovery.

The psychological aspect of bear mauling, which usually results in posttraumatic stress disorder, needs to be

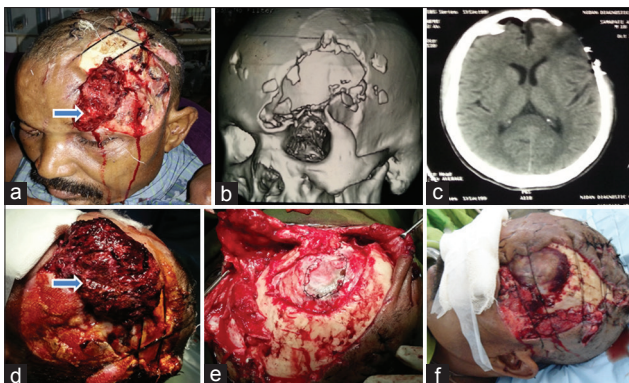


Figure 1: (a) Patient in emergency department showing scalp injury with fungating brain mass, (b) three-dimensional reconstructed skull view showing loss of left fronto parietal bone extending upto supra orbital ridge, (c) computed tomography scan showing bone defect with underlying edema but no mass effect or hematoma, (d) brain parenchyma protruding through skull defect, (e) repair of dural defect with pericranium, (f) patient after dural repair ready for free flap scalp defect repair

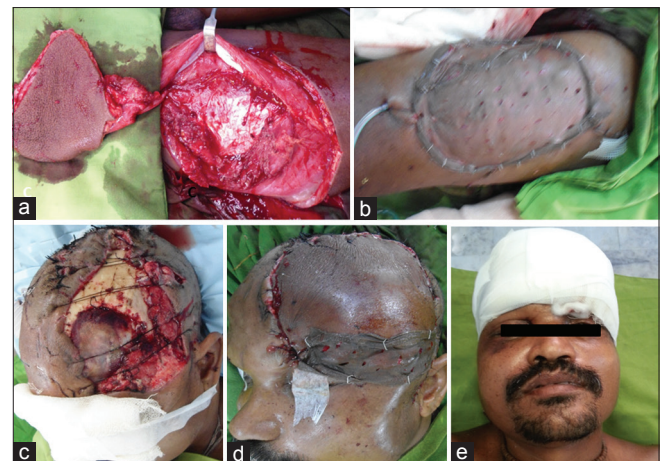

Figure 2: (a) Antero-lateral thigh free flap being harvested, (b) harvested site closure with skin graft, (c) wound after debridement and duraplasty, (d) wound after free flap repair of scalp, (e) patient on day of discharge

addressed with adequate anti-anxiety medications and psychotherapy.^[10]

Conclusion

As traumatic brain injury due to bear mauling is very rarely reported, its documentation with rational medical and surgical management is justified. Awareness, education, knowledge, and prevention rather than the elimination of animal populations, may be the best way to control wild animal attacks on human in future.

Declaration of patient consent

The authors certify that they have obtained all appropriate patient consent forms. In the form the patient(s) has/have given his/her/their consent for his/her/their images and other clinical information to be reported in the journal. The patients understand that their names and initials will not be published and due efforts will be made to conceal their identity, but anonymity cannot be guaranteed.

Financial support and sponsorship

Nil.

Conflicts of interest

There are no conflicts of interest.

References

1. Hayashi Y, Fujisawa H, Tohma Y, Yamashita J, Inaba H. Penetrating head injury caused by bear claws: Case report. *J Trauma* 2003;55:1178-80.
2. Frank RC, Mahabir RC, Magi E, Lindsay RL, de Haas W. Bear maulings treated in Calgary, Alberta: Their management and sequelae. *Can J Plast Surg* 2006;14:158-62.
3. Middaugh JP. Human injury from bear attacks in Alaska, 1900-1985. *Alaska Med* 1987;29:121-6.
4. Herrero S. *Bear Attacks: Their Causes and Avoidance*. New Revised Edition. Toronto: McClelland and Stewart Ltd.; 2003.
5. Dvivedi S, Sood S, Mehrotra V, Dvivedi J. Injuries caused by the black Himalayan bear in the foothills of Garhwal, Himalayas. *Trop Doct* 2003;33:115-7.
6. Mahabir RC, Olesen PR, Cannon WG, Barre NM, Snelling CF, Williamson JS, *et al.* Surgical management of injuries sustained from grizzly bear maulings treated in Vancouver, British Columbia. *Can J Plast Surg* 2000;8:193-8.
7. Kunimoto D, Rennie R, Citron DM, Goldstein EJ. Bacteriology of a bear bite wound to a human: Case report. *J Clin Microbiol* 2004;42:3374-6.
8. Taylor M, Elkin B, Maier N, Bradley M. Observation of a polar bear with rabies. *J Wildl Dis* 1991;27:337-9.
9. Maimaris C, Quinton DN. Dog-bite lacerations: A controlled trial of primary wound closure. *Arch Emerg Med* 1988;5:156-61.
10. Kaplan HI, Saddock BJ, Grebb JA. *Synopsis of Psychiatry: Behavioral Sciences, Clinical Psychiatry*. 7th ed. Baltimore: Williams and Wilkins; 1994. p. 608-11.