

Penetrating Injury of Superior Sagittal Sinus

Abstract

Penetrating injury of superior sagittal sinus (SSS) is very rare yet serious which can lead to morbidity and mortality. Complications such as bleeding, thrombosis, and infection are possible and should be anticipated. We report a case of 3-year-old boy with penetrating injury caused by a nail at the middle third of SSS. The patient underwent the surgery for extraction and sinus repair and antibiotic treatment during the hospital stay. He was neurologically intact and recovered completely. Comprehensive treatment of both surgical and medical management is important in achieving the best possible outcome.

Keywords: Head injury, penetrating head injury, penetrating sinus injury, penetrating superior sagittal sinus injury, superior sagittal sinus injury

Introduction

Sinus injury is a very dangerous condition which occurs in 1.5%–5.5% of all head trauma cases.^[1] This type of injury constitutes 4%–12% of all head trauma cases. Despite making a small proportion, the mortality rate of dural sinus injury reaches 41%.^[2] Location of the injury affects the surgical approach and the consideration to salvage or to preserve the related structure. Among all sinuses, the superior sagittal sinus (SSS) is the most common injured site.^[1,2]

SSS injury that was caused by nail penetration is very rare.^[3,4] Complications of this condition include bleeding and thrombosis. Both can lead to new neurologic deficits such as paresis or seizure and eventually increased intracranial pressure when the extent of the bleeding or infarct is large enough. The surgical procedure is necessary to extract the nail. Thus, imaging is very helpful for perioperative planning.

The surgical procedure to extract the nail also acts as infection source control to prevent further morbidities such as meningitis or encephalitis which can be devastating. Therefore, comprehensive treatments and follow-ups are mandatory for the best possible outcome.

This is an open access journal, and articles are distributed under the terms of the Creative Commons Attribution-NonCommercial-ShareAlike 4.0 License, which allows others to remix, tweak, and build upon the work non-commercially, as long as appropriate credit is given and the new creations are licensed under the identical terms.

For reprints contact: WKHLRPMedknow_reprints@wolterskluwer.com

Case Report

Authors reported a case of 3-year-old boy, attending to the emergency department at National Brain Center, whose head was accidentally punctured with a corroded nail using a rivet gun at the midline parietal 6 h before [Figure 1]. Complaint of pain was localized at the site of the injury. Bleeding was minimum and the patient had no neurologic deficits at all. History of vaccination and immunization was complete until he was 9-month-old, including for tetanus.

The patient underwent the brain computed tomography (CT) scan and CT angiography to achieve a better understanding of the exact site and position of the nail intracranially. The nail did not injure the brain parenchyma at all; however, it completely penetrated the middle portion of SSS [Figure 2]. There was no arteries appeared to be damaged [Figure 3]. The brain was looking edematous but from the clinical examination, the patient did not show any signs of increased intracranial pressure.

The patient received tetanus immunoglobulin 250 IU and underwent surgery to remove the nail and repair the dura. Cefazoline 400 mg intravenous was given as prophylaxis treatment for this patient.

How to cite this article: Arham A, Zaragita N. Penetrating injury of superior sagittal sinus. *Asian J Neurosurg* 2021;16:132-5.

Submitted: 29-Jun-2020 **Revised:** 04-Aug-2020
Accepted: 01-Oct-2020 **Published:** 20-Mar-2021

**Abbrar Arham,
Nadya Zaragita**

*Departments of Neurosurgery,
National Brain Center, South
Jakarta, Indonesia*

Address for correspondence:

*Dr. Abbrar Arham,
Department of Neurosurgery,
National Brain Center, MT
Haryono Kav. 11,
South Jakarta 13650, Indonesia.
E-mail: drabbrar_arham@yahoo.
com*

Access this article online

Website: www.asianjns.org

DOI: 10.4103/ajns.AJNS_320_20

Quick Response Code:



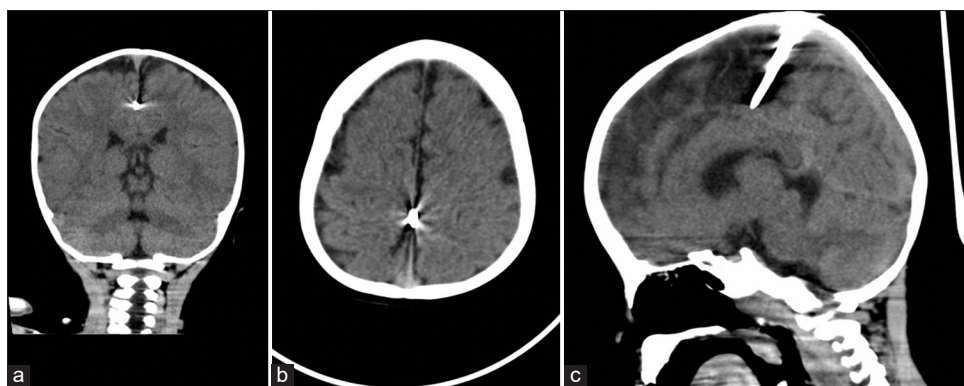


Figure 1: (a) Coronal, (b) Axial, and (c) Sagittal view of the brain computed tomography scan

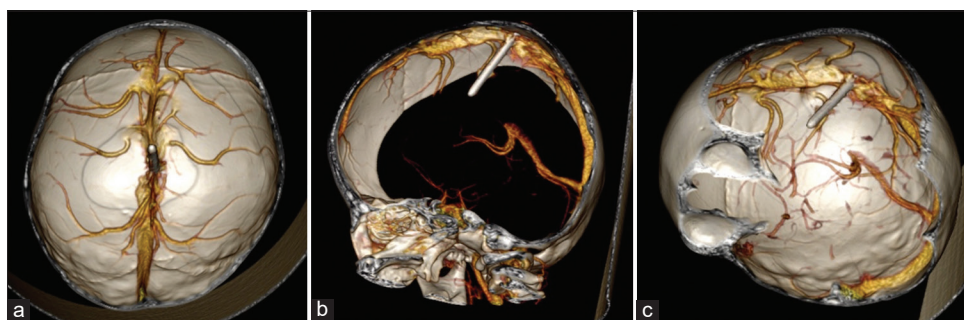


Figure 2: (a) Axial view, (b) Sagittal view, and (c) Oblique view of computed tomography scan three-dimensional reconstruction

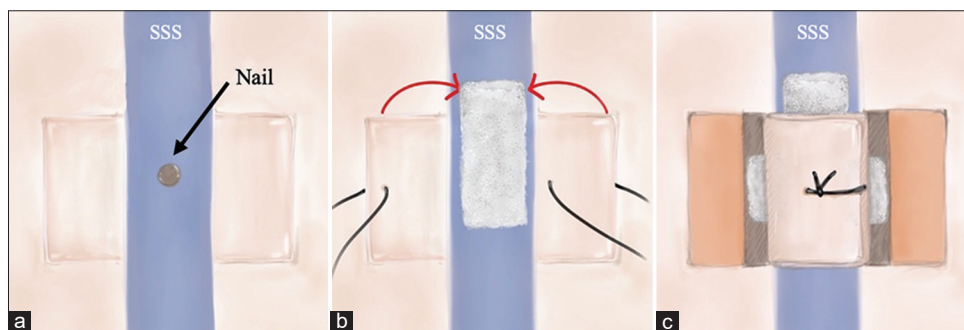


Figure 3: Steps of dura repair. (a) Dura incision design (superior sagittal sinus). (b) The suture was placed to the dura flaps. The nail was extracted and the hemostatic agent was placed over the defect and also at the lateral walls of the sinus (not illustrated). Immediately, the dura flaps were approximated. (c) The final result of the sinus repair

Management

The patient was positioned supine, with the neck slightly flexed. The aseptic and antiseptic procedure was done at the parietal region. U-shaped incision was made at the midparietal region and the skin was retracted downwardly. The nail was identified on the surface of the bone, right on the sagittal suture. Craniotomy with a size of 4 cm × 4 cm was made at the midparietal. The bone was elevated, leaving the nail head attached at the middle portion of SSS. From the injured sinus, there was no apparent bleeding.

Two U-shaped incisions lateral to the nail, which will be the flaps to repair the torn sinus, were made. The temporary clip was used to secure one of the draining veins. The nail was quickly removed and gentle pressure with the finger was applied to control the bleeding. The lateral sinus wall

was packed with hemostatic agents until the bleeding stopped while the surface of the sinus was closed with a hemostatic agent and the dura flaps that were approximated and sutured at the midline [Figures 4]. There was no active bleeding after the sinus repair. The temporary clip was removed. Synthetic dura was used to cover the exposed brain, the bone was put back, and the skin was sutured. Total blood loss was 100cc.

The postoperative laboratory showed that hemoglobin level dropped from 12.5 g/dL to 7.7 g/dL. Packed red cell transfusion was given to the patient. He also received postoperative antibiotics of ceftriaxone and metronidazole. During the hospital stay, the patient showed no neurologic deficits neither signs of infection. The patient was discharged after 1 week of treatments.

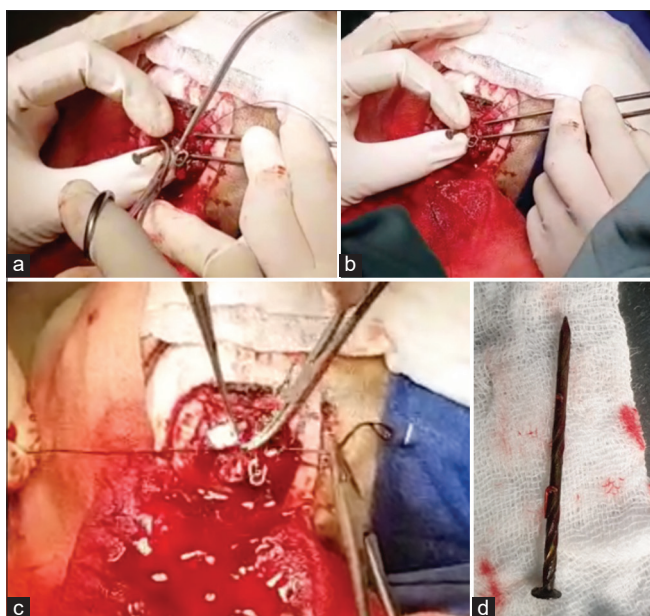


Figure 4: Intraoperative findings. (a and b) The nail was being extracted. (c) Dural repair with hemostat and flaps, with bleeding volume of 100 cc (d) 4.5 cm nail

During 1-week, 1-month, 3-months, and 6-months clinic follow-up, the patient had no complaints at all as well. The brain CT-scan, CT angiography, or magnetic resonance venography (MRV) after the surgical procedure was not performed to the patient due to the patients' stable clinical condition.

Discussion

Sinus injury composed a small portion of all head injury cases which can be very fatal in some cases when not treated.^[1] Intracranial nail injury constitutes a small portion of all head injury cases and some of them involved the sinus.^[5] When the injury does not injure the parenchyma or important blood vessels, the neurologic status outcome is usually good.^[3] In our case, since the nail was right at the midline, projecting anteriorly, the brain was not damaged, explaining the good neurologic status.

Conditions resulted from sinus injury include bleeding that can manifest as epidural hemorrhage or subdural hemorrhage. Other condition that has to be taken care of is the probability of thrombosis at the injured site. The obstructed venous outflow of a large draining vein may eventually cause severe brain edema which can be fatal.

The decision to treat SSS injury due to trauma depends on the site of the injury itself. Out of all dural sinus injury, the most common is SSS, with the most common involving the middle portion (48%), followed by the anterior (41%) and the posterior (10%).^[2] Injury at the anterior portion of SSS can be treated by ligation, but this treatment cannot be done to the middle and posterior portion of SSS in which repair is necessary.^[1] Death rate was highest when the injury site involving the posterior portion, followed by the

middle, and finally anterior portion.^[2] In our case, the sinus was repaired due to this reason.

Imaging studies for surgical planning is very crucial for trauma cases. Beside in determining the approach and the size of craniotomy, it gives the operator information of the extent of the injury and the possible route of extraction.^[6] Blind extraction may be fatal when there is unknown vessel injury which may lead to unexpected profuse bleeding. However, it is also important to remember that not all vessels can be visualized clearly from imaging, especially if the diameter of the blood vessel is very small. Ideally, imaging such as MRV after the surgical procedure should be done to assess if there is thrombosis and will determine the need of anticoagulant treatment. In some case series, venous thrombosis occurred and patients received short-term anticoagulant treatment for better outcomes.^[1] However, clinicians should decide if anticoagulant treatment would be safe enough to be given to the patient considering the risk of bleeding. In our report, the patient was a child who was clinically stable and therefore was not given any antiplatelets nor anticoagulants.

During the surgery, the dural sinus can be repaired with direct pressure and various kinds of hemostatic agents.^[5] Depending on the needs, free duraplasty with or without muscle flap can also be done, but in one case, the complication of total venous occlusion occurred after this procedure.^[1,2] In our case, since the dural sinus defect was small, small flaps from the lateral side of the sinus was considered sufficient for dura repair and stop the bleeding. The patient's positioning during the surgery is also crucial since one of the risks during the surgery is air embolism.

The risk of infection has to be kept in mind especially when trauma occurs in the pediatric population since this population can be prone. Complications such as meningitis and encephalitis are possible, which may lead to a prolonged hospital stay or even disability. For this reason, the administration of antibiotics is generally recommended.^[3] In a case, residual hemiparesis remained, related to the site of injury.^[7]

The studies mentioned above are summarized in Table 1.

Conclusion

SSS injury is a rare case that can lead to morbidity and mortality if not treated properly. Although surgical repair is necessary and done, clinicians should be aware of the potential problems such as emboli, thrombosis, and infection during the recovery period. Clinically stable patient during the hospital admission does not guarantee that all of the complications mentioned will not occur. Comprehensive treatments and thorough examination during the follow-ups are important to ensure patients' safety.

Informed consent

Informed consent from patient's guardian was collected.

Table 1: Reviews of Previous Articles on Sinus Injury

Authors	Type of injury	Management	Deficit or complication
Meier <i>et al.</i> ^[2]	39 cases of superficial dural sinus injury out of 978 cases within a period of 13 years	Ten cases were treated with free duraplasty, six with direct stitching, six with hitching up the dura to the bone adjacent to the sinus, 4 with ligation of the SSS, three by lateral sinus angle occlusion, two with pedunculated duraplasty, and eight with staunching the bleeding	16 deaths among 39 superficial dural sinus injury
Elkakatny <i>et al.</i> ^[1]	Twenty cases of dural venous sinus injury within a period of August 2013–March 2014	Ten cases were treated with direct compression of gel foam, five cases were controlled by gel foam and dural repair, and one case was treated by free muscle duroplasty	One case of multiple brain infarction, two cases of EDH at contralateral site, five cases of intraoperative bleeding that required a blood transfusion, and one case of sinus thrombosis
Makoshi <i>et al.</i> ^[7]	One case of right transverse sinus nail gun injury	The patient underwent angiography before surgical removal of the foreign object and sinus repair	Residual right hemiparesis

EDH – Epidural hemorrhage; SSS – Superior sagittal sinus

Declaration of patient consent

The authors certify that they have obtained all appropriate patient consent forms. In the form, the guardian has given his consent for images and other clinical information to be reported in the journal. The guardian understands that names and initials will not be published and due efforts will be made to conceal identity, but anonymity cannot be guaranteed.

Financial support and sponsorship

Nil.

Conflicts of interest

There are no conflicts of interest.

References

1. Elkakatny AA, Elreheem YA, Hamdy T. Traumatic dural venous sinuses injury. *Open Access Maced J Med Sci* 2019;7:3225-34.
2. Meier U, Gärtner F, Knopf W, Klötzer R, Wolf O. The traumatic dural sinus injury-A clinical study. *Acta Neurochir (Wien)* 1992;119:91-3.
3. Sani S, Jobe KW, Byrne RW. Successful repair of an intracranial nail-gun injury involving the parietal region and the superior sagittal sinus. *Case report. J Neurosurg* 2005;103:567-9.
4. Guppy KH, Ochi C. Self-inflicted drywall screws in the sagittal sinus. *World Neurosurg* 2018;110:323-5.
5. Nussbaum ES, Graupman P, Patel PD. Repair of the superior sagittal sinus following penetrating intracranial injury caused by nail gun accident: Case report and technical note. *Br J Neurosurg* 2019;1-5. DOI: 10.1080/02688697.2019.1630550.
6. Jeon YH, Kim DM, Kim SH, Kim SW. Serious penetrating craniocerebral injury caused by a nail gun. *J of Korean Neurosurgical Society* 2014;56:537-9.
7. Makoshi Z, AlKherayf F, da Silva V, Lesiuk H. Nail gun injuries to the head with minimal neurological consequences: A case series. *J Med Case Rep* 2016;10:58.