

Unusual Complication of Paraplegia Following Intracranial Aneurysm Clipping in a Patient with Undiagnosed Coarctation of Aorta

Abstract

We report a case of subarachnoid hemorrhage in a 38-year-old male, diagnosed to have the right middle cerebral artery aneurysm on computed tomography (CT) cerebral angiogram. He was a known hypertensive for 17 years and was on irregular treatment. Craniotomy and clipping of the aneurysm were done. Postoperatively, the patient had high blood pressure of 200/120 mmHg. Treatment of hypertension in the postoperative period resulted in paraplegia. CT angiogram of aorta revealed coarctation-postductal type. He underwent balloon dilatation for the coarctation of aorta followed by coarctoplasty and stenting with the improvement in motor power in both lower limbs.

Keywords: *Coarctation of aorta, paraplegia, postoperative paraplegia*

**Shaik Afsar Pasha,
Rajesh K. Ghanta¹,
Biju Govind²**

Departments of Neurology and ²Cardiology, NRI Medical College and General Hospital, Guntur; ¹Department of Neurosurgery, Suraksha Hospital, Vijayawada, Andhra Pradesh, India

Introduction

Coarctation of the aorta is a congenital cardiac malformation that can go undiagnosed until old age with only hypertension as a marker of its presence because clinical signs can be subtle. The frequency of intracranial aneurysm among patients with coarctation of aorta is approximately 5-fold to that of the general population.^[1] The younger age group present more with aneurysmal rupture due to coarctation while compared to patients without coarctation.^[2] The incidence of coarctation of the aorta among patients with cerebral aneurysm is very low, ranging from 0.19% to 1.9%.^[2] Treatment of hypertension in the perioperative treatment of intracranial aneurysm can lead to renal or spinal cord ischemia in a patient with undiagnosed coarctation of aorta.

Case Report

A 38-year-old male presented with complaints of sudden onset severe headache and mild weakness in the left leg with loss of vision in the left eye for 1 day. He was a known hypertensive for 17 years and was on irregular treatment. The patient was conscious, alert, with power of 4+/5 in the left upper limb and 2/5 power in the left lower limb. Blood pressure was 170/100 mmHg in the right upper limb. Computed tomography (CT) of the brain

revealed subarachnoid hemorrhage (SAH) with bleeding predominantly in the right sylvian fissure [Figure 1]. CT cerebral angiogram revealed a large right middle cerebral artery (MCA) bifurcation aneurysm and a small unruptured posterior communicating artery aneurysm [Figure 2]. Four-vessel digital subtraction angiogram (DSA) was not done in this case.

Right pterional craniotomy and clipping of MCA bifurcation aneurysm were done. Postoperatively, patient's blood pressure increased to 200/120 mmHg. In view of increasing blood pressures, anti-hypertensive medications were started including clonidine. Gradually, the blood pressure decreased to 140/90 mmHg. Simultaneously, there was a decrease in the motor power in both lower limbs with reduced sensation. On examination, power was 0/5 in both lower limbs with bladder/bowel involvement and decreased sensation below D-10 dermatome with sparing of posterior columns. Magnetic resonance imaging of the whole spine was normal. Both the femoral pulses were feeble. CT angiogram of the aorta revealed postductal type coarctation of aorta [Figure 3]. Postoperative CT scan of the brain did not show any infarct. Loss of vision in the left eye was due to subhyaloid hemorrhage.

The patient was discharged on the 10th postoperative day. He underwent

Address for correspondence:

*Dr. Shaik Afsar Pasha,
Department of Neurology,
NRI Medical College and
General Hospital, Chinakakani,
Guntur, Andhra Pradesh, India.
E-mail: afsarpasha81@gmail.
com*

Access this article online

Website: www.asianjns.org

DOI: 10.4103/ajns.AJNS_327_16

Quick Response Code:



How to cite this article: Pasha SA, Ghanta RK, Govind B. Unusual complication of paraplegia following intracranial aneurysm clipping in a patient with undiagnosed coarctation of aorta. *Asian J Neurosurg* 2019;14:989-91.

This is an open access journal, and articles are distributed under the terms of the Creative Commons Attribution-NonCommercial-ShareAlike 4.0 License, which allows others to remix, tweak, and build upon the work non-commercially, as long as appropriate credit is given and the new creations are licensed under the identical terms.

For reprints contact: reprints@medknow.com

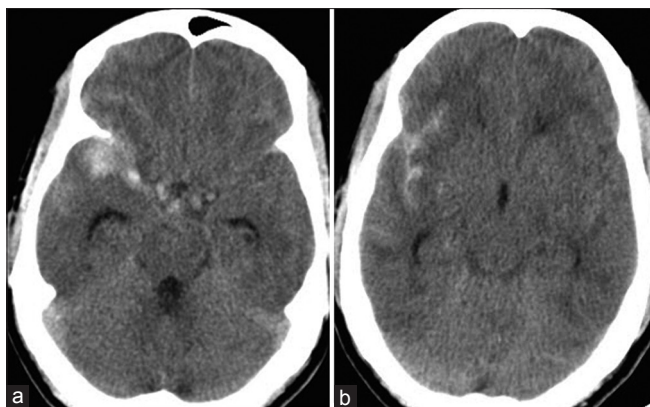


Figure 1: (a and b) Noncontrast computed tomography scan of the brain showing subarachnoid hemorrhage, with blood predominantly in right sylvian fissure

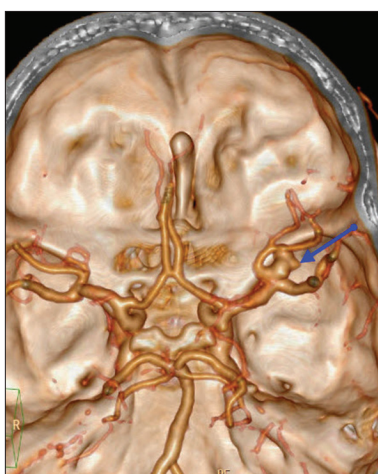


Figure 2: Three-dimensional computed tomography brain angio and volume rendering image showing large right middle cerebral artery bifurcation aneurysm and small right posterior communicating artery aneurysm

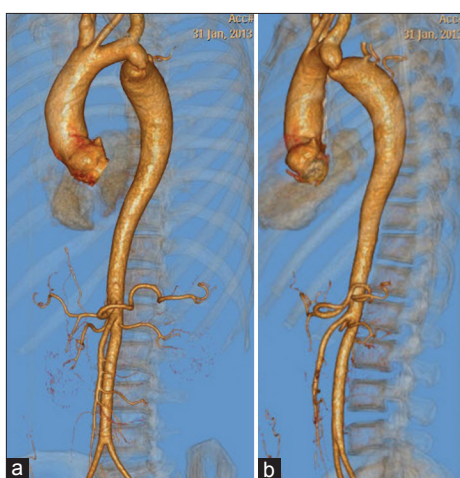

Figure 3: (a and b) Three-dimensional computed tomography angio of aorta showing postductal coarctation of aorta

balloon angioplasty for coarctation of aorta 3 months after clipping of the intracranial aneurysm and later underwent coarctoplasty with stenting for the treatment

of recoarctation. Clinical examination at 2-year follow-up showed neurological improvement, with power 4/5 in both lower limbs, counting fingers at 3 m distance in the left eye, and patient being partially dependent for daily activities.

Discussion

The association of aortic coarctation and cerebral aneurysms was first described by Eppinger in 1871.^[3] Patients presenting with ruptured intracranial aneurysm in association with coarctation of aorta are usually younger and can have multiple intracranial aneurysms.^[2] Mild or moderate coarctation may exist undetected in adult life, where it usually presents due to its sequelae.^[4] In the present case, the patient only had hypertension before presenting with SAH. CT angiogram of the brain was done initially in this case for diagnosing intracranial aneurysm. The standard 4-vessel DSA by transfemoral approach would have diagnosed coarctation of aorta before the cranial surgery.

Coarctation of aorta is a relatively common cardiovascular anomaly accounting for 5%–8% of congenital cardiac defects.^[4] In neonates and infants, it presents as congestive cardiac failure and in older children and adults as hypertension. High index of suspicion is required in a young patient with hypertension to rule out secondary causes. In the present case, though the patient had been hypertensive for 17 years, he was on irregular treatment and the investigations to rule out secondary causes of hypertension were not done due to logistic reasons. After admission for treating SAH, DSA could have diagnosed the coarctation before the intracranial surgery. In this case, CT angiogram of the brain was done. This is one scenario where DSA would have given more information than CT angiogram. Treatment of patients with intracranial ruptured aneurysm accompanied by coarctation should begin with the clipping/coiling of the aneurysm, followed by the surgical treatment for coarctation.^[2]

Paraparesis in patients with coarctation of aorta has been described in literature; possible causes include compression due to dilated intraspinal collaterals, SAH, and its sequelae; compression due to radicular artery aneurysm or spinal artery aneurysm; or compression due to enlarged and tortuous anterior spinal artery collateral.^[5] “Aortic steal” could be a cause of paraparesis, where there is reversal of flow and the blood passes from the anterior spinal artery to the part of aorta distal to the coarctation.^[5] Paraparesis following surgery for coarctation of aorta has also been described following cross clamping of the descending thoracic aorta due to insufficient blood supply along the spinal arteries.^[6] Paraplegia following percutaneous balloon angioplasty for aortic coarctation is also reported in literature.^[7] Paraparesis following intracranial aneurysm clipping surgery in an undiagnosed coarctation of aorta is rare. In the present case, the probable cause for paraplegia was excessive reduction of blood pressure in the distal aorta, leading to spinal cord

ischemia. After balloon dilatation and coarctoplasty with stenting, the patient gradually improved neurologically because of the normalization of blood flow patterns. Neurosurgeons treating intracranial aneurysms in younger, hypertensive patients should have a higher suspicion of coarctation of aorta and when hypertension is being treated, care should be taken to prevent renal or spinal cord ischemia. The urinary output, blood pressure, and motor function of the lower extremities must be checked regularly.^[2]

Conclusion

Coarctation of aorta is a clinical diagnosis. High index of suspicion is required in young, noncyanosed, hypertensive patients with neurological presentations such as aneurysmal SAH, intraocular subhyaloid hemorrhage, and vascular myelopathy. Early intervention is required to reduce the mortality and morbidity and to improve the quality of life in these patients.

Financial support and sponsorship

Nil.

Conflicts of interest

There are no conflicts of interest.

References

1. Connolly HM, Huston J 3rd, Brown RD Jr., Warnes CA, Ammash NM, Tajik AJ. Intracranial aneurysms in patients with coarctation of the aorta: A prospective magnetic resonance angiographic study of 100 patients. *Mayo Clin Proc* 2003;78:1491-9.
2. Serizawa T, Satoh A, Miyata A, Kobayashi S, Odaki M, Nakamura H, *et al.* Ruptured cerebral aneurysm associated with coarctation of the aorta – Report of two cases. *Neurol Med Chir (Tokyo)* 1992;32:342-5.
3. Victor AR, Rossi R, Anjos R, Branco C, Ferreira R, Martins FM. Intracranial aneurysms as the first sign of coarctation of the aorta. *Rev Port Cardiol* 2005;24:571-7.
4. Jurcut R, Daraban AM, Lorber A, Deleanu D, Amzulescu MS, Zara C, *et al.* Coarctation of the aorta in adults: What is the best treatment? Case report and literature review. *J Med Life* 2011;4:189-95.
5. Gill M, Pathak HC, Singh P, Pathak K. A case of aortic coarctation presenting with quadriparesis due to dilated tortuous anterior spinal artery. *Neurol India* 2011;59:317-8.
6. Abad C, Martí M, Marrero L, Antúnez ML, Suárez P. Paraplegia following surgical repair of a ductus and of a coarctation of the aorta in childhood. *Cir Pediatr* 1993;6:84-7.
7. Ussia GP, Marasini M, Pongiglione G. Paraplegia following percutaneous balloon angioplasty of aortic coarctation: A case report. *Catheter Cardiovasc Interv* 2001;54:510-3.