

Trans-Cranial Embolisation of a Complex Transverse Sigmoid Sinus Dural Arteriovenous Fistula by Direct Puncture of the Superior Sagittal Sinus

Abstract

This technical note describes a direct puncture of the superior sagittal sinus (SSS) to treat a complex dural arteriovenous fistula (dAVF). A 40-year-old female was admitted having a history of increasing confusion. Computer tomography revealed enlargement of the right superior ophthalmic vein and magnetic resonance imaging demonstrated extensive bilateral hemispheric venous engorgement. Digital subtraction angiography (DSA) demonstrated a high flow dAVF involving the right transverse sinus. There was extensive cortical venous rerouting with venous sinus occlusion at the right transverse and sigmoid junction. Under general anesthesia, the sinus was exposed and catheterized. The angiography catheter was fed over the guide wire into the sinus. The remaining right sigmoid and transverse sinus were obliterated using a combination of microcoils and Onyx®. She made a good postoperative recovery, and a repeat DSA at 30 days postoperatively showed evidence of the meningohypophyseal trunk but complete occlusion of the fistula. A check DSA 2 years later confirmed no evidence of a residual fistula. Our case demonstrates the potential use of the SSS as a novel conduit to treat distant targets.

Keywords: Cannulation, embolization, fistula, Onyx®

Introduction

The superior sagittal sinus (SSS) has novel potential to be used as a conduit to treat pathology relatively far removed from the puncture site. We had employed standard procedural methods to treat a complex dural arteriovenous fistula (dAVF) but decided to take a more radical approach which proved successful in terms of technique and functional recovery. This transcranial approach has already been employed before for direct cannulation of lesion vessels, and our case demonstrates the potential use of the SSS as a unique conduit to treat distant targets.

Technical Note

A 40-year-old female was admitted having a history of increasing confusion but no seizure history. Five years earlier, she had been investigated for headache and right-sided tinnitus, but magnetic resonance imaging (MRI) was normal. She was subsequently seen by an ophthalmologist for diplopia. Computer tomography revealed enlargement of the right superior ophthalmic vein, and a repeat MRI demonstrated

extensive bilateral hemispheric venous engorgement [Figure 1a].

Her previous medical history included alcohol excess and treatment for breast carcinoma. Each day, she smoked twenty cigarettes and consumed two bottles of spirits. On examination, positive findings included confusion, right-sided proptosis, and left upper limb drift.

Digital subtraction angiography (DSA) demonstrated a high flow dAVF involving the right transverse sinus [Figure 1b and c]. Its supply was from the right occipital artery and the neuromeningeal division of the right ascending pharyngeal artery. Supply to the fistula arose from the right posterior inferior cerebellar artery as well as from the tentorial divisions of the meningohypophyseal trunks bilaterally. Further supply from the right anterior inferior cerebellar artery and posterior meningeal artery was also observed, and a pial venous sump effect was noted.

There was extensive cortical venous rerouting with venous sinus occlusion at the right transverse and sigmoid junction. In view of the cortical venous reflux, this

**Simon Lammy,
Joti Bhattacharya¹,
James Dervin¹,
Edward Jerome
St. George**

Departments of Neurosurgery and ¹Neuroradiology, Institute of Neurological Sciences, The Southern General Hospital, Glasgow G51 4TF, United Kingdom

Address for correspondence:

*Dr. Simon Lammy,
Department of Neurosurgery,
Institute of Neurological
Sciences, The Southern
General Hospital, 1345
Govan Road, Glasgow
G51 4TF, United Kingdom.
E-mail: lammy@doctors.org.uk*

Access this article online

Website: www.asianjns.org

DOI: 10.4103/ajns.AJNS_330_16

Quick Response Code:



How to cite this article: Lammy S, Bhattacharya J, Dervin J, Jerome E, St. George EJ. Trans-Cranial embolisation of a complex transverse sigmoid sinus dural arteriovenous fistula by direct puncture of the superior sagittal sinus. *Asian J Neurosurg* 2018;13:946-8.

This is an open access journal, and articles are distributed under the terms of the Creative Commons Attribution-NonCommercial-ShareAlike 4.0 License, which allows others to remix, tweak, and build upon the work non-commercially, as long as appropriate credit is given and the new creations are licensed under the identical terms.

For reprints contact: reprints@medknow.com

lesion posed a high risk of hemorrhage at 11% (Borden Type II dAVF).

An initial attempt at embolizing one of the multiple direct communicating transverse sinus fistulae arising from the middle meningeal artery (MMA) with 70% cyanoacrylate led to some reduction in flow (in conjunction to occlusion of the fistula bed using Onyx[®] through the right occipital artery). A further staged embolization was carried out 5 days later. This occluded a further two direct fistulae using 80% cyanoacrylate and a pedicle arising from the MMA was infused using Onyx[®]: this resulted in complete occlusion of supply from the MMA.

However, an ascent balloon could not be navigated across the torcula into the right transverse sinus through the left sigmoid sinus: due to its septated configuration. Two weeks later, the transvenous route was used in an attempt to access the right transverse sinus through organized clot in the jugular vein: this too was unsuccessful. It was agreed that the most direct route to the transverse sinus was through the direct cannulation of the SSS. This occurred 1 month later.

Under general anesthesia in the neurosurgical theaters, the patient was placed in the supine position, and the head immobilized in a 3-pin Mayfield[®] head clamp. The surface projection of the SSS was marked using Brain Lab[®] neuronavigation and was observed just right of the midline. The site of entry was chosen distal to the point of sinus constriction. A free bone flap was cut using an air drill and the sinus was exposed. The sinus was catheterized through the scalp using a large Venflon[®]. Using the Seldinger technique, a guide wire was passed through the Venflon into the sinus (and the Venflon was then removed).

The angiography catheter was fed over the guide wire into the sinus and connected to a saline flush [Figure 2]. The

bone flap was replaced and secured with plates, and the scalp closed in a single layer, and the patient transferred to the radiology suite. It became necessary to reopen the wound in the angiography suite to facilitate deeper passage of the catheter. The remaining right sigmoid and transverse sinus were obliterated using a combination of microcoils and Onyx[®]. The wound was then packed with Betadine[®] soaked gauze and covered with an Opsite[®] dressing.

The patient then returned to our neurosurgical theaters where the wound was reopened, and the catheter removed under direct vision. Minimal sinus bleeding was observed. Floseal[®] was applied, and the bone flap was replaced and secured with plates. The scalp was closed in layers, and the patient was then transferred to our neurosurgical Intensive Care Unit. She made a good postoperative recovery and a repeat DSA at 30 days postoperatively showed evidence of the meningohypophyseal trunk but no longer contributing to the fistula: complete occlusion of the fistula. This was also demonstrated on a repeat MRI [Figure 3a]. A check DSA 2 years later confirmed no evidence of a residual arteriovenous fistula [Figure 3b and 3c].

Discussion

Using the SSS as a conduit to treat complex dAVF of intracranial venous systems, downstream is novel and extremely uncommon in Britain, i.e., reports are scarce. Direct puncture of other intracranial vessels has been conducted to treat a lesion but only in the vessel directly cannulized, for example, MMA,^[1] transverse-sigmoid sinus,^[2] and SSS.^[3]

A multitude of treatment and procedural methods exists for treating complex dAVF and these historically encompassed a spectrum from embolization and coil occlusion through transvenous and transarterial routes, radiosurgery, and surgery. Therefore, it remains a treatment modality which is employed if more conventional means are unsuccessful.

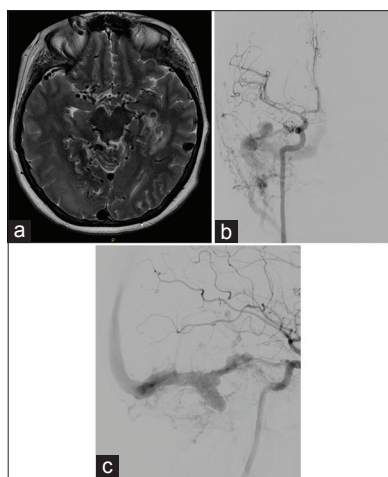


Figure 1: (a) Magnetic resonance imaging (T2-weighted). Three-month preembolization showing venous congestion and occlusion. (b) Angiogram. Preembolization image demonstrating early venous filling and a high flow dural arteriovenous fistula involving the transverse sinus. (c) Angiogram (lateral). Preembolization image demonstrating early venous filling and a high flow dural arteriovenous fistula involving the transverse sinus

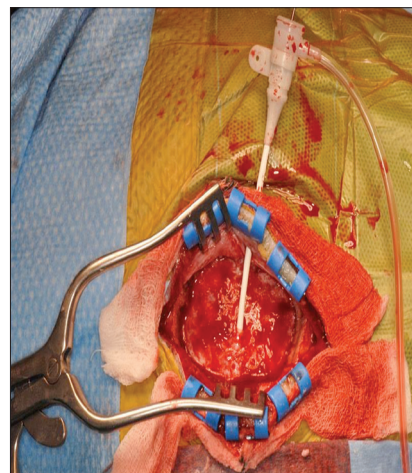


Figure 2: Intraoperative image showing placement of angiography catheter in the superior sagittal sinus after the Seldinger technique was used

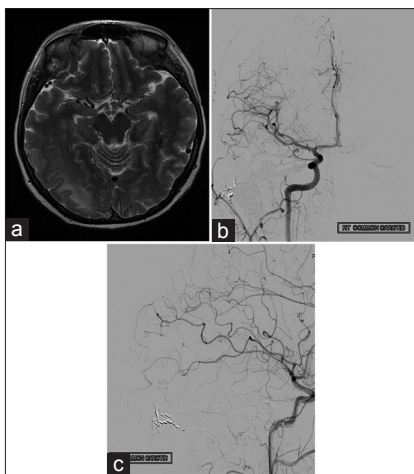


Figure 3: (a) Magnetic resonance imaging (T2-weighted). Three-month postembolization showing a significant reduction in venous congestion. (b) Angiogram. Two-year postembolization image demonstrating no evidence of residual dural arteriovenous fistula. (c) Angiogram (lateral). Two-year postembolization image demonstrating no evidence of residual dural arteriovenous fistula

The surgical corridor is small and can present a technical challenge to cannulate the SSS. Due to the variable anatomy of the SSS, neuronavigation should be employed to permit ease of puncture.

Preoperative assessment should include both MRI and DSA. Use of a neurosurgical theater and angiography suite in proximity to each other permits ease of transfer. Staff trained in both operative and endovascular environments should be employed. This decreases the risk of dislodging the angiography catheter during patient transfer to and from the angiography suite. Postoperative investigations include

a DSA and MRI to check for evidence of fistula occlusion and obliteration.

Conclusion

This technical note in conjunction to other direct puncture reports of the SSS demonstrates the utility of the SSS as a means to treat pathology far removed (relatively speaking) from the puncture site. We employed standard procedural methods to treat our patient but decided to undertake a more radical approach that proved successful in terms of both technique and functional recovery. This transcranial approach has already been employed before for direct cannulation of lesion vessels, and our case demonstrates the potential use of the SSS as a novel conduit to treat distant targets.

Financial support and sponsorship

Nil.

Conflicts of interest

There are no conflicts of interest.

References

1. Oh JS, Yoon SM, Shim JJ, Bae HG. Transcranial direct middle meningeal artery puncture for the onyx embolization of dural arteriovenous fistula involving the superior sagittal sinus. *J Korean Neurosurg Soc* 2015;57:54-7.
2. Pierot L, Visot A, Boulin A, Dupuy M. Combined neurosurgical and neuroradiological treatment of a complex superior sagittal sinus dural fistula: Technical note. *Neurosurgery* 1998;42:194-7.
3. Luo CB, Chang FC, Wu HM, Chung WY. Transcranial embolization of a transverse-sigmoid sinus dural arteriovenous fistula carried out through a decompressive craniectomy. *Acta Neurochir (Wien)* 2007;149:197-200.